

Less Invasive Surgical Procedures Using Narrow-Diameter Implants: A Prospective Study in 20 Consecutive Patients

France Emmanuelle Lambert, DDS, MS, PhD^{1*}

Geoffrey Lecloux, DDS, MS¹

Charlotte Grenade, DDS MS²

Alice Bouhy, DDS, MS³

Marc Lamy, DDS, MS, PhD⁴

Eric Henri Rompen, DDS, MS, PhD¹

Narrow-diameter implants (NDIs) are increasingly produced and used in implant dentistry, especially since the introduction of new, more resistant materials. The objective of the present study was to evaluate the clinical performance of NDIs (3.3 mm) placed in thin alveolar crests. Twenty consecutive patients needing implant-supported fixed partial dentures and presenting an alveolar thickness ≤ 6 mm were treated with 1 or several NDIs. The surgical protocol was chosen according to the clinical situation: (1) flapless, (2) mini-cervical flap, (3) wide flap, (4) wide flap + guided bone regeneration (GBR). Implants were immediately loaded if the primary stability was higher than 20 Ncm. Implant survival and success, prosthodontic success rates, and patient-centered outcomes were evaluated after a follow-up period of 1 year. A total of 39 implants were placed in 20 patients, 12 and 27 implants in the anterior regions and in the posterior mandible, respectively. All but 1 implant reached an insertion torque higher than 20 Ncm and were loaded within 48 hours. The implant survival and success rates both reached 94.7%. The need for GBR was avoided in 60% of the implant sites. The mean peri-implant bone remodeling after a follow-up period of 1 year was -0.35 mm at the implant level. Peri-implant bone remodeling was higher in the posterior region, when the alveolar crest was thinner than 4 mm and GBR was required in addition. In conclusion, use of NDIs to restore partial edentation in sites with limited horizontal thickness seems to be an effective treatment option that prevented GBR in the majority of the present cases. Immediate provisionalization of NDIs does not seem to impair the results.

Key Words: dental implant, dental prosthesis, implant-supported, immediate dental implant loading, minimally invasive surgical procedure.

INTRODUCTION

Dental implants are now frequently considered in oral rehabilitation. However, some clinical situations with limited bone availability in height or thickness may impair the placement of standard implants without concomitant bone regeneration. This makes the treatment more complex and traumatic for the patients. Patients—mainly out of fear of surgery or the expected postoperative outcomes—may be less tolerant of these treatment options.¹ Nevertheless, over the last decade, dental implant designs—such as shorter and narrower implants—have been developed to better suit the clinical situation and reduce the need for bone reconstruction and, consequently, patient discomfort. The development of new and stronger materials for implant manufacturing has allowed the use of narrow-implant diameters (NDIs) (≤ 3.5 mm) and, at the same

time, widened the indications. The clinical outcomes of NDIs have been systematically reviewed by Sohrabi et al² and seem to display results similar to those reported for standard implants.^{3–5} The mean survival rate reported overall screened studies was higher than 90%, including 8 studies with a 100% survival rate. In 22 studies, the reported survival rate ranged from 95% to 99.9%.² Despite the high survival rates found in these studies, few treatment protocols and indications have been investigated with NDIs compared to regular-diameter implants. For instance, only a few studies have evaluated the effectiveness of NDIs for the replacement of posterior teeth (molars/premolars)^{6–9} and even fewer have assessed immediate provisionalization of NDIs.^{10,11} Since NDIs seem to decrease the need for bone regeneration and large flap reflection,² the potential reduction of the incidence of surgical trauma is not well understood. The primary objective of the present study was to determine the implant success rate and marginal bone resorption 1 year after NDI placement and immediate restoration in the alveolar bone crest ≤ 6 mm in thickness. The secondary objective was to assess the proportion of implant sites that could be managed less invasively using only reduced NDIs without any bone regeneration procedures.

¹ Department of Periodontology and Oral Surgery, University of Liège, Belgium.

² Department of Fixed Prosthodontics, University of Liège, Belgium.

³ Department of Removable Prosthodontics, University of Liège, Belgium.

⁴ Department of Implant Prosthodontics, University of Liège, Belgium.

* Corresponding author, e-mail: france.lambert@chu.ulg.ac.be

DOI: 10.1563/AAID-JOI-D-13-00201

MATERIALS & METHODS**Study design**

The present study was designed to enroll a series of consecutive patients in need of an implant-supported fixed partial denture and presenting an alveolar crest ≤ 6 mm thick. Twenty consecutive patients from the Department of Periodontology and Oral Surgery at the University of Liège, Belgium, were enrolled between March 2010 and July 2011. The ethics committee of the University Hospital, University of Liège, Belgium, approved the study protocol (file: 2009/167).

Each patient received from 1 to 5 implants. Two periodontists were involved in the surgical procedures. Immediate prosthodontic procedures and final restorations were performed by academic prosthodontists. Any patient dropouts or withdrawals, as well as adverse events, were carefully monitored during the entire investigation period. Follow-up visits were scheduled at 1 month, 3 months, 6 months, and 1 year after implant insertion. Patient-centered outcomes were evaluated 1 month after surgery.

Study population

Candidate patients for single or partial implant-supported fixed restorations were included in the study according to the following site-related inclusion criteria: alveolar bone crest ≤ 6 mm thick in the cervical region (2 mm under the crestal edge), healed sites (at least 2 months after extractions), and free of infection. Previous socket preservation or bone regeneration procedures were not considered as exclusion criteria (Figure 1).

Patients were excluded from the study according to the following criteria: alcohol or drug abuse, ASA 3 or ASA 4 general health status, smoking > 10 cigarettes per day, patients who were not available for immediate implant insertion, and patients who did not sign the informed consent. Patients were excluded at implant surgery if primary stability was not achieved (insertion torque ≤ 20 Ncm).

Surgical protocol

Antibiotics (amoxicillin 500 mg TID for 5 days), analgesics and anti-inflammatory medication (ibuprofen 600 mg TID from 3–7 days, depending on patient need), and chlorhexidine mouth rinse (TID for 7 days) were started 1 day prior to the surgery. Patients were treated under strict sterile conditions. Local anesthesia (articaine hydrochloridum 7200 mg/1.8 mL, adrenalin 1800 mg/1.8 mL) was provided. Based on computerized tomography (CT) scans and clinical assessments at the time of the surgery, 4 distinct flap designs/surgical protocols were used: (1) in case of favorable bone and keratinized soft tissue quantity, a flapless approach was chosen (FL); (2) a minimal split thickness flap was done when the bone quantity was favorable but the keratinized tissues limited (MF); (3) a full thickness flap was performed when a limited quantity of bone was available (FTF); and (4) a full thickness flap combined with GBR was done when implant threads were exposed buccally (GBR) (Figures 2 and 3). In each case, the two surgeons aligned when deciding on the appropriate surgical protocol.

GBR procedures were performed using biphasic calcium phosphate (BoneCeramic, Institut Straumann AG, Basel, Swit-

zerland) and collagen membrane (Bio-Gide, Geistlich Biomaterials, Wolhusen, Switzerland). Implants were placed according to the manufacturers' recommendations. The profile drill was used as an option, depending on the bone quality. Flaps were sutured with 4/0 silk or polypropylene sutures. Directly after the surgery, nonstandardized intra-oral X rays were acquired to identify the baseline peri-implant bone levels. Patients were provided with home care maintenance instructions and scheduled for postoperative check-ups on an individual basis.

Loading protocol

An impression was taken directly after the surgical procedure using a vinyl polysiloxane (Aquasil Ultra Monophase, Dentsply DeTrey, Constance, Germany) if primary stability was higher than 20 Ncm, thus allowing immediate implant loading. Immediate temporary restorations were designed out of occlusion, where possible. A one-abutment one-time loading protocol was used. Standard titanium or customized zirconia abutments were used to support a cemented provisional crown made in the lab (Figure 4). The abutments were connected to the implants within 48 hours postsurgery, and the provisional crowns were carefully cemented to avoid cement spreading into the sulcus (Figure 5). The lab procedure included impressions of the abutments to realize abutment replicas, as well as corresponding impression copings to realize the final impression and crown delivery (Figure 6).

Final prostheses delivery

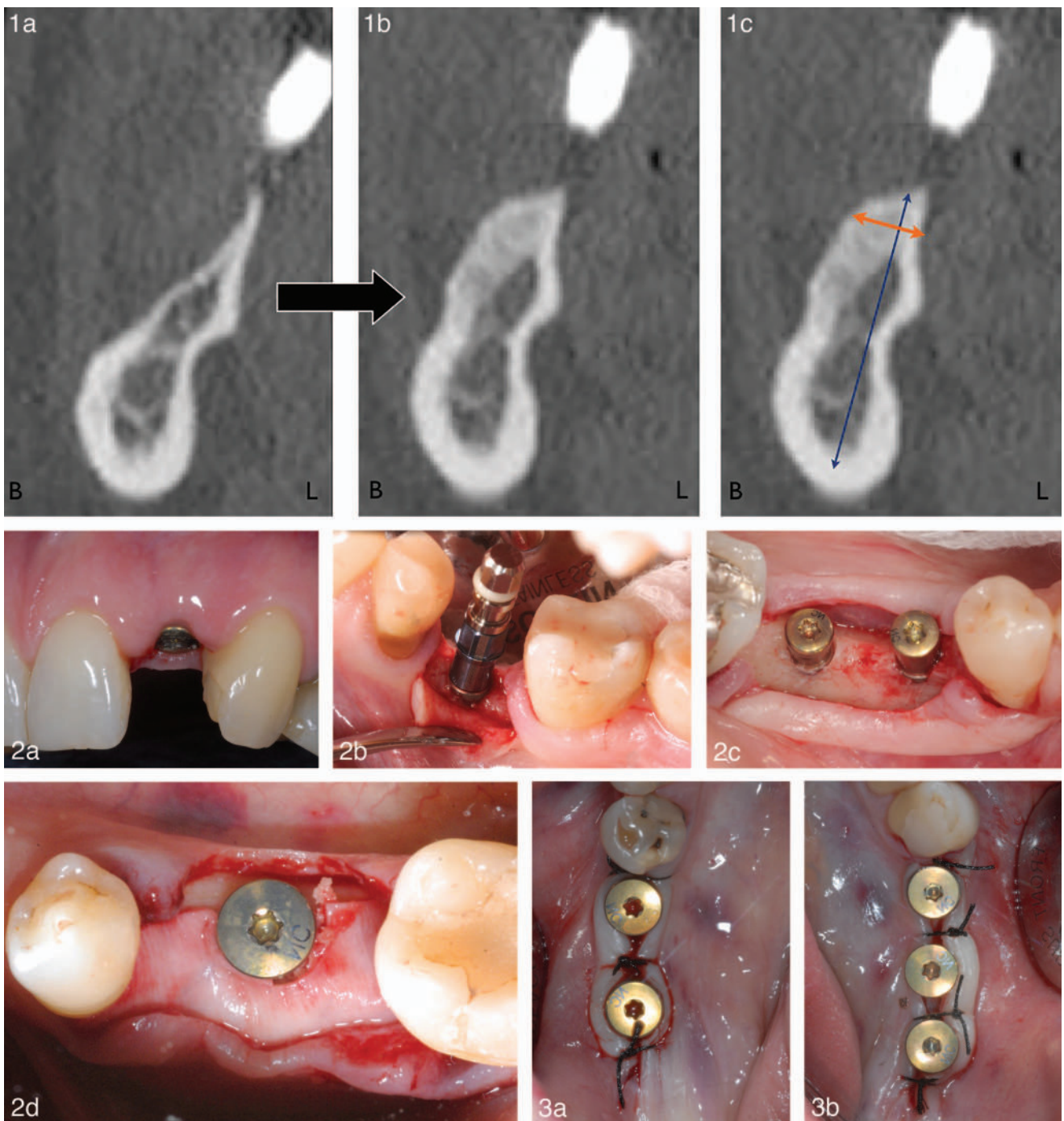
Final prosthodontic rehabilitations were carried out 2 to 6 months after implant placement. The abutments were torqued to 35 Ncm using a wrench key. The final impression was taken using the previously custom-made impression copings to avoid use of retraction cords. Porcelain-fused-to-metal or full ceramic crowns/bridges were cemented with self-adhesive resin cement (Rely X Unicem, 3M ESPE, Seefeld, Germany) (Figure 7).

Follow-up visits

Patients were recalled for clinical examination visits after 1, 3, and 6 months, and after 1 year. An intra-oral X ray was taken at each implant site after 1 year. Implant success was assessed according to the criteria defined by Buser et al.¹² Specifically, the implant was considered successful if the following parameters were met: (1) absence of recurring peri-implant infection with suppuration; (2) absence of persistent subjective complaints such as pain, foreign body sensation, or dysesthesia; (3) absence of a continuous radiolucency around the implant; and (4) absence of any detectable implant mobility. These criteria have proven to be effective in defining the success of an implant system and evaluating long-term results in clinical trials. Failing implants were considered unsuccessful.

Radiographic measurements

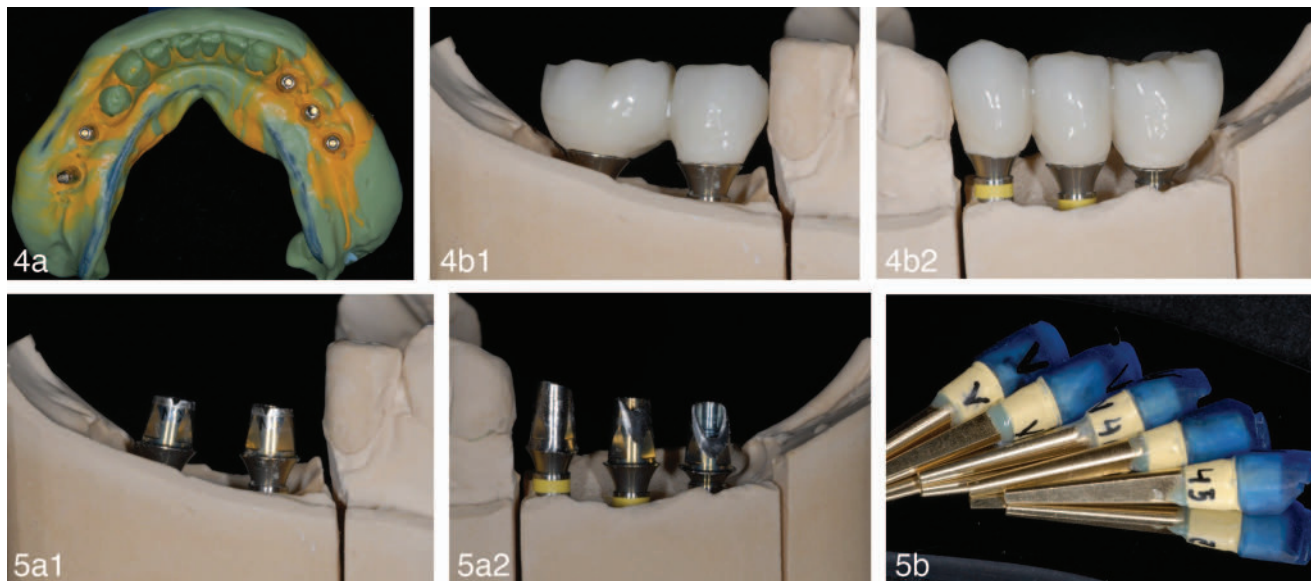
Pre-operative crestal bone widths were measured on CT scans on three levels using the crestal cervical edge as reference point. Measurements were performed perpendicular to the



FIGURES 1–3. FIGURE 1. (a) Preoperative computerized tomography (CT) scan. This patient presented a bilateral knife-edge bone resorption in the posterior mandible. (b) Postoperative CT scan. After bone regeneration, the CT scan shows that the available bone quantity could be noticeably augmented but was still limiting for implant placement. (c) Horizontal thickness was measured (5 mm) on the CT scan (orange arrow), perpendicular to the planned implant axis (blue arrow), and 2 mm below the cervical edge of the alveolar crest. **FIGURE 2.** Description of the different flap design and surgical techniques. (a) Flapless. (b) Mini split-thickness flap. (c) Full thickness flap. (d) Full thickness flap + guided bone regeneration. **FIGURE 3.** The surgical procedure of the same case whose CT scans were shown in Figure 1. Five NDIs were placed using a minimal flap in split thickness to avoid exposure of the regenerated bone.

planned implant position (Figure 1). Marginal bone levels were measured on intra-oral radiographs at baseline and at the 1-year follow-up, using the implant neck as reference point and the image processing software Image J64 (National Institutes

of Health, Bethesda, Md). Marginal bone remodeling was calculated accordingly. For intra-oral radiographs, the film was placed parallel to the implant axis and perpendicular to the X-ray beam.



FIGURES 4 AND 5. FIGURE 4. Description of the loading protocol. (a) Immediately after the surgery, an impression of the implant positions was taken. (b) The provisional resin bridges were produced in the laboratory on the selected final titanium abutments. **FIGURE 5.** (a) Height and transgingival height of the titanium abutment were selected in the lab once the working models were inserted in the articulator and according to the clinical situation. (b) Replicas of the final abutments were performed as well as the corresponding resin copings (blue cap). The copings were used directly on the titanium abutment for the final impression to allow a seamless procedure. The replicas of the final abutments were used on the master model for the realization of the final prostheses.

Patient assessment

Patient-related data were collected using a self-reporting questionnaire with VAS scales from 0 to 10. Although a nonvalidated questionnaire was used, the most relevant questions related to speech, functionality, esthetics, and confidence were assessed after 1 month and after the overall treatment.

Statistical methods

Results are presented as mean, standard deviation, standard error, minimum, median, maximum, quartiles ($Q_1 = P_{25}$ and $Q_3 = P_{75}$), and interquartile range for continuous variables, and as numbers and percentages for categorical variables. Mean values between two groups were compared by the classical Student *t* test (or Kruskal-Wallis test), while the chi-squared (χ^2) test was used to compare proportions. The paired Student *t* test (or Wilcoxon sign-rank test) was used to test the mean change between two time points. The correlation coefficient was calculated to measure the association between two continuous or ordinal variables (Spearman correlation coefficient). Statistical tests applied to implant characteristics were also adjusted to account for the fact that most patients received at least 2 implants (repeated measurements within patients). To test the time evolution from baseline to the 1-year visit, a generalized linear mixed model was applied to sequential data recorded during the study.

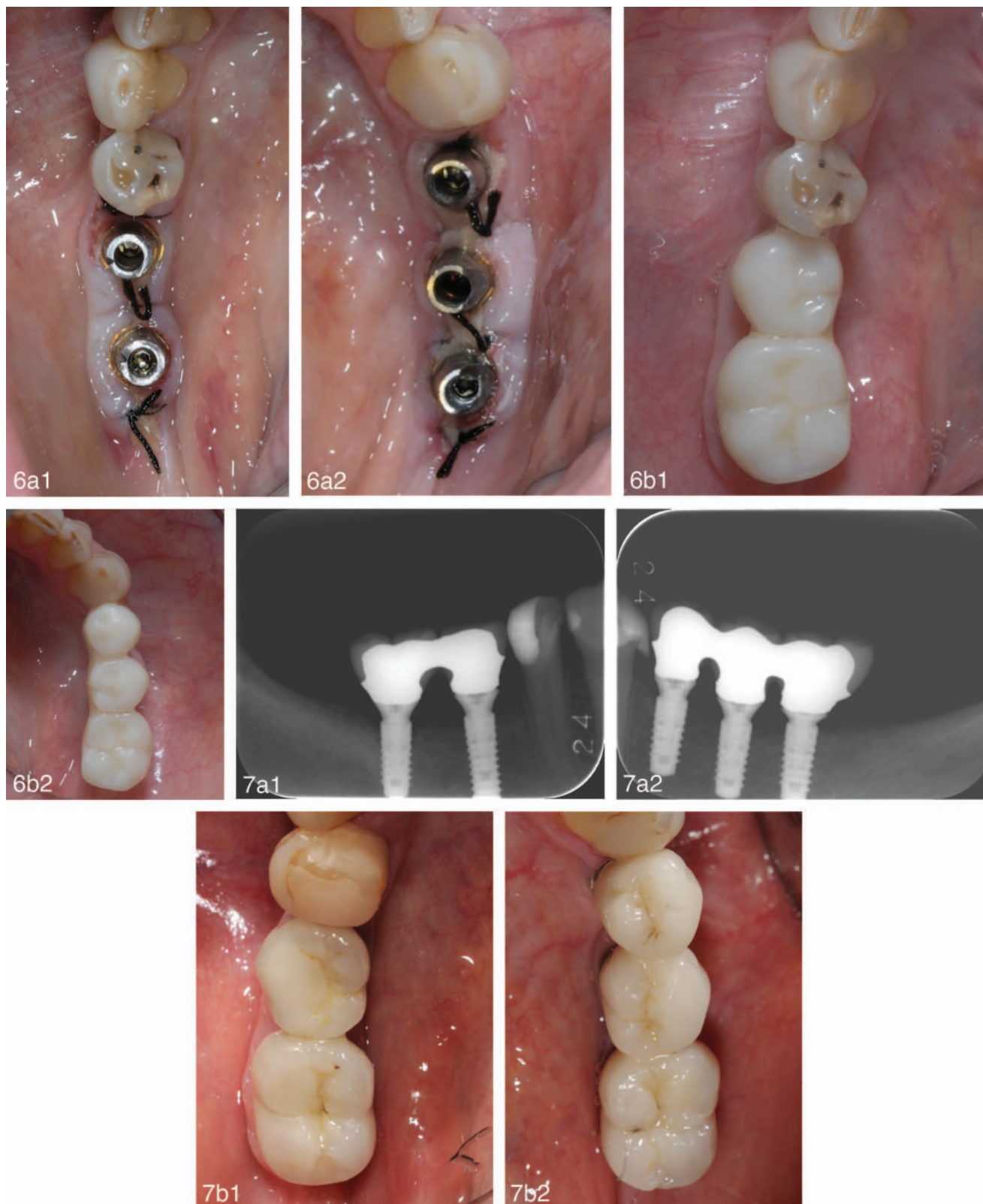
Results were considered to be significant at the 5% critical level ($P < .05$). Calculations were done using SAS version 9.3 (SAS Institute, Cary, NC), and figures were produced by S-PLUS version 7.0.

RESULTS

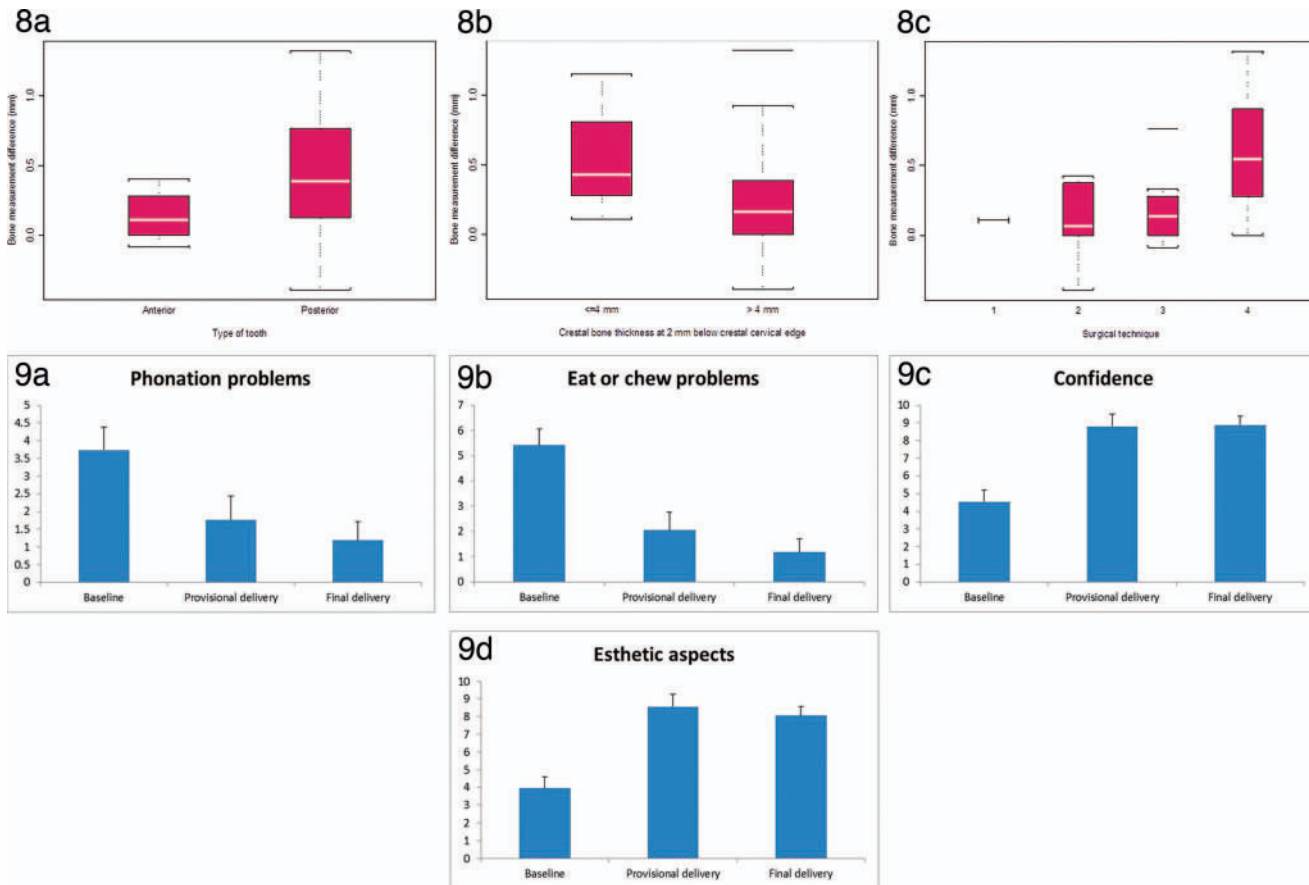
A total of 39 narrow diameter implants (Bone Level, Roxolid, 3.3-mm diameter, Institut Straumann AG) were placed in 20 patients (5 males and 15 females). Twelve (31%) implants were placed in the anterior region and 27 (69%) in the posterior mandible. The alveolar bone thickness of the included patients ranged from 2.9–6 mm. Only one implant did not reach an insertion torque higher than 20 Ncm and was therefore excluded from the study. The other 38 implants were loaded within 48 hours. Despite the limited horizontal bone thickness, GBR was necessary for only 40% of the implant sites. A full thickness flap (FTF) was performed for 30% of the implant sites, a minimal split thickness flap (MF) was used for 25% of the sites, and only 1 implant (2.6%) could be placed by a flapless (FL) procedure. Patient- and implant-related descriptive analyses are displayed in Tables 1 and 2. Two implants were removed within 2 months after the surgical intervention, which resulted in an implant survival rate of 94.7% after 1 year. The 2 failing implants were inserted in lower molar sites. A silk suture was found after 2 months under the provisional restoration of 1 failing implant; this implant was replaced after another 2 months without immediate loading. The second failing implant displayed bone sequestra on the buccal aspect; the implant was not replaced. The 2 patients with implant failures were excluded from bone-level assessment. All patients received a provisional restoration within 48 hours. Most of the patients received the final crowns or bridges within 2 to 6 months postsurgery, except for 2 patients who received the final restorations after 9 and 15 months, respectively.

All remaining implants fulfilled the success criteria after 1 year, resulting in an implant success rate of 94.7%. The mean peri-implant bone remodeling after 1 year was assessed only on 35

Journal of Oral Implantology 2015.41:693-699. Downloaded from www.joionline.org by 24.0.129.189 on 02/09/19. For personal use only.



FIGURES 6 AND 7. **FIGURE 6.** (a) Within 48 hours after surgery, the selected and adjusted final titanium abutments were placed and torqued by hand. (b) The provisional bridges, realized in the lab, were cemented using temporary cement. Care was taken to avoid cement spreading under the flap. The occlusion was fine-tuned to reduce occlusal contacts as much as possible. **FIGURE 7.** The final prosthesis, consisting of ceramic-fused-to-metal frameworks, were placed after 6 months. (a) Intra-oral radiographs after the 1-year follow-up period. Note the stable bone level, despite the very demanding initial clinical situation. (b) Clinical pictures of the final bridges after 1 year. Note the gingival health.



FIGURES 8 AND 9. FIGURE 8. Factors influencing peri-implant bone remodeling: (a) Posterior (molars/premolars) vs anterior (canines, incisors) teeth: Higher mean bone loss was found in implants placed in the posterior mandible ($0.46 \text{ mm} \pm 0.44 \text{ mm}$ vs $0.14 \text{ mm} \pm 0.17 \text{ mm}$, $P = .026$). The standard deviation was high, pointing toward substantial bone loss occurring in a limited number of implants. (b) When the initial bone thickness was $\leq 4 \text{ mm}$, the results showed a tendency for increased bone remodeling ($P = .08$). (c) Significantly higher bone remodeling was associated with full thickness flaps and GBR compared to the other surgical approaches ($P = .015$). The residual bone thickness and the need for GBR correlated. Implant sites displaying substantial bone loss often combined the 3 risk factors: Implants placed in the posterior mandible in sites with a residual bone thickness $< 4 \text{ mm}$ and the need for simultaneous GBR. **FIGURE 9.** Evaluation of the patient-centered outcomes before treatment (baseline), 1 month after the provisional restoration (provisional delivery), and after 1 year (final delivery) for the 4 assessed parameters: (a) Phonation. (b) Eating function. (c) Esthetics. (d) Confidence. All outcomes significantly improved after placement of the provisional prostheses.

implants in 18 patients because 1 patient had a surviving implant that was splinted to a failing implant and was therefore excluded from bone-level assessment. The measurements revealed a bone loss of -0.35 mm at the implant level compared to the baseline measurement performed at implant insertion.

Certain clinical parameters displayed a statistically significant effect on peri-implant bone remodeling:

- Bone loss was significantly higher for posterior implants (molars/premolars) than for anterior implants (canines/incisors) ($0.46 \text{ mm} \pm 0.44 \text{ mm}$ vs $0.14 \text{ mm} \pm 0.17 \text{ mm}$, $P = .026$) (Figure 8a);
- When a full thickness flap with GBR was performed, the mean peri-implant bone loss reached $0.59 \pm 0.41 \text{ mm}$ and was significantly higher ($P = .015$) than was the bone loss found with the other 3 surgical techniques (FL, MF, FT) (Figure 8b);
- A non-significant tendency for higher peri-implant bone remodeling ($P = .08$) was found when the initial crestal bone thickness was $< 4 \text{ mm}$ (Figure 8c);

- The implants displaying the highest bone loss ($> 0.45 \text{ mm}$) were associated with GBR, the posterior region, and with a crestal bone thickness $< 4 \text{ mm}$ in 100%, 90%, and 60% of the cases, respectively.

All studied patient-centered outcomes significantly improved after placement of the provisional restorations and remained comparable after the delivery of the final prostheses (Figure 9) (speech: $P = .015$; eating function: $P = .0014$; esthetics: $P < .0001$; confidence: $P < .0001$).

DISCUSSION

Implant survival and success rates

Both implant survival and success rates were 94.7%. These promising results were achieved despite the demanding clinical situation. More than two-thirds of the implants were placed in the posterior mandible with horizontally limited bone available, and

TABLE 1
Patient-related descriptive analyses

Age	Mean (Min–Max)	50 Years Old (21–70)
Gender	Male	15 (75%)
	Female	5 (25%)
Tobacco use	No	19 (95%)
	<10 cigarettes/day	1 (5%)
Health status	ASA I	18 (90%)
	ASA II	2 (10%)

all implants except 1 could be immediately restored, even though simultaneous GBR was performed. Only 1 implant did not achieve sufficient primary stability. Two implants failed for reasons unrelated to the implant diameter: One implant was removed prematurely because of substantial bone loss that could be attributed to an unremoved nonresorbable suture. The second failing implant displayed acute buccal inflammation and formed bone sequestra after 1 month.

The present implant survival rate and peri-implant bone remodeling are comparable to published values on standard diameter implants supporting FPDs.^(3–5) Conventional loading protocols were used in these studies as opposed to immediate loading, further emphasizing the excellent clinical performance of NDIs in the current study. Several other clinical studies have investigated the clinical performance of implants with diameters between 3 mm and 3.5 mm supporting fixed partial dentures (FPDs), with survival rates from 93.8% to 100%.^(7,8,11,13–18) Only a few studies have considered immediate provisionalization of NDIs, mainly in the anterior maxilla.^(10,11)

Immediate provisionalization

Even though immediate restorations of posterior partial edentulism may not always be required in daily practice from an esthetic point of view, the present results demonstrate that no reduction in implant survival rate should be expected. Nevertheless, 1 of the implant failures seemed to be related to the immediate provisionalization procedure, since a remaining suture was found under the restoration after 2 months. Resorbable sutures may avoid such complications. To prevent implant losses, the prosthodontists tried

to avoid dispersion of impression material and provisional cement under the flap, which the authors consider a key condition to reduce complications in the case of immediate loading.

Minimal invasive approach

All the implant sites had limited horizontal bone available. One patient presented with a crestal bone thickness of 2.9 mm in the cervical area, representing the challenging bone situation in many patients. Using NDIs, GBR was necessary in 40% of the implant sites. Therefore, 60% of the implant sites could be restored without GBR. On the one hand, this reduces the number and severity of surgical interventions and, on the other hand, reduces the costs for these patients compared to conventional treatment involving GBR. Another interesting aspect of this study is the preservation of the regenerated bone by NDIs. In cases where bone reconstruction was necessary prior to implantation, NDIs allowed preservation of the newly regenerated bone to a high degree since only a small diameter implant bed had to be prepared.

Peri-implant bone remodeling

Despite the limitation of the 2-D radiographical method the evaluation of the peri-implant bone remodeling, the average bone loss found in the present study is comparable to published values in the literature on platform-switched implants.³ The statistical analysis emphasized higher peri-implant bone loss at implant sites in the posterior mandible and at sites with a residual bone thickness of <4 mm that needed simultaneous GBR. In presence of these risk factors, a delayed loading protocol might be recommended. Indeed, the design of the present study without a control group that received delayed loading does not allow an assessment of whether the higher bone loss detected at these sites is related to the restoration protocol. Since immediate restoration in the posterior region is not often required, the authors advise to delay NDI loading or provisionalization in the posterior mandible, especially when GBR is involved.

Patient-centered outcomes

Within the limits of analyzing the patient-centered outcomes, the speech and eating function, as well as esthetics and confidence, had significantly improved as soon as the provisional restorations

TABLE 2
Site-related descriptive analyses and implant outcomes

Insertion torque	Mean (Min–Max)	31 (15–45)
Implant position	Anterior (incisors, canines)	12 (31%)
	Posterior (molars, premolars)	27(69%)
Surgical technique	FL	1 (2.6%)
	MF	10 (25.6%)
	FTF	12 (30.8%)
	GBR	16 (41%)
Bone thickness –2 mm under the most cervical edge (Figure 1)	Mean (min–max)	4.14 mm (2.9–6)
Implant outcomes	Implant survival rate	36/38 implants 94.7%
	Implant success rate	36/38 implants 94.7%
Peri-implant bone remodeling	Patient level (18)	0.25 mm (–0.2–1.1)
	Implant level (35)	0.35 mm (–0.4–1.3)

were delivered. Further significant improvements were not observed with the final prosthesis. Therefore, immediate restoration might be of interest for timely improvement of patient satisfaction.

CONCLUSION

Within the limitations of this 1-year prospective study, the following conclusions were made:

- NDIs exhibit success rates similar to published values for standard-diameter implants, even in the posterior region (molars/premolars);
- NDIs are suitable for implant treatment if the alveolar crest thickness is <6 mm;
- The use of NDIs limited the use of GBR in 60% of the present cases;
- Peri-implant bone remodeling seemed to be higher in the posterior region, when the alveolar crest was <4 mm thick, and when GBR was also required.

ABBREVIATIONS

- CT: computerized tomography
- FPD: fixed partial denture
- GBR: guided bone regeneration
- NDI: narrow-diameter implant

ACKNOWLEDGEMENTS

The authors would like to express their gratitude to Dr. Caroline Legros (Department of Removable Prosthodontics, University of Liège, Belgium) for her assistance with the patient follow-up and gratitude to Profs Adelin Albert, Laurence Seidel, and Nicolas Gillain (Department of Biostatistics, University of Liege, Belgium) for the informatics data collection and statistical analyses.

REFERENCES

1. Walton JN, MacEntee MI. Choosing or refusing oral implants: a prospective study of edentulous volunteers for a clinical trial. *Int J Prosthodont.* 2005;18:483–488.
2. Sohrabi K, Mushantat A, Esfandiari S, Feine J. How successful are

- small-diameter implants? A literature review. *Clin Oral Implants Res.* 2012;23:515–525.
3. Annibaldi S, Bignozzi I, Cristalli MP, Graziani F, La Monaca G, Polimeni A. Peri-implant marginal bone level: a systematic review and meta-analysis of studies comparing platform switching versus conventionally restored implants. *J Clin Periodontol.* 2012;39:1097–1113.
4. Pjetursson BE, Thoma D, Jung R, Zwahlen M, Zembic A. A systematic review of the survival and complication rates of implant-supported fixed dental prostheses (FDPs) after a mean observation period of at least 5 years. *Clin Oral Implants Res.* 2012;23(suppl 6):22–38.
5. Vouros ID, Kalpidis CD, Horvath A, Petrie A, Donos N. Systematic assessment of clinical outcomes in bone-level and tissue-level endosseous dental implants. *Int J Oral Maxillofac Implants.* 2012;27:1359–1374.
6. Arisan V, Bolukbasi N, Ersanli S, Ozdemir T. Evaluation of 316 narrow diameter implants followed for 5-10 years: a clinical and radiographic retrospective study. *Clin Oral Implants Res.* 2010;21:296–307.
7. Malo P, de Araujo Nobre M. Implants (3.3 mm diameter) for the rehabilitation of edentulous posterior regions: a retrospective clinical study with up to 11 years of follow-up. *Clin Implant Dent Relat Res.* 2011;13:95–103.
8. Olate S, Lyrio MC, de Moraes M, Mazzone R, Moreira RW. Influence of diameter and length of implant on early dental implant failure. *J Oral Maxillofac Surg.* 2010;68:414–419.
9. Zinsli B, Sagesser T, Mericske E, Mericske-Stern R. Clinical evaluation of small-diameter ITI implants: a prospective study. *Int J Oral Maxillofac Implants.* 2004;19:92–99.
10. Oyama K, Kan JY, Rungcharassaeng K, Lozada J. Immediate provisionalization of 3.0-mm-diameter implants replacing single missing maxillary and mandibular incisors: 1-year prospective study. *Int J Oral Maxillofac Implants.* 2012;27:173–180.
11. Sohn DS, Bae MS, Heo JU, Park JS, Yea SH, Romanos GE. Retrospective multicenter analysis of immediate provisionalization using one-piece narrow-diameter (3.0-mm) implants. *Int J Oral Maxillofac Implants.* 2011;26:163–168.
12. Buser D, Weber HP, Lang NP. Tissue integration of non-submerged implants. 1-year results of a prospective study with 100 ITI hollow-cylinder and hollow-screw implants. *Clin Oral Implants Res.* 1990;1:33–40.
13. Andersen E, Saxegaard E, Knutsen BM, Haanaes HR. A prospective clinical study evaluating the safety and effectiveness of narrow-diameter threaded implants in the anterior region of the maxilla. *Int J Oral Maxillofac Implants.* 2001;16:217–224.
14. Comfort MB, Chu FC, Chai J, Wat PY, Chow TW. A 5-year prospective study on small diameter screw-shaped oral implants. *J Oral Rehabil.* 2005;32:341–345.
15. Degidi M, Piattelli A, Carinci F. Clinical outcome of narrow diameter implants: a retrospective study of 510 implants. *J Periodontol.* 2008;79:49–54.
16. Reddy MS, O'Neal SJ, Haigh S, Aponte-Wesson R, Geurs NC. Initial clinical efficacy of 3-mm implants immediately placed into function in conditions of limited spacing. *Int J Oral Maxillofac Implants.* 2008;23:281–288.
17. Romeo E, Lops D, Amorfini L, Chiapasco M, Ghisolfi M, Vogel G. Clinical and radiographic evaluation of small-diameter (3.3-mm) implants followed for 1–7 years: a longitudinal study. *Clin Oral Implants Res.* 2006;17:139–148.
18. Veltri M, Ferrari M, Balleri P. One-year outcome of narrow diameter blasted implants for rehabilitation of maxillas with knife-edge resorption. *Clin Oral Implants Res.* 2008;19:1069–1073.

Journal of Oral Implantology 2015;41:693-699. Downloaded from www.joionline.org by 24.0.129.189 on 02/09/19. For personal use only.