

## SYSTEMATIC REVIEW



# Mini dental implant overdenture as an alternative treatment (systematic review)

Doaa Amr A. Heshmat Rostom<sup>1</sup>, Adnan Al-Fahd<sup>2</sup>

<sup>1</sup>Department of Prosthodontics, Faculty of Oral and Dental Medicine, Cairo University, Cairo, Egypt, <sup>2</sup>Department of Prosthodontics, Faculty of Oral and Dental Medicine, IBB University, Yemen, Egypt

## Keywords

Mandible, marginal bone loss, mini implant, overdenture, survival rate

## Correspondence

Doaa Amr A. Heshmat Rostom, Department of Prosthodontics, Faculty of Oral and Dental Medicine, Cairo University, Cairo, Egypt.  
Phone: 01006455491. E-mail: doaa.heshmat@dentistry.cu.edu.eg

Received 17 September 2017;

Accepted 28 October 2017

doi: 10.15713/ins.idmjar.78

## Abstract

**Background:** Patients with narrow alveolar ridges requiring dental implants may be managed by residual ridge augmentation or guided bone regeneration procedures followed by the placement of conventional diameter implants. All these procedures need more time, more cost, and more clinician experience. Mini implants are an alternative option in case of the reduced residual alveolar ridge.

**Aim:** The aim of this study was to evaluate the crestal bone changes, survival rates, and patient satisfaction with mini dental implant.

**Methodology:** An electronic searching was performed in the following databases, Pubmed (1990 to 25 October 2016) and Cochran (1999 to 2016). In addition, hand searching was performed in implant-related journals and through the references of included studies.

**Result:** Four articles resulted after the final filtration, from which three studies were randomized controlled trials and one non-randomized controlled trial. The follow-up period was extended at least 1 year in all studies. The results of the included studies reveal that the marginal bone loss, survival rate, and patient satisfaction of the mini implant were comparable to those resulting from the conventional implants.

**Conclusion:** No significant difference was observed between the mini implant and the conventional implants regarding the marginal bone loss, implant survival rate, and patient satisfaction. However, this review depends on few numbers of studies that accompanied with a high degree of bias, so more evidence to validate this treatment is still necessary.

**Clinical Significance:** The flapless technique of the small implant diameter offers the advantage of less invasion and less trauma to the tissue. Furthermore, the mini implants approach makes promise solution for those patients with medical and/or financial problems to use conventional implants so that they increase the clinical applications of dental implants.

## Introduction

Usually after teeth loss, alveolar bone continues to resorb that leads to lack of stability and retention, especially of the lower denture, which in turn causes lack of self-confidence and reduction in chewing efficiency.<sup>[1-3]</sup> Dental rehabilitation of completely edentulous patients with traditional removable prosthesis creates functional and psychological problems for the patients because of the frequent instability of the prosthesis.<sup>[4]</sup>

Many patients are dissatisfied with their conventional dentures due to functional disability, pain, psychological discomfort, retention, stability, esthetics, and speech discomfort

with denture.<sup>[5]</sup> Patients who received implant-supported overdentures showed increased satisfaction and chewing ability, more self-confidence compared to those with a complete denture. However, dental implants require adequate bone dimensions for their stability. If the available bone is insufficient, further surgical processes such as bone grafting are required.<sup>[6]</sup>

Patients with narrow alveolar ridges requiring dental implants may be managed by residual ridge augmentation or guided bone regeneration procedures followed by the placement of conventional diameter implants. All these procedures need more time, more cost, and more clinician

experience.<sup>[7]</sup> Mini implants are an alternative option in case of reduced residual alveolar ridge. Their reduced diameter <3 mm allow for easy and safe insertion in narrow ridges. Moreover, the mini implant technique is simpler and faster, and it is often done with flapless.<sup>[7,8]</sup>

Mini implant was first introduced in 1994 to support an interim prosthesis, and on implant removal, it was noted that removal of these implants from the bone was difficult because it osseointegrated within the bone.<sup>[10-12]</sup>

Mini implants loading can delay after 3 months from implant placement, or it can be loaded immediately within the atrophic bone according to the amount of the primary stability, the insertion torque should be at least 30 Ncm.<sup>[13]</sup> The minimum number of mini implants required for retaining complete removable dentures may be 6 in the maxilla and 4 in the mandible. The implants should be parallel to each other, and the degree of malalignment should not exceed 20° to allow ease denture seating.<sup>[13-15]</sup>

Some clinical reports have claimed that mini implant used for retaining mandibular dentures are successful.<sup>[16,17]</sup> Some other studies recorded the survival rate of mini implant-supported mandibular complete dentures is in the range of 81-97.4%.<sup>[14,18]</sup> However, scientific evidence regarding clinical outcomes of the mini dental implants (MDI) retained overdentures is relatively limited in the literature.<sup>[19,20]</sup>

The aim of this study was to evaluate the crestal bone changes, survival rates, and patient satisfaction with mini dental implant.

## Methodology

This systematic review was developed according to the PRISMA, and it was formulated using (PICO), participant, intervention, comparison, and outcome (1) Participant: Completely edentulous patient. (2) Intervention: Mini implant-supported mandibular overdenture. (3) Comparison: Other implant alternative treatment. (4) Outcome: Implant survival, peri-implant bone change, and patient satisfaction.

The focused question was “in the completely edentulous patient.” Can the mini implants-supported overdenture serve as a good alternative treatment, regarding implant survival, peri-implant bone change, and patient satisfaction?

Electronic searching was performed in the following databases: (1) PubMed (1990 to 25 October 2016) and (2) Cochran (1999 to 2016). The following search terms were in combination, mini implant, mandible, and overdenture.

Hand searching of the years from 1999 to 2016 was done from the following journals: Clinical Implant Dentistry and Related Research, Clinical Oral Implants Research, Implant Dentistry, International Journal of Oral and Maxillofacial Implants, International Journal of Periodontics and Restorative Dentistry, International Journal of Prosthodontics, Journal of Oral Implantology, Journal of Oral Rehabilitation, and Journal of Prosthetic Dentistry. Bibliographies of selected articles were further searched for potentially relevant articles. The study selection procedure was shown in Graph 1.

## Selection criteria

The literature review and data extraction were performed by the two authors.

The inclusion criteria for the article were selected, and any disagreement between the authors was discussed.

The following inclusion criteria were included in the study:

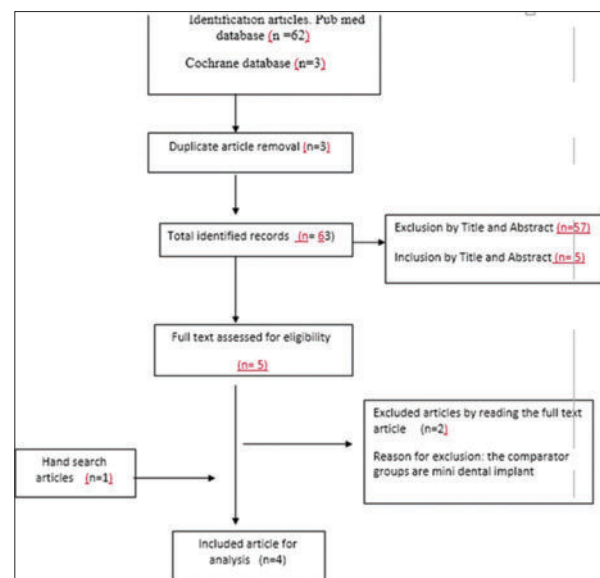
1. Randomized controlled studied and cohort studies
2. Mini implant in mandible diameter <3.5 mm
3. English-language publication
4. Only mandibular edentulous ridge.

However, the following exclusion criteria were excluded from the study:

1. Case reports, reviews, and non-clinical studies
2. Finite element analysis studies
3. Maxillary mini implant
4. Explanation of technique or manual
5. Animal studies
6. Small-diameter implants that were not meant for permanent use.

The electronic search was done through 3 steps. At step 1, articles titles were screened from the 2 electronic databases, each investigator independently analyzed relevant titles regarding the selected inclusion criteria, and any disagreement was discussed by the 2 authors. At step 2, both authors separately screened the abstracts of all selected titles. Again, any disagreement was discussed by the 2 authors. At step 3, the investigators studied all full-text articles that were included. Selection of the article was based on the inclusion and exclusion criteria that were applied and the validity of the methodology, and then, the qualitative and quantitative data were extracted.

A data extraction form was developed to collect general information (title, year of publication, and number of implants



Graph 1: Search strategy

used, implant system, implant length and diameter, outcome variable, and follow-up period) [Tables 1-4].

**Results**

The final electronic search on databases revealed 62 records. After removal of duplicates, 5 articles remained, and the hand searching revealed one additional studies. Two articles were excluded after full-text screening because the comparator groups were mini dental implant. The total number of included article were 4 articles, 3 were a randomized controlled<sup>[9,21,22]</sup> and one non-randomized controlled.<sup>[18]</sup> Details about the search strategy are shown in Graphs 2 and 3.

**Description of studies**


The included studies were four studies. In a non-randomized prospective study,<sup>[18]</sup> the number of the participants were 22, and they were divided into 2 groups, the study group including 99 implants received 4-5 MDI with diameter 1.8-2.4 mm and length 13-15 mm, the control group were 10 participants including 35 implants received 2-4 conventional dental implants with diameter 3.3-3.7 mm and length: 11-13 mm, the outcome of the study was the assessment of bone density around the implant from computed tomography data, and patients were followed for 2 years. The study out was examined 3, 6, 12, and 24 months after implant placement. This study showed that mini implant survival was 90%.

Souza *et al.* (2015)<sup>[9]</sup> carried out a randomized control study. The randomization (ratio: 1:1:1) was based on computer-generated numbers enclosed in sealed, opaque envelopes. The number of the participants were 120, and they were divided into three groups, compared mandibular overdentures retained by 2 or 4 mini implants with standard implants. The follow-up study was 1 year. Complications such as lost implant were assessed after 3, 6, and 12 months from implant placement. The

survival rate of mini implants is not as high as that of standard implants. However, patient satisfaction evaluated by the Oral Health Impact Profile in edentulous adults after 12 months, the result indicating that the 2 or 4 mini implants in the mandibular arch resulted in slightly better oral health-related quality of life. The mean values for most patient satisfaction and masticatory ability in mini implants compared with standard implants items were also higher with 4 mini implants and regarding ease in speaking, comfort, and esthetics; all groups were doing a similar effect.

Ribeiro *et al.* (2015)<sup>[21]</sup> reported a randomized clinical trial. This study compared post-operative pain and discomfort following the insertion of mini implants and conventional implant for the retention of mandibular overdentures. A total of 120 patients divided into three groups, group 1: Four mini implants in the arch, total of 120 patients were divided into three groups, Group 1: Four mini implants in the arch, total number of implants were 152, Group II: Two mini implant, total number of implants were 84 and a flapless technique whenever possible and if not possible, a small pericrestal incision of approximately 3 mm was performed, and Group III: Two standard implants, total number of implants were 80, osteotomy was done with flap reflection. Seven days after implant insertion, patients answered questions (100 mm visual analog scales) for evaluation the patient satisfaction. It was concluded that that pain was at its highest level in 4 mini implant group, and the pain was moderate in 2 mini implant group, so pain is related to number of surgical sites, and it was reported that the easy of implant insertion and oral hygiene is better in 2 mini implants than the 2 conventional implant group.

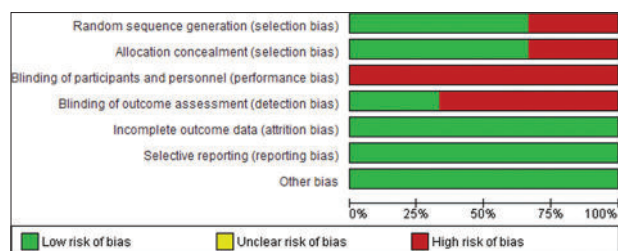
Bayari (2015)<sup>[22]</sup> compared mini dental implants, ball-type single piece implant, and screw-type tapered root-form implants for supporting complete overdenture. Fourteen completely edentulous patients divided into two groups to evaluate the bone density and bone height changes around the implants at 0, 6, and 12 months after loading. The result proved that there was no significant difference found between the two types of implants.



**Graph 2:** Risk of bias summary: Judgments about each risk of bias item for each included study

**Data analysis**

No statistical analysis of data was performed because of the divergence of the study designs outcomes.



**Graph 3:** Risk of bias graph: Judgments about each risk of bias item presented as percentages across all included studies

**Table 1:** Temizel *et al.* 2016<sup>[18]</sup>

Study design	Non-randomized clinical trial
Follow-up	2 year
Age	Not clear
Participant number	Total number=32 Study group=22 Control=99
Implants number	Study group=99 Control=35
Implant company	Mini implant (3M, ESPE), conventional implant (Dentaurum implant Gmb)
Implant length×diameter	Study group (length 13/15, diameter 1.8-2.4) Control group (length 11/13, diameter 3.3-3.7)
Surgical technique	Flap
Loading time	Delayed loading
Implant failure	One conventional implant
Successes rate	90%
Bone changes	Study group (1250 HU) control group (1100 HU)
Patient satisfaction	N/A

**Table 2:** Souez *et al.* 2015<sup>[9]</sup>

Study design	Randomized clinical trial
Follow-up	1 year
Age	>45 year
Participant number	Total number=120 4 mini implant group=38 2 mini implant=42 2 standard implant=40
Implants number	4 mini implant group=152 2 mini implant=84 2 standard implant=80
Implant company	Mini implant (Mini-Drive Lock MDL; Intra-Lock International Inc.), conventional implant (Morse-Lock Straight 4.0 mm, Intra-Lock International Inc.)
Implant length×diameter	Mini implant group (length 10, diameter 2) Control group (length 10, diameter 4)
Surgical technique	Flap
Loading time	Delayed loading
Implant failure	4 mini implant group=10 and 6 implants lost before loading 2 mini implant group=9 and 6 failed before loading 2 standard implant=1
Successes rate	4 mini implant group=89% 2 mini implant=82% 2 standard implant=99%
Bone changes	N/A

**Table 3:** Ribeiro *et al.* 2015<sup>[21]</sup>

Study design	Randomized clinical trial
Follow-up	7 day
Age	59±8.5
Participant number	Total number=120 4 mini implant group=38 2 mini implant=42 2 standard implant=40
Implants number	4 mini implant group=152 2 mini implant=84 2 standard implant=80
Implant company	Mini implant (Mini-Drive Lock MDL; Intra-Lock International Inc), Conventional implant (Morse-Lock Straight 4.0 mm, Intra-Lock International Inc.)
Implant length×diameter	Mini implant group (length 10, diameter 2) Control group (length 10, diameter 4)
Surgical technique	Mini implant group=flapless technique whenever viable and if not possible, a small pericrestal incision of approximately 3 mm was performed Standard group=flap technique
Loading time	Delayed loading
Implant failure	N/A
Successes rate	N/A
Bone changes	N/A

**Table 4:** Beyari *et al.* 2015<sup>[22]</sup>

Study design	Randomized clinical trial
Follow-up	12 months
Age	52
Participant number	Total number=14 A group receives two screw type tapered root form implants=7 A group receives two ball single piece mini implants=7
Implants number	N/A
Implant company	Mini implant (Mini Implants, OsteoCare™ Implant System Ltd. Berkshire, UK), Conventional implant (Legacy, Spectra system, Implant Direct, U.S.A.)
Implant length×diameter	Mini implant group (diameter=2.8 mm, length=13) Control group (not mentioned)
Surgical technique	Flapless technique
Loading time	Delayed loading
Bone changes	Bone density percent change for group 1, group 2 was 0.17, 0.56 ( $P = 0.06$ ) Bone height percent change for group 1, group 2 was - 9.79, -11.99 ( $P = 0.003$ ) Mean bone height change for group 1, group 2 was 18.77, 18.02 ( $P = 0.9$ )

### Peri implant bone changes

A randomized clinical trial by Bayen (2015) evaluated all patients radiographically at the time of loading (baseline), 6 months, and 12 months.<sup>[22]</sup> The result revealed that the bone density percent change for group 1 and group 2 was 0.17 and 0.56 ( $P = 0.06$ ). Bone height percent change for group 1 and group 2 was  $-9.79$  and  $-11.99$  ( $P = 0.003$ ). Mean bone height change for group 1 and group 2 was 18.77 and 18.02 ( $P = 0.9$ ), respectively.

One non-randomized article, Temizel *et al.* (2016)<sup>[18]</sup> reported the bone density and bone height changes around mini implant in comparison to conventional implant after 2 years. A total number of 99 mini implants used with implant length equal 13-15 mm and implant diameter 1.8-2.4 mm, and a total of 35 conventional implants used with implant length equal 11/13 mm and implant diameter 3.3/3.7 mm. The mean Hounsfield (HU) value in the participants who received MDI was significantly ( $P = 0.035$ ) higher (1250 HU) than that in the participants who received conventional dental implants (1100 HU). The measured bone height and cortical thickness showed no significant differences ( $P = 0.930$  and  $P = 0.940$ , respectively).

### Implant survival

Temizel *et al.* (2016)<sup>[18]</sup> reported that only one conventional implant lost after 18 months and no mini implant lost and the survival rates for mini dental implants and conventional dental implants were comparable 90%. While Souza *et al.* (2015)<sup>[9]</sup> reported that implant survival rate was 89%, 82%, and 99% for 4 mini implants group, 2 mini implants, or 2 standard implants group, respectively.

### Patient satisfaction

Patient satisfactions for mini implant comparing with conventional implant were varied between the studies regarding the timing of recordings patient satisfaction and patient satisfaction item, a study record pain, discomfort after 1 year, and the other one record was after 7 days. Souez *et al.* (2015)<sup>[9]</sup> reported that after 12 months the mean values for most patient satisfaction and masticatory ability in mini implants compared with standard implants items were also higher with 4 mini implant, but they did not evaluate post-operative pain, while Robiero *et al.* (2015)<sup>[21]</sup> were concluding that that pain was at its highest level in 4 mini implant group 7-day post-operatively.

### Discussion

The purpose of this systematic review was to know the available evidence on the mini dental implant, to evaluate the survival rate, crestal bone changes, and patient satisfaction in overdenture support by mini implants. The result of the search strategy from 1990 to 2016 reveals retrospective studies and one-arm prospective studied which they are of low evidence according to a hierarchy level of evidence.<sup>[19]</sup>

Our search results in only one non-randomized clinical trial and 3 randomized clinical trials. There were little studies comparing mini implants with narrow diameter with standard dental implants for complete denture additionally. There were no much studies assess the perimini implant bone changes, and Temizel *et al.* (2016)<sup>[18]</sup> reported that there is a significant difference to the mini implant group ( $P = 0.035$ ). The participants who had received MDI had higher HU values than those who received conventional dental implants. The measured bone height and cortical thickness showed no significant differences ( $P = 0.930$  and  $P = 0.940$ , respectively).

The method of reporting mini implant follow-up in different studies was variable that did not allow for pooling the data for statistical analysis. Souza *et al.* (2015)<sup>[9]</sup> study follow-up was 1 year. Ribeiro *et al.* (2015)<sup>[21]</sup> recorded the patient satisfaction in a questioner after 7 days.

The quality assessment of the included trials was undertaken independently and in duplicate by two review authors as part of the data extraction process. Temizel *et al.* (2016)<sup>[18]</sup> follow-up was 2 years, the author said that it was non-randomized trial study because it is contraindicated to use standard size implant in a narrow residual ridge without performing surgical modification. They reported that it was difficult to blind the surgeon, but the statistician was blind to minimize the bias.

According to Cochrane risk of bias assessment for randomization clinical trials, as shown in Graphs 2 and 3, the quality of the evidence was assessed. The randomization and sample size calculation, were adequate and allocation concealment was done in the two randomized control studies.<sup>[9,21]</sup> to reduce selection bias. Regarding blindness for the 2 included randomization, clinical trials<sup>[9,21]</sup> were unclear in contrast to the non-randomized study.<sup>[18]</sup>

Completeness of follow-up and dropout was not reported in Ribeiro *et al.* (2015),<sup>[21]</sup> but in Souza *et al.* (2015),<sup>[9]</sup> the number of the dropout and withdrawals in each treatment group was clear and intention-to-treat analysis was done to manage the dropout.

Beyari (2015)<sup>[22]</sup> is of low evidence due to unclear randomization and allocation concealment method, and he did not explained how he estimate the sample size. The majority of the study was setting an inclusion and exclusion criteria which is important to reduce selection bias. However, all the studies have small sample size which may affect on the final result.

The patient satisfaction result in the included studies could not be combined in one analysis due to variation in the follow-up time, follow-up items, and the surgical technique.

Depending on this systematic review, it is still difficult to draw strong evidence regarding the real effect of mini implant on peri implant bone change, implant survival, and patient satisfaction in comparison to conventional implant due to limited randomized trial and small studies sample size. Consequently, a well-designed randomized controlled trials with long follow-up periods still strongly recommended.

## Conclusion

There was no significant difference between the mini implant and the conventional implants regarding the marginal bone loss, implant survival rate, and patient satisfaction. However, this review depends on few number of studies that accompanied with a high degree of bias, so more evidence to validate this treatment is still necessary.

## References

1. Doundoulakis JH, Eckert SE, Lindquist CC, Jeffcoat MK. The implant-supported overdenture as an alternative to the complete mandibular denture. *J Am Dent Assoc* 2003;134:1455-8.
2. Misch CE. Contemporary implant dentistry. Missouri: Elsevier Mosby; 2008. p. 15, 134-141, 294-299, 300-308, 421-466, 654, 812-813, 818,833, 1073.
3. Albaker AM. The oral health-related quality of life in edentulous patients treated with conventional complete dentures. *Gerodontology* 2012;1-6. DOI: 10.1111/j.1741-2358.2012.00645.
4. Atchison KA, Dolan TA. Development of the geriatric oral health assessment index. *J Dent Educ* 1990;54(11):680-7.
5. Veyrune JL, Tubert-Jeannin S, Dutheil C, Riordan PJ. Impact of new prostheses on the oral health related quality of life of edentulous patients. *Gerodontology* 2005;22:3-9.
6. Morais JA, Heydecke G, Pawliuk J, Lund JP, Feine JS. The effects of mandibular two-implant overdentures on nutrition in elderly edentulous individuals. *J Dent Res* 2003;82:53-8.
7. Sohrabi K, Mushantat A, Esfandiari S, Feine J. How successful are small-diameter implants? A literature review. *Clin Oral Implants Res* 2012;23:515-25.
8. Mazor Z, Steigmann M, Leshem R, Peleg M. Mini-implants to reconstruct missing teeth in severe ridge deficiency and small interdental space: A 5-year case series. *Implant Dent* 2004;13:336-41.
9. de Souza RF, Ribeiro AB, Vecchia MP, Costa L, Cunha TR, Reis AC, *et al.* Mini vs. Standard implants for mandibular overdentures: A randomized trial. *J Dent Res* 2015;94:1376-84.
10. Preoteasa E, Imre M, Preoteasa CT. A 3-year follow-up study of overdentures retained by mini-dental implants. *Int J Oral Maxillofac Implants* 2014;29:1170-6.
11. Jofré J, Conrady Y, Carrasco C. Survival of splinted mini-implants after contamination with stainless steel. *Int J Oral Maxillofac Implants* 2010;25(2):351-6.
12. Elsyad MA. Prosthetic aspects and patient satisfaction with resilient liner and clip attach-ments for bar-and implant-retained mandibular overdentures: A 3-year randomized clinical study. *Int J Prosthodont* 2012;25:148-56.
13. Flanagan D, Mascolo A. The mini dental implant in fixed and removable prosthetics: A review. *J Oral Implantol* 2011;37 Spec No:123-32.
14. Shatkin TE, Shatkin S, Oppenheimer BD. Mini dental implants for the general dentist. *Compend Contin Educ Dent* 2003;24:26-34.
15. Froum S, Emtiaz S, Bloom MJ, Scolnick J, Tarnow DP. The use of transitional implants for immediate fixed temporary prostheses in cases of implant restorations. *Pract Periodontics Aesthet Dent* 1998;10:737-46.
16. Bulard RA. Mini dental implants: Enhancing patient satisfaction and practice income. *Dent Today* 2001;20:82-5.
17. Griffiths TM, Collins CP, Collins PC. Mini dental implants: An adjunct for retention, stability, and comfort for the edentulous patient. *Oral Surg Oral Med Oral Pathol Oral Radiol Endod* 2005;100:e81-4.
18. Temizel S, Heinemann F, Dirk C, Bourauel C, Hasan I. Clinical and radiological investigations of mandibular overdentures supported by conventional or mini-dental implants: A 2-year prospective follow-up study. *J Prosthet Dent* 2017;117:239-46.
19. Australian Government. NHMRC: How to use the Evidence : Assessment and Application of Scientific Evidence. Available from: [http://www.nhmrc.gov.au/\\_files\\_nhmrc/file/publications/synopses/cp69.pdf](http://www.nhmrc.gov.au/_files_nhmrc/file/publications/synopses/cp69.pdf). [Last accessed on 2009 Dec 16].
20. Shatkin TE, Shatkin S, Oppenheimer BD, Oppenheimer AJ. Mini dental implants for long-term fixed and removable prosthetics: A retrospective analysis of 2514 implants placed over a five-year period. *Compend Contin Educ Dent* 2007;28:92-9.
21. Ribeiro AB, Vecchia MP, Cunha TR, Sorgini DB, Dos AC. Oral rehabilitation short-term post-operative pain and discomfort following insertion of mini-implants for retaining mandibular overdentures : A randomized controlled trial. 2015;4. DOI: 10.1111/joor.12287.
22. Beyari MM. Comparative study between two types of implants supporting mandibular overdenture. *Int J Surg Res* 2015;4(2):15-18.

**How to cite this article:** Rostom DA, Al-Fahd A. Mini dental implant overdenture as an alternative treatment (systematic review). *Int Dent Med J Adv Res* 2017;3:1-6.

This work is licensed under a Creative Commons Attribution 4.0 International License. The images or other third party material in this article are included in the article's Creative Commons license, unless indicated otherwise in the credit line; if the material is not included under the Creative Commons license, users will need to obtain permission from the license holder to reproduce the material. To view a copy of this license, visit <http://creativecommons.org/licenses/by/4.0/> © Rostom DA, Al-Fahd A. 2017