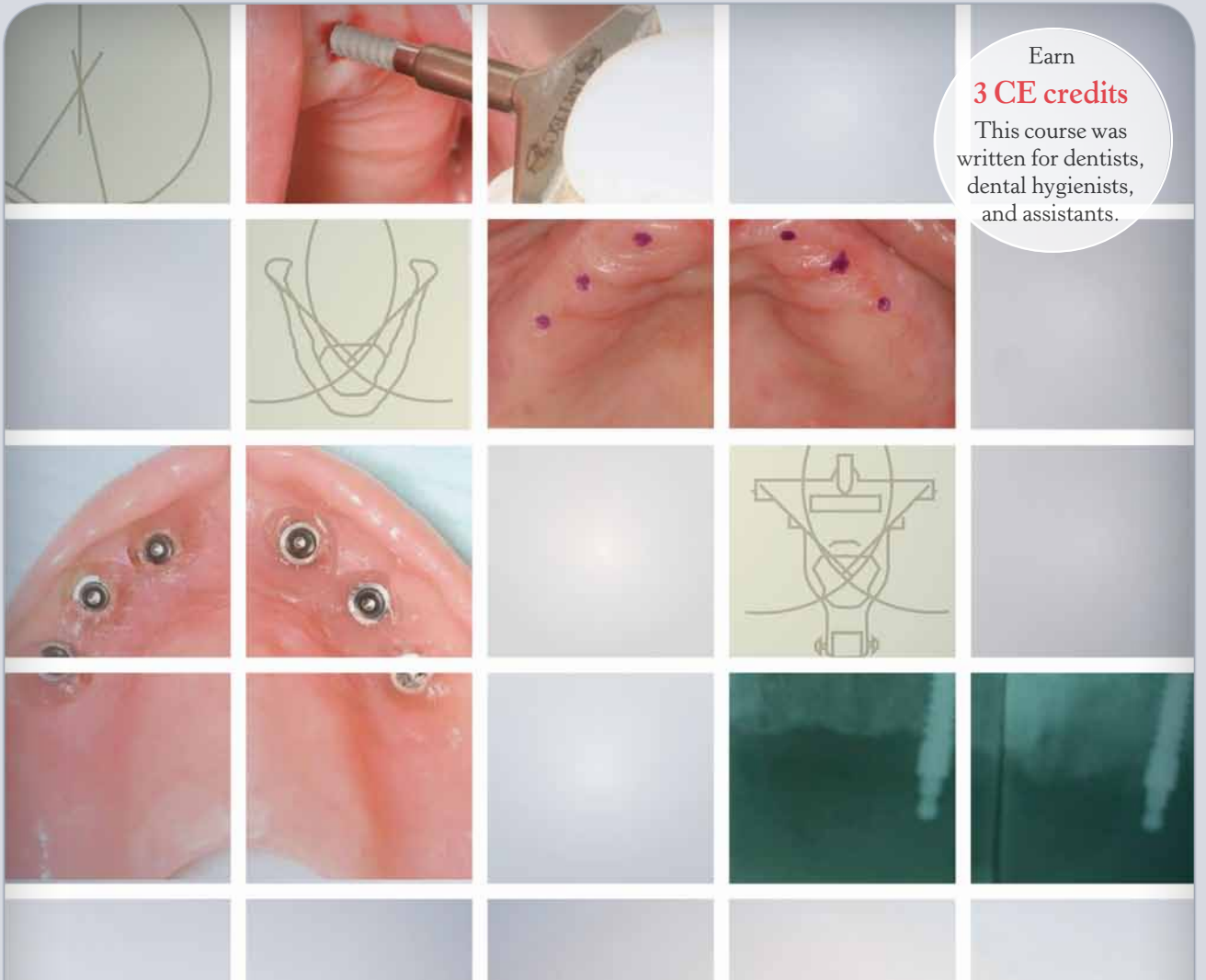

Earn  
**3 CE credits**  
 This course was written for dentists, dental hygienists, and assistants.

# An Overview of Mini-Implants and Their Role in Complete Denture Treatment

A Peer-Reviewed Publication  
 Written by Jeffrey C. Hoos, DMD

**ADA CERP**® | Continuing Education Recognition Program

PennWell is an ADA CERP recognized provider. ADA CERP is a service of the American Dental Association to assist dental professionals in identifying quality providers of continuing dental education. ADA CERP does not approve or endorse individual courses or instructors, nor does it imply acceptance of credit hours by boards of dentistry. Concerns or complaints about a CE provider may be directed to the provider or to ADA CERP at [www.ada.org/goto/cerp](http://www.ada.org/goto/cerp).

PennWell designates this activity for 3 Continuing Educational Credits



Publication date: April 2011  
 Expiry date: March 2014

**Go Green, Go Online to take your course**

Supplement to PennWell publications. This course has been made possible through an unrestricted educational grant. The cost of this CE course is \$59.00 for 3 CE credits.  
**Cancellation/Refund Policy:** Any participant who is not 100% satisfied with this course can request a full refund by contacting PennWell in writing.

## Educational Objectives

The overall goal of this course is to provide the reader with information on the indications and use of mini-implants. On completion of this article, the reader will be able to do the following:

1. List and describe the indications for implants and mini-implants
2. List and describe the clinical challenges that may be present in edentulous patients
3. List and describe the goals of complete denture fabrication
4. List and describe the types of mini-implants and overdenture attachments
5. List and describe the steps involved in providing patients with mini-implants.

## Abstract

Implants and mini-implants have been cleared by the Food and Drug Administration for a considerable period of time. They are indicated for several treatment modalities, including fixed prostheses and removable complete dentures, and have been found to improve treatment outcomes with complete dentures – particularly where anatomical challenges are present that otherwise result in reduced stability and retention of the denture(s). A step-by-step process is essential for success, and the goals of denture fabrication can be met through careful treatment planning, following the standard steps required for denture fabrication and, where indicated, using mini-implants.

## Introduction

The introduction of root-form dental implants expanded the types of treatment that dentists can provide to their patients and, as the science of dental implants developed, many different types of implants were designed with various diameters and lengths. The first implant diameters to be introduced were the standard-diameter implants – typically around 3.75 mm – followed by wider and narrower implants, then mini-implants. The diameter of mini-implants typically ranges from 1.8 mm to 2.9 mm, and the diameters of narrow, standard and wide implants typically range in combination from 3 mm to as much as 6 mm. The 2.9 mm mini-implants are also known as hybrid implants, as their diameter approximates that of narrow-diameter root-form implants.

## Indications for mini-implants

Root-form dental implants were cleared by the Food and Drug Administration (FDA) from the 1970s onward. These have become a mainstream treatment with high success rates and are utilized for implant-retained crowns, fixed prostheses and overdentures. Initially, mini-implants were cleared for use as transitional (temporary) implants to help support temporary removable prostheses, with the objective of transitioning over to standard implants when the permanent prostheses were planned for. By first using mini-implants, some stability was achieved while healing and bone remodeling occurred, and if

these could be easily explanted the site could then be widened as an osteotomy site for placement of the wider (permanent) implant. In 1997, mini-implants were cleared by the FDA for long-term use.<sup>1</sup> Mini-implants have also been accepted for transitional and long-term use by the Canadian regulatory authorities (Health Canada in Ottawa). Mini-implants are indicated for use in restorative dentistry and orthodontics. In orthodontics, they are used as temporary anchorage devices to enable more rapid and more complex tooth movements than would otherwise be possible within a given time frame. These mini-implants, “TADs,” provide an anchor point toward which the teeth are moved. A systematic review by Reynders et al. of 19 studies of mini-implants less than 2.5 mm in diameter used as temporary anchorage devices during orthodontic treatment led to the conclusion that this was a suitable treatment modality.<sup>2</sup> Their use in orthodontics continues to increase.

Mini-implants are now used for short- and long-term prosthodontic treatment; narrower-diameter mini-implants (up to 2.4 mm) are indicated for long-term use for complete and partial removable denture stabilization and for fixation of fixed prostheses (bridges). Wider-diameter mini-implants (2.9 mm) are indicated for denture stabilization in cases where softer bone is present as well as for single crowns. There are two primary anatomical reasons why a mini-implant would be used rather than a narrow- or standard-diameter implant: these are lack of space and insufficient bone. To these, a third rationale may be added – that of reduced invasiveness. The use of mini-implants enables placement of implants in areas where there is insufficient bone present for implants with a greater diameter (without bone grafting or other procedures). Mini-implants are available with tapered, fluted tips that aid advancement of the mini-implant into cancellous bone during finger and wrench tightening. As with some standard implant designs, roughened surfaces are created using grit-blasting and acid-etching to increase the surface area for osseointegration.

Mini-implants may be the only available solution for a single implant-supported crown in cases where there is insufficient bone interdently or bucco-lingually (or buccopalatally), a thin alveolar crest, or insufficient space between adjacent teeth, and where teeth have narrow cervical diameters.<sup>3,4</sup> Where insufficient bone is available, other solutions would include either a fixed prosthesis to replace the missing tooth or an adjunctive procedure involving bone grafting to first increase the availability of bone for the osteotomy site for a standard-diameter implant. Where insufficient space is available, either a fixed prosthesis would be indicated or pretreatment orthodontics would be required to create more space. Neither offers a quick or inexpensive solution, and bone grafting is an invasive procedure. In comparison, the use of mini-implants in these situations offers a solution that is relatively less costly and much quicker, does not involve extra steps, does not involve adjacent teeth, is less invasive,

and has now been shown to offer high success rates with good case selection. Mini-implants have been found to be successful in these situations. One case study report in 2004 of 32 mini-implants used for these reasons to restore single crowns found this to be a successful treatment option.<sup>5</sup> An early five-year retrospective study of mini-implants for single crowns was conducted by Vigolo and Givani. Forty-four patients received 52 mini-implants between 1992 and 1994 for subsequent restoration with single crowns. It was concluded from the study that the results were similar to those achieved with standard-diameter implants, and that this was a “suitable treatment alternative to solve both functional and esthetic problems.” The implant survival rate was 94.2%.<sup>6</sup> It has been recommended that in posterior sites, narrow rounded crowns be provided that minimize axial and off-axial forces and reduce loading to help reduce the risk of metal fatigue. This recommendation has also been made for fixed prostheses.<sup>7</sup> Although not a mainstream use, mini-implants have been utilized to help stabilize fixed prostheses where potential retention of the bridge was suboptimal. In these situations, a mini-implant has been placed under the pontic area to support and retain the pontic. This can be performed retroactively to help lengthen the service of a fixed prosthesis that has loosened from one of the abutments, by removing the bridge, placing the mini-implant, and recementing and securing the bridge back in position.<sup>8</sup>

Implant-retained partial removable dentures can be provided using mini-implants as well as standard-diameter (and wide/narrow-diameter) implants. In the case of partial removable dentures, adequate retention and function can often be achieved with the remaining alveolar ridge as well as by utilizing the remaining dentition as retainers (with or without the use of precision attachments). Distal extensions and anterior extensions in partial dentures are prone to rocking in function, which if sufficient bone is present can be solved through the placement of mini-implants on which the extension area of the dentures rests with use of precision attachments, O-rings or a soft reline material.<sup>8</sup> However, the primary focus of this article with respect to mini-implants is on their main use – providing stable, retentive overdentures for edentulous patients.

### Edentulous arches and complete removable dentures

In patients with edentulous arches, the ability to speak, masticate and smile is all dependent on an accurately fitting and well-retained denture. It has been said that “a patient with no eyes cannot see and a patient with no legs cannot run, yet a patient with no teeth expects to eat and act with dentures as with natural teeth.”<sup>9</sup> The provision of complete removable dentures that satisfy all functional and esthetic requirements is one of the challenges in dentistry. At the same time, despite overall improvements in the oral health of the population, the demand for complete removable dentures will continue as the elderly population increases. Over

the last thirty years, it has been estimated that edentulism in the population has decreased approximately 10% per decade. On the other hand, the number of people over 55 years of age – the most edentulous age group – will increase by 79% between 1990 and 2020. In the two decades following 1991, the number of complete denture patients requiring up to 2 dentures will increase from 33.6 million to almost 38 million.<sup>10</sup> These statistics underscore the importance of continuing to provide dental students with education on the provision of complete dentures as well as the necessity to acquire and retain the expertise that will continue to be needed to provide patients with functional and esthetic complete removable dentures. A number of anatomical and physiological challenges complicate treatment and the wearing of dentures and can result in patient dissatisfaction.

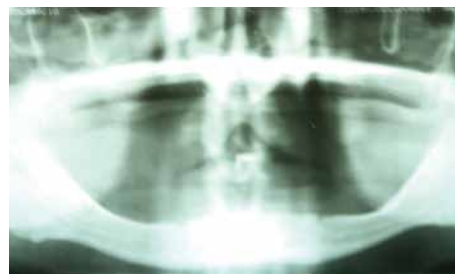
### Clinical challenges in edentulous patients

Edentulous arches undergo ongoing bone resorption from the time teeth are extracted until the time the patient dies. The degree of resorption varies from patient to patient – in some cases sufficient residual arch remains to aid retention and function (particularly in the early years following extractions, if advanced periodontal destruction had not occurred); in other cases, over time little residual arch remains. Such atrophy is typically more severe in the mandible than the maxilla. (Figures 1-3) Along with resorption comes a lack of retention and compromised function of complete dentures. A chronically loose denture can create an epulis fissuratum – a mucosal hyperplasia that results from chronic low-grade trauma induced by a loose denture. (Figure 4) Although painless, if this is present clinically it is evidence of a loose, ill-fitting denture.

Figure 1. Residual maxillary arch-form

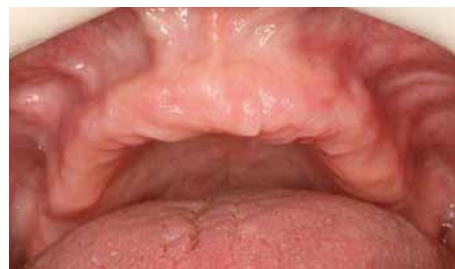

Figure 2. Panorax of atrophic mandible



Note mental nerves at the surface of the bone, making denture wearing painful

Figure 3. Residual mandibular arch with atrophy

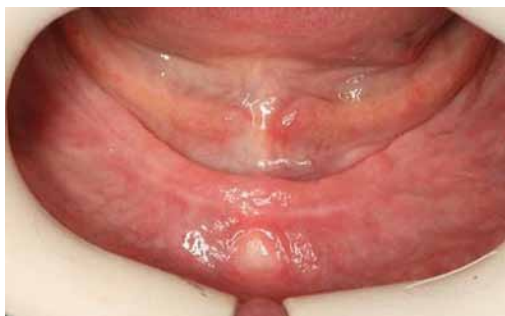
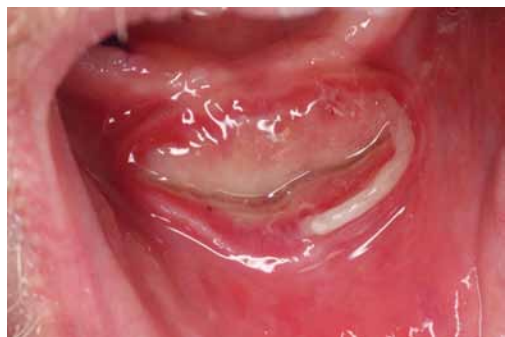
Figure 4. Mucosal hyperplasia associated with loose overextended denture on the mandible



In addition to arch-form, saliva also factors into the functioning of complete removable dentures. Excess saliva (ptyalism) can result in gagging. If saliva is thick and ropy, it will accumulate under the denture and result in a loss of retention, while thin and watery saliva also compromises the function of dentures. A lack of or inadequate amount of saliva reduces suction (and therefore retention) of the denture. The high prevalence of xerostomia in older adults<sup>11</sup> therefore complicates the clinical challenges faced. Research conducted on edentulous patients who either had no dentures or had ill-fitting dentures that they could not wear has highlighted a link between these factors and overall physical and mental health. One six-year study in Japan led to the conclusion that institutionalized edentulous patients deteriorated more physically than dentate patients (with at least 20 teeth) and had a significantly higher six-year mortality rate.<sup>12</sup> All these challenges highlight the importance of good complete denture design as well as the potential utility of implants and mini-implants in improving outcomes and patient satisfaction.

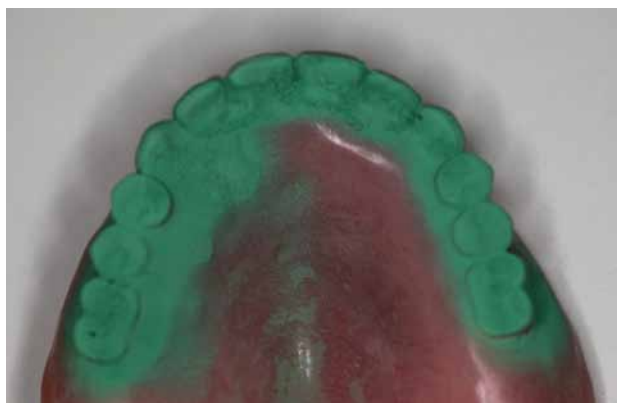
### Goals of complete denture fabrication

The overall objective of complete denture treatment is to fabricate dentures that reproduce the lost dentition as well as the supporting structures. When considering the replacement of missing teeth and supporting structures, three important goals have to be accomplished for the complete denture: support, stability and retention.<sup>13</sup> To these can be added a fourth goal, patient satisfaction.

### Support, stability and retention

The fundamental philosophies governing the biomechanics of complete dentures state that there is a fine interrelationship between support, retention and stability, and the success of the prosthesis will be dependent in a very large part on these features. Support refers to how well the tissues keep the denture from moving in a vertical direction and from depressing the tissue, which would result in discomfort. Stability is related to how resistant the denture is to side-to-side movement – if the ridges are atrophied and flat then stability is compromised. Stability also relies on the occlusion being correct, with no premature contacts that would induce movement of the denture. (Figure 5)

Figure 5. Denture with premature contact on the patient's right side (tooth #3)



Retention refers to how well the denture remains in place – i.e., it does not drop from the maxillary arch and does not lift up from the mandibular arch. This relies on the ridge anatomy and also on an impression that accurately captures the morphology of the patient's tissues for accurate model reproduction for denture fabrication. (Table 1)

Table 1. Anatomical details and border extensions

Maxillary Impression
Canine eminence
Coronoid process
Incisive papilla
Frenum attachments
Hamular notches
Tuberosity
Posterior palatal seal area and vibrating line
Mandibular Impression
Buccal shelf
Mylohyoid ridge
Genial tubercles
Frenum attachments
Retromolar pads

Retention will be significantly better if the denture is well-adapted to the underlying and adjacent tissues, while adequate and accurate border extensions of the dentures are also essential for retention and stability.<sup>14</sup> (Figures 6-8) In the case of a maxillary complete denture, the post dam is key for retention; if an upper complete denture drops when pressure is applied to the incisal edges of teeth, the post dam will need to be evaluated. Assessing the vibrating line is also key.

Figure 6. Dentures with and without adequate border extensions (same patient)

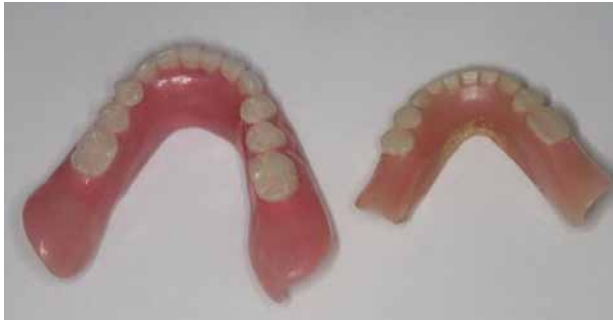
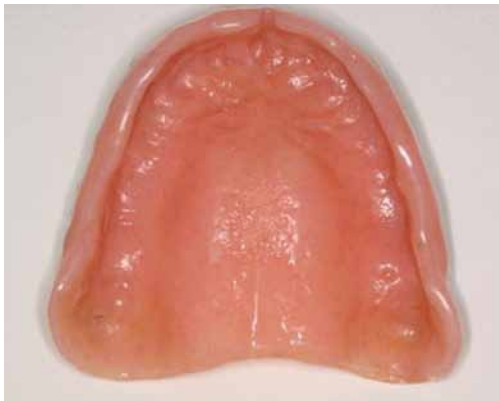
Figure 7. Maxillary denture without proper extension to include the hamular notches



Note the insufficient borders, the hamular notches not being included.

Figure 8. Lower impression with adequate extensions and capturing of all anatomical details

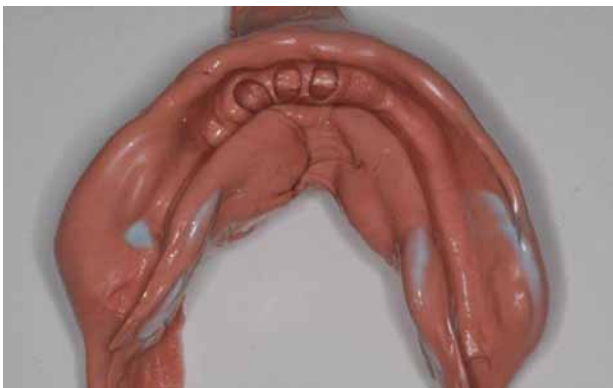
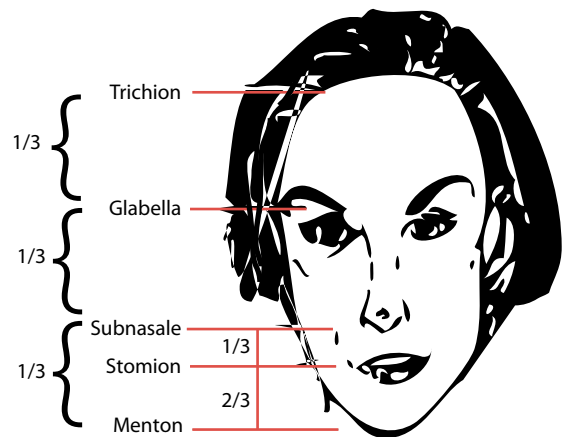


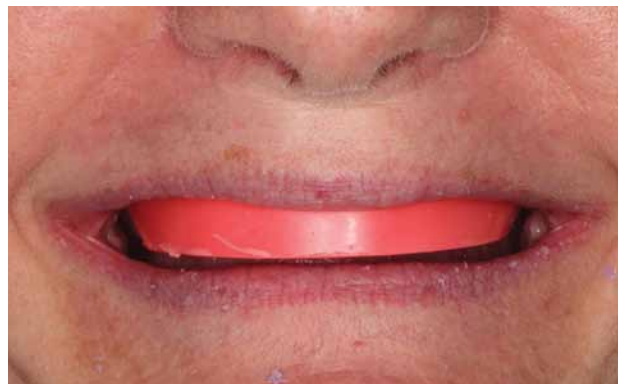Figure 9. Golden proportion



### Vertical dimension

The vertical dimension is the distance between the mandible and maxilla when the opposing teeth are in contact.<sup>15</sup> The clinical rest position is highly variable and can be influenced by a number of factors, including cranial-cervical position, the presence or absence of dentures,<sup>16</sup> speech,<sup>17</sup> and stress.<sup>18</sup> The term “rest position” is also somewhat of a misnomer, since the jaw muscles in this position do not necessarily display their lowest amount of electromyographic (EMG) activity.<sup>19</sup> This rest, or postural, position is generally in the range of 2 mm to 4 mm relative to the intercuspal position.<sup>20</sup> The vertical dimension is related to the amount of force that can be applied and therefore the ability to chew. Vertical dimension can be measured using many techniques, including phonetics, swallowing, using the patient’s hand, the golden proportion and the facial appearance.<sup>21</sup> (Figure 9) One study in 50-to-65-year-olds found that maximum bite force was obtained using the facial appearance method;<sup>22</sup> this assesses the position of the lips, how much vermilion border of the lip shows, the commissure of lips and crease of the upper lip. During denture fabrication, an Esthetic Control Base must be used to record the smile line and midline to provide the laboratory with information required to set up the anterior teeth. (Figure 10) The vertical dimension and bite relationships must also be measured and recorded.

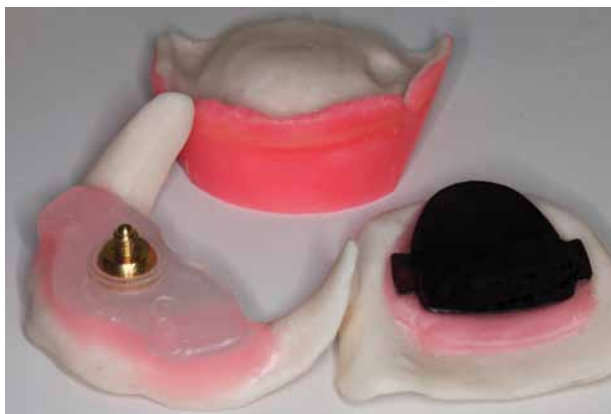Figure 10. Esthetic Control Base



### Occlusion and centric relation

Occlusion is key in governing denture stability. The denture occlusion that will be “ideal” for the patient is the one that will limit tilting of the dentures and thereby minimize disruption of the peripheral seal.<sup>23</sup> This occlusal prescription will take into account the patient’s denture-bearing tissues and chewing pattern, and will dictate which types of teeth should be used (anatomic/non-anatomic/zero-degree/cuspless) for new dentures. The proposed length and width for anterior teeth, and the plane of occlusion, can be determined by measuring the distance of the width of the nares opening – this has been found to be the same width as the four upper anterior teeth.<sup>24</sup> In turn, measuring the distance from the incisal papilla to the length of upper lip at rest guides selection of the length of the anterior teeth. In determining the occlusion that will be ideal, the centric relation must be measured as well as the protrusive and lateral excursions. These can be difficult to establish and to accurately transfer the information to the laboratory for mounting of casts in the articulator and the denture setup. The use of a Gothic arch tracer substantially simplifies this process and provides accurate readings for these measurements. Using the Gothic arch tracer, the stylus is mounted in the lower recording base and a flat plate is attached to the maxillary recording base and then coated with crayon, articulating paper or a permanent felt-tip marker. The recording bases are then returned to the mouth, and the patient is instructed to assume a retruded mandibular position, then a protrusive position sequentially and repeatedly. Next, the patient is instructed to carry his or her mandible into its most lateral movements to capture lateral excursions. These measured and observed tracings result in a clear understanding of where centric relation is, and the tracing is representative of the range of mandibular movement that can then be applied to denture and prostheses fabrication and equilibration.<sup>25-30</sup> (Figures 11-13) When analyzing existing dentures, the plane of occlusion must be assessed, and it must also be established for new dentures – this affects both function and esthetics. If the posterior aspect of a maxillary denture is

Figure 11. Gothic arch tracer and EC Base



hanging down, the plane of occlusion is incorrect. Holding the dentures in place, allowing the patient to gently close in habitual occlusion and asking him or her to stop at first contact makes it possible to observe any occlusal interferences. Checking the occlusion is easier with paint-on or spray-on articulating liquid than with articulating paper, as dentures move away from articulating paper.

Figure 12. Gothic arch tracings

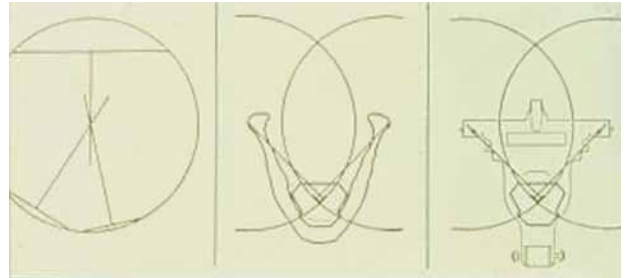
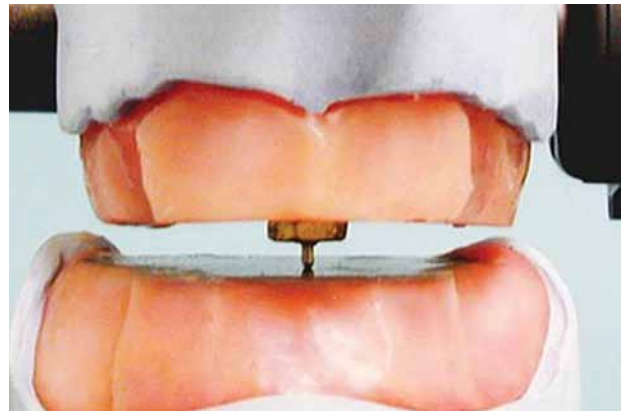

Figure 13. Tracer set up on the articulator parallel to the horizon



Although these techniques help to ensure that the goals of complete denture fabrication can be met, these goals cannot always be attained without adjunctive treatment such as implants or mini-implants. This in turn can also affect patient satisfaction.

### Patient satisfaction

Patient satisfaction ultimately depends on the treatment we provide meeting the needs and expectations of the patient. In the case of treatment with complete dentures, it is worth remembering that the denture patient has had many prior dental experiences, which ultimately culminated in the dentition being lost (both physically and emotionally detrimental). For patients with preexisting complete dentures, it is key to understand the patient’s level of satisfaction with the old dentures, the chief complaint and any other complaints regarding the denture. To satisfy these patients, the complaint(s) will have to be resolved and the dissatisfiers addressed during treatment. Also determine whether the patient arrived with a particular treatment in mind. The initial patient interview

is key in setting the stage for the proposed treatment and outcomes and is an opportunity for the patient to explain in his or her own words what he or she has come for and any complaints or problems. It is important to clearly understand what the patient wants and his or her understanding of the proposed treatment and outcomes. Equally important is a clear determination of the type of treatment the patient can tolerate, whether the patient will be satisfied with the end result or whether he or she has unrealistic expectations. The patient must also understand the options that are available and the advantages and disadvantages of each type of treatment, including ease and length of treatment and cost. A signed informed consent must be obtained from the patient prior to embarking on treatment.<sup>31</sup>

### Implant-retained overdentures

The use of overdentures together with implants presents an opportunity to improve denture retention and stability and to improve comfort for patients. Implant-retained overdentures have also been found to improve patient satisfaction and quality of life. A well-accepted protocol for implant-retained mandibular complete dentures is the provision of two standard diameter implants for the edentulous mandible. However, in many cases there is insufficient bone to support two standard diameter implants. In those instances, mini-implants can be an attractive solution. Numerous studies have assessed patient satisfaction with implant-retained mandibular overdentures compared to their satisfaction levels with prior complete dentures (i.e., without implants), finding higher satisfaction ratings with the implant-retained overdentures – one study measured this as 36% higher.<sup>32</sup> Patients have also reported improved ability to chew with implant-retained mandibular overdentures, as well as improved stability and comfort.<sup>32,33</sup> Oral health-related quality of life has been found to be significantly improved with the provision of implants for (mandibular) overdentures.<sup>34-37</sup> These results have been found in both middle-aged and elderly edentulous patients, both male and female. Different levels of patient satisfaction with dentures have also been observed in men versus women – female wearers are as satisfied as men with implant-retained overdentures, but not with complete dentures (i.e., without implants).<sup>38</sup> Implants offer us a way to give our patients a solution for these chronic problems. However, root-form implants have limitations related to cost, anatomical considerations, health of the patient and the dentist's technical ability. Many patients just cannot afford a multiple root-form implant-supported fixed lower denture. Mini-implants are no longer transitional but offer a solution to the problems of denture instability, lack of retention and denture-related discomfort, and therefore also a solution for the unsatisfied denture patient. Mini-implants are minimally invasive compared to wider-diameter implants and typically have a shorter healing period. The surgical procedure is less complex, quicker and less invasive, and

the insertion of the implants simpler.<sup>39</sup> They can be placed in as little as 90 minutes and immediately loaded and have also been found to be cost-effective.<sup>40</sup> Placement of mini-implants can be performed with or without a surgical flap.

### Mini-implant-retained overdentures

As with standard-diameter implants, patients receiving mini-implants for overdenture treatment have reported higher satisfaction rates, and high success rates have been obtained. One study involving placement of 116 mini-implants in 30 patients found a success rate of over 97%. Based on patient responses, denture retention, comfort, chewing ability and speaking ability all improved. It was concluded that “MDIs are a highly successful implant option” and that the implants are “relatively affordable and overall patient satisfaction is excellent.”<sup>41</sup> Another study with a follow-up period ranging from 5 months to 8 years found a success rate of more than 91%.<sup>39</sup> In another study, mini-implants were placed over a 5-year period in 531 patients, with a mean follow-up of 2.9 years; 2,514 mini-implants were placed, almost equally in the mandible and maxilla, and almost equal numbers of fixed and removable prostheses were provided to the patients (1,278 versus 1,236). The overall survival rate was 94.2%, and risk factors for failure of mini-implants were found to be atrophic bone, cigarette smoking, removable prostheses and placement in the posterior maxilla. The same researchers also concluded that there was a learning curve associated with the procedure.<sup>42</sup> A retrospective study, published in 2008 by Degidi et al., looked at 510 narrow-diameter implants ranging from 3.0 mm to 3.5 mm diameter placed in 237 patients over an 88-month period (November 1996 through February 2004), half of which were immediately restored (without loading). The survival rate was 99.4% and no implants fractured. The researchers concluded that the procedure is reliable.<sup>43</sup>

### Mini-implant overdenture attachments

Several designs of attachments are available for use with mini-implants under complete dentures. These include O-balls, O-rings, and the use of soft reline material. The “O-balls” are the head of the implant and part of its design, which coronally has a spherical area. Retention can then be obtained using a metal housing with a titanium nitride coating to improve wear resistance. This housing is built into the interior aspect of the dentures and retentively fits over the head (O-ball) of the implant. An alternative method involves the use of “O-rings” that are held in a generic metal cap that fits over the head of the implant. These O-rings can be swapped out as they wear and lose their retentive ability. A third method utilizes soft reline material in the area on the internal aspect of the denture that will contact and surround the head of the mini-implant, providing for a soft, gripping area around the implant. Other attachment designs are also available.<sup>44</sup>

## Treatment planning and overdenture treatment with mini-implants

When planning treatment for mini-implant overdentures, all standard steps for successful complete denture fabrication must be followed in sequence. These steps begin with the patient interview and clinical examination and end with follow-up. (Table 2)

Table 2. Treatment requirements

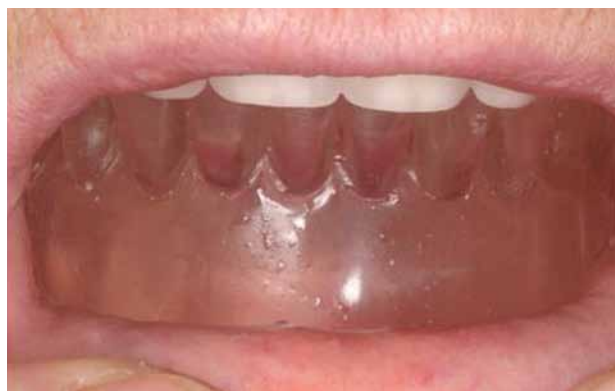Interview with the patient
Clinical examination
Agreement to treatment
Understanding the limitations of treatment
Reproduction of the tissue surfaces
Vertical dimension
The proper jaw relationship between the mandible and maxilla
The correct esthetic result in terms of shape and color of teeth
The proper occlusal scheme so the patient can chew
Try-in
Denture placement
Follow-up appointment(s)

The option of placing mini-implants should be discussed with the patient at the clinical examination, and agreement to this treatment ideally reached at the treatment-planning stage if it appears that these will be necessary for retention and stability of the denture(s). If the patient rejects this treatment option, and if after careful explanation of all options you clinically believe they would improve the outcome, it helps to use a clear stent at the try-in stage rather than pink-colored acrylic and teeth. (Figure 14) The patient will ask about the clear stent, and it is then possible to reintroduce the topic of mini-implants, explaining why these are advisable and that by using a clear stent at the try-in stage, it could also be used for mini-implant placement if the lower denture is not as stable or retentive as the patient would like and a decision is made later to place mini-implants. In the case of a patient for whom it is impossible to provide a stable, retentive denture without placing standard or mini-implants, and the patient rejects this while still expecting excellent retention and stability, it may be best to deselect this patient for denture treatment at your office rather than ending up with a very dissatisfied and problematic patient. Bruxers should be carefully evaluated as bruxism is a risk factor in mini-implant and implant cases. Selecting wider diameter implants, together with careful treatment planning, can help reduce the risk of implant fracture.

Nonretentive lower complete dentures over an atrophic mandibular arch can result in patients developing a

vertical-only chewing pattern without lateral excursions (“accommodative chomping”), in an attempt to prevent the denture from dislodging. If implants are then placed and the denture retrofitted, this chewing pattern can change over time to one that includes lateral and protrusive excursions. An unfortunate effect of this improved chewing pattern and lower denture retention is that the occlusion of the dentures may now result in a previously retentive maxillary denture being “tripped” by the lower denture such that it loosens.<sup>44</sup> Therefore, when retrofitting the denture, the occlusion must always be checked for this possibility. Patients should also be advised ahead of time that the upper denture may feel loose once the lower arch has been treated and, if so, that implants in the upper arch may also be required.<sup>45</sup>

Figure 14. Clear stent



## Mini-implants and the active treatment phase

Once it has been decided to place mini-implants, the type, diameter and their positioning must be carefully assessed and determined. Sites must be selected that offer adequate volume and quality of bone to ensure that the implants can be properly placed and will osseointegrate. During placement, either flapless surgery or surgery with a raised flap can be performed. Raising a flap to directly observe the amount of bone and proposed site for placement of implants may be advantageous to ensure accurate placement and angulation of implants. However, it has also been found that minimally invasive flapless surgery offers patients the possibility of high predictability of success for mini-implants, and flapless surgery is less traumatic for the patient. Proper diagnosis and treatment planning are key factors in achieving predictable outcomes.<sup>45</sup> Pretreatment assessment of bone is essential whether or not a flap is raised. In the case of mini-implants, these require less bone, and only a pilot hole is required. Drilling to the full length of an osteotomy site is not necessary as it typically is with narrow-, standard-, and wide-diameter implants. The cases below demonstrate the placement and use of mini-implants (MDI, 3M ESPE, formerly IMTEC) in the mandibular and maxillary arches using the flapless surgery technique.



### Case: Mini-implant placement for lower complete denture retention

The patient presented with upper and lower complete dentures. Her chief complaint was that the lower denture was unstable, moved around and at times was uncomfortable and painful to wear. She was satisfied with her upper complete denture. On examination it was determined that all oral soft tissues were healthy and that the upper denture was stable, well-retained and supported by an adequate maxillary ridge. The mandibular arch was atrophied with limited ability to retain the lower complete denture, which was unstable. (Figures 15-18)

Figure 15. Occlusal view of mandible

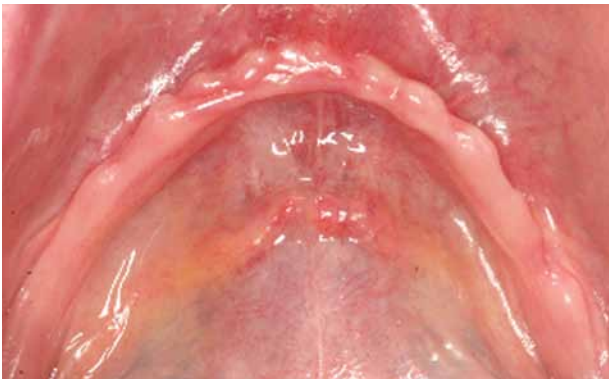


Figure 16. Lateral view of mandible

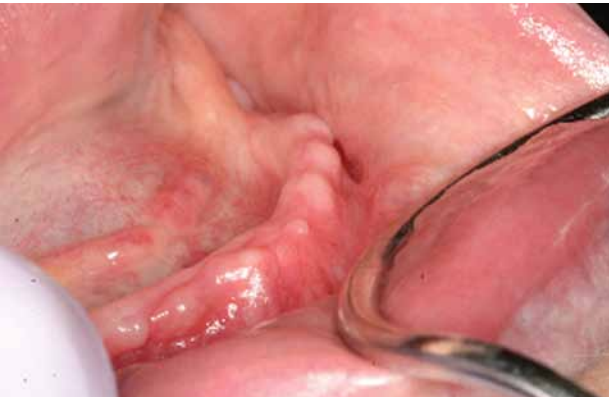

Figure 17. Existing denture, full view

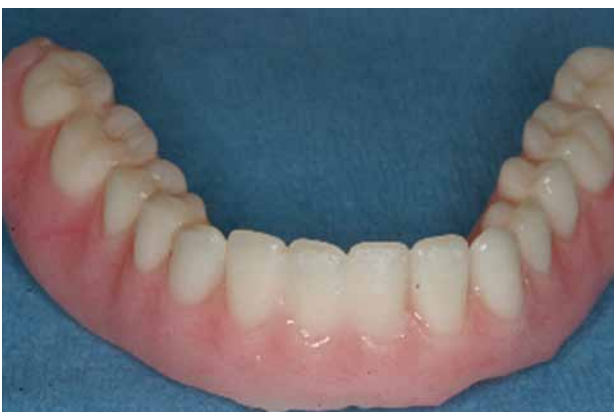
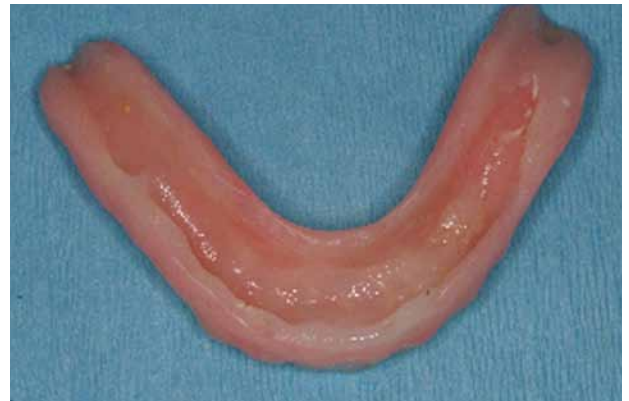
Figure 18. Existing denture, tissue side



In consultation with the patient and after exploring all options, it was determined that mini-implants should be placed to provide retention for the lower complete denture which was otherwise satisfactory. Panoramic radiographs were taken to fully assess and treatment plan for the mandibular arch, at which stage it was determined that four mini-implants would be placed at selected sites. At the mini-implant placement visit, the sites for placement were marked using a surgical pencil. These markings were then transferred to the denture by placing it over the mandible after the markings were made. (Figures 19-21)

Figure 19. Surgical marking pencil



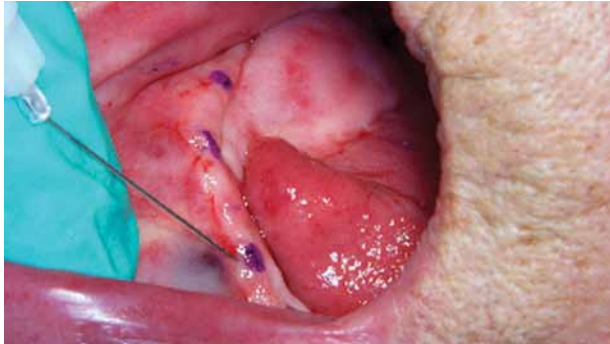
Figure 20. Markings on mandibular arch for mini-implant sites

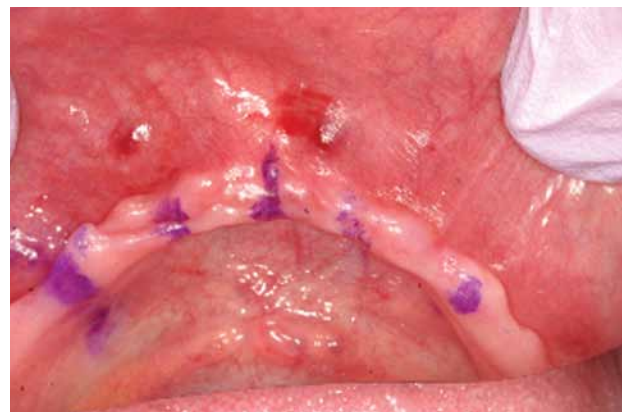

Figure 21. Markings transferred to denture

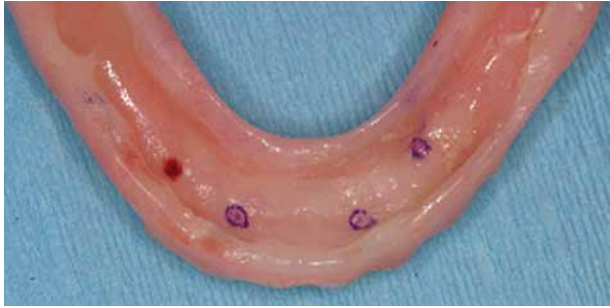

Figure 22. Stab mark with needle



Stab marks were made next at the marked sites, using a wide gauge disposable needle. A 1.1 mm pilot hole was then created at the first anterior osteotomy site using a single surgical bur to drill through the cortical plate, after which the implant (2.1 mm diameter) was inserted at the site and then slowly tightened with the matching thumb wrench until resistance was felt. As with all surgical procedures involving pilot drills, these should be used as directed to avoid drill fracture. This was followed by tightening with the winged wrench and the mini-implant was then fully seated using the matching ratchet wrench. Following the manufacturer's surgical protocol – using a sequential procedure with appropriate force – avoids compromising the implant. Note that no more than 2 mm of soft tissue should be left coronal to the cortical bone level. This was repeated with the contralateral anterior implant and the remaining two, until all four mini-implants (all 2.1 mm diameter) were in position. Note that they should be placed in parallel to each other – more than 15% divergence from parallel is undesirable. (Figures 22-29)

Figure 23. Drilling the pilot hole

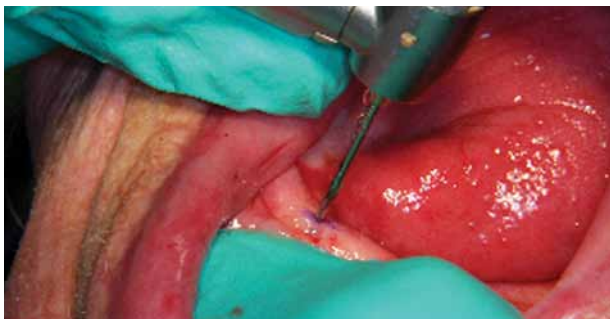

Figure 24. Placement of the implant

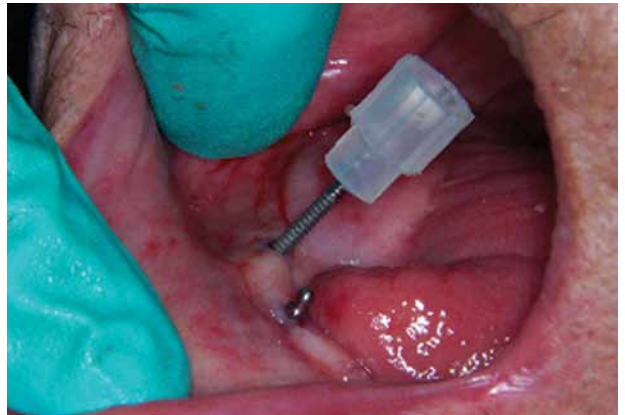

Figure 25. Finger-tightening of the implant

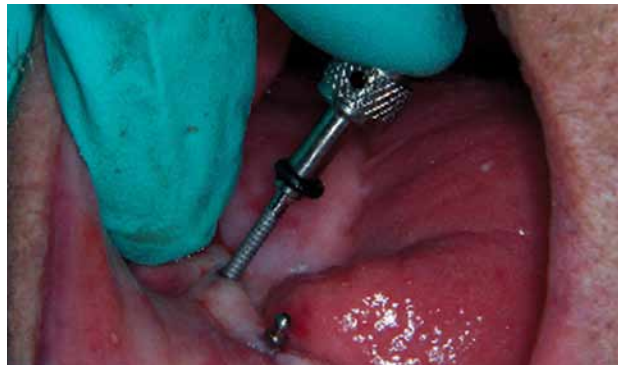

Figure 26. Use of winged wrench to tighten the implant

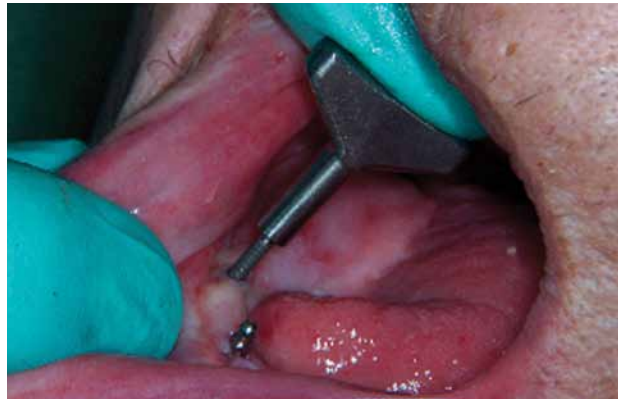

Figure 27. Anterior mini-implants placed

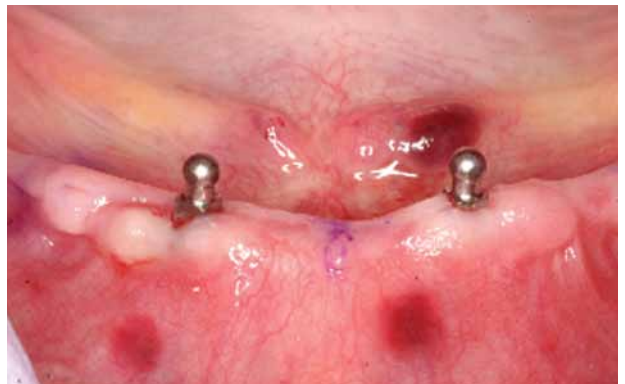

Figure 28. Oblique view, all four mini-implants placed

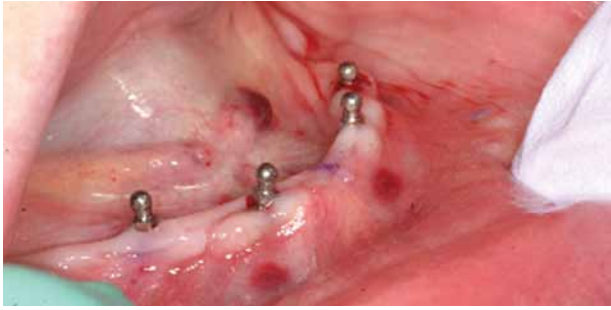
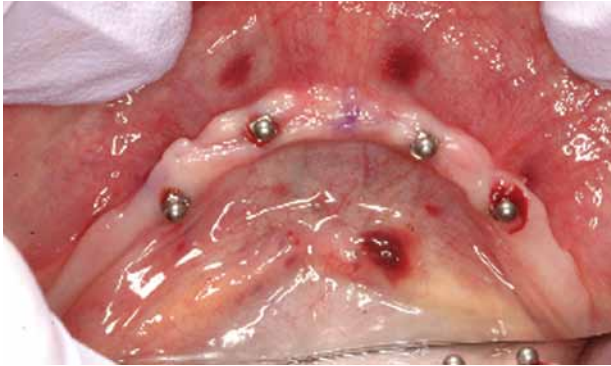

Figure 29. Occlusal view



### Retrofitting the denture

Following placement of the mini-implants, the metal housings were then placed over them. It was ensured during this process that the fit was passive with the metal housings tissue-borne and implant-retained. After the metal housings were placed, the area was checked to make sure no undercuts were present. This is critical, as any undercut must be blocked out to enable accurate pick-up and to ensure that no acrylic material would be able to seep under the housing to adhere to the implant head during retrofitting of the denture.

The next step was to relieve the denture where the marks had been transferred, to provide sufficient space for the metal housings and acrylic. Denture acrylic was then mixed and placed in the denture where it had been relieved and the denture placed over the metal housings and seated. After the acrylic had set, the denture was removed with the metal housings incorporated and the anterior border adjusted for comfort. (Figures 30-34) The existing denture was thus retrofitted with mini-implants and attachments chairside in one visit.

Figure 30. Metal housings placed over mini-implant heads

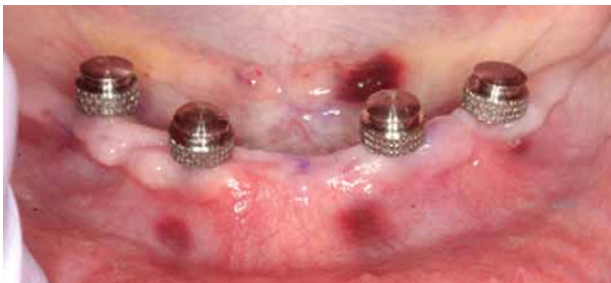

Figure 31. Denture relieved

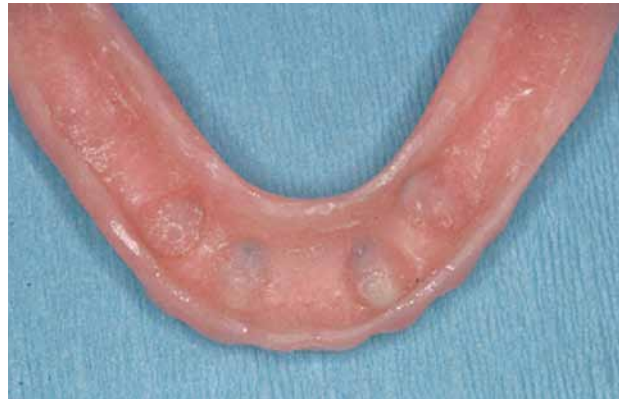

Figure 32. Mixed acrylic placed in relieved denture

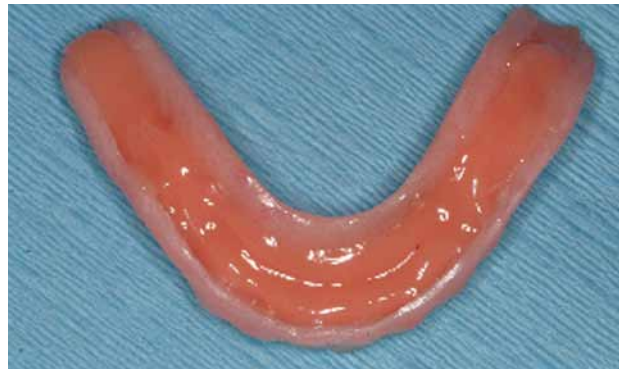

Figure 33. Denture with metal housings incorporated

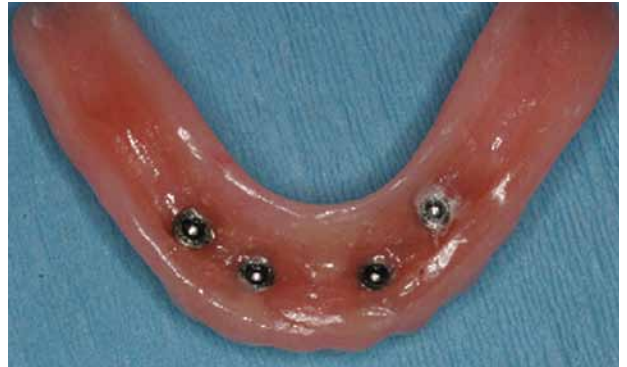
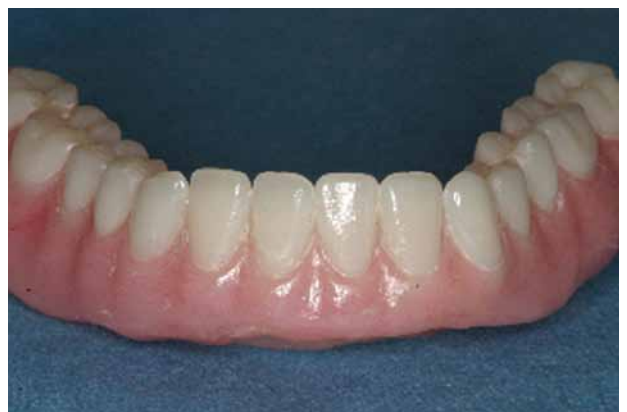
Figure 34. Complete lower denture with anterior border relieved



### Case: Mini-implant placement for upper complete denture retention

This patient presented with the lower anterior teeth present, no lower denture, and a complete upper denture. The patient's chief complaint was that the maxillary complete denture moved around during eating and was not stable. During clinical examination it was determined that all oral soft tissues were healthy and that the lower anterior region was functional. (Figure 35) It was also determined that the upper denture was well-fabricated and that, to improve on the stability and retention of an upper denture, the patient would need mini-implants for the upper denture and a lower removable partial denture. (Figure 36) After this was explained to the patient and compared with the implications and outcomes of other possible treatments, he accepted the proposed treatment.

Figure 35. Visual examination of the maxilla

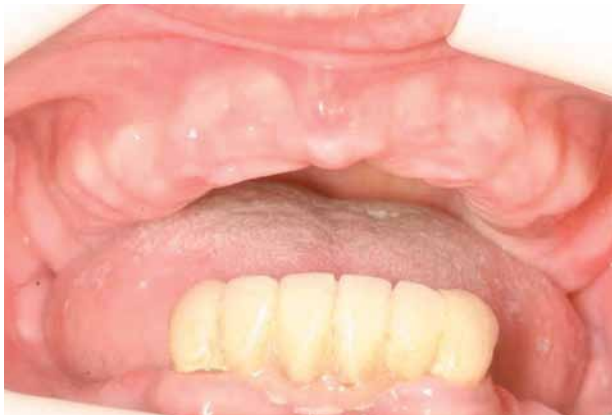
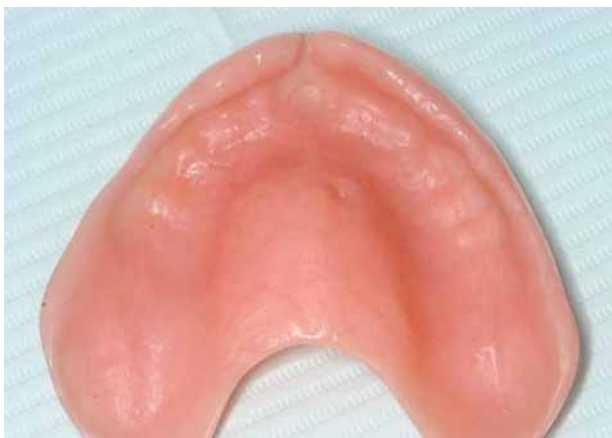
Figure 36. Well-fabricated existing maxillary denture



The sites for mini-implant placement were determined from the clinical examination and radiographs, and a denture-marking stick was used to plan the position of the mini-implants. The 1.1 mm pilot holes were then drilled through the cortical plate using a single surgical bur, and the mini-implants (2.4 mm diameter) were carried to the

sites and inserted into position. The mini-implants were slowly tightened with the matching thumb wrench until resistance was felt, followed by tightening with the winged wrench and were then fully seated using the matching ratchet wrench. (Figures 37-43)

Figure 37. Use of a denture-marking stick to plan mini-implant positions, noting implant positions across from each other

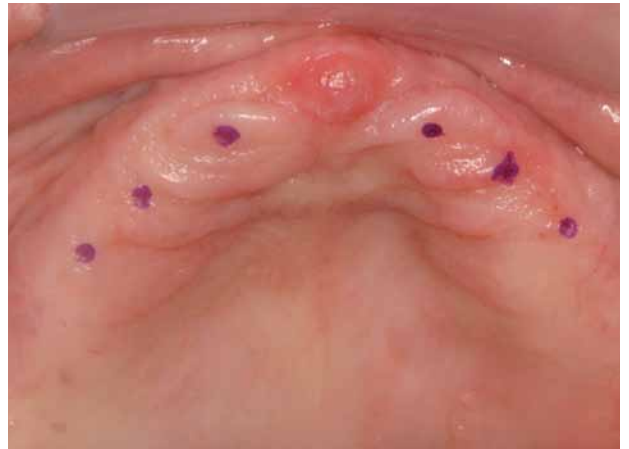

Figure 38. Drilling of the pilot holes

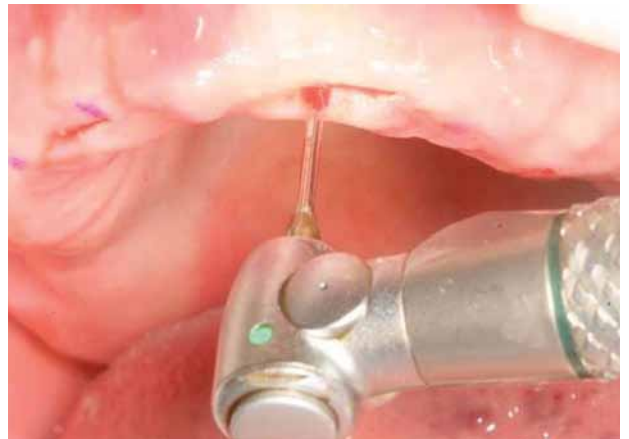

Figure 39. Placement of one of the mini-implants

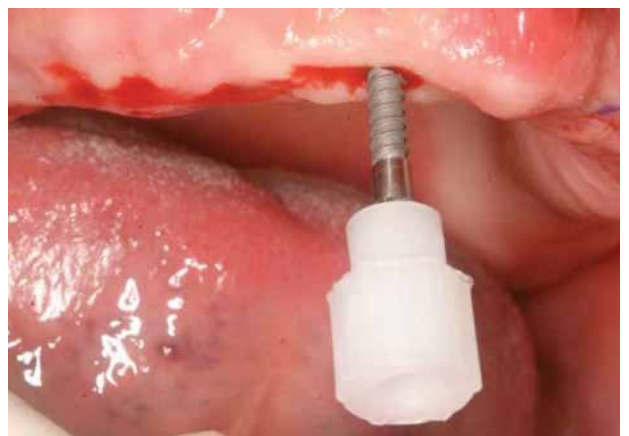

Figure 40. Finger tightening the mini-implant with the thumb wrench

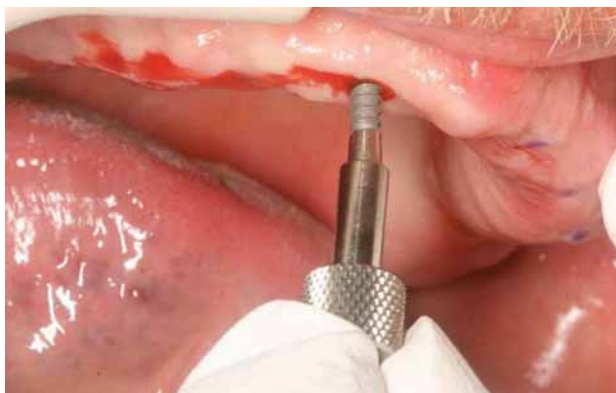

Figure 41. Finger tightening the mini-implant with the winged wrench

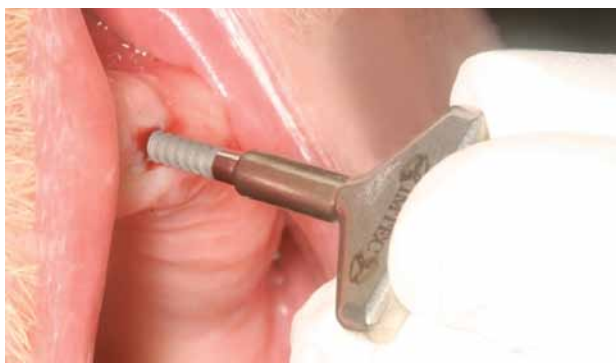

Figure 42. Fully seating the mini-implant using the ratchet wrench

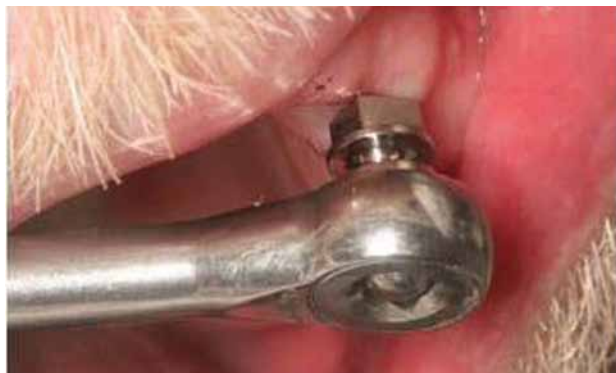
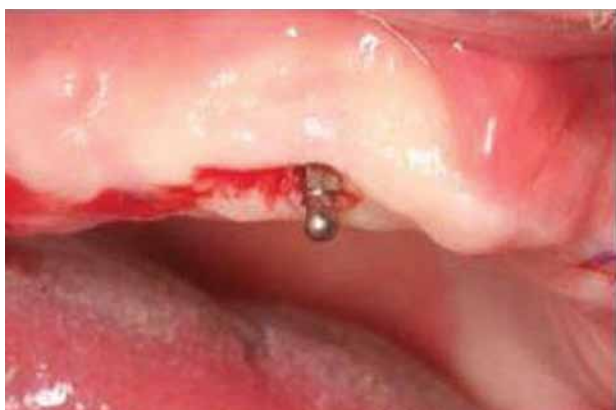
Figure 43. Mini-implant fully seated



### Retrofitting the denture

Following placement of all mini-implants in this manner while ensuring that they were parallel with each other, the metal housings were placed over the heads of the mini-implants. The junctions between the implants and the metal housings were checked to see if the seals were complete. If there is an area that has an incomplete seal, an undercut will be present that must be blocked out (using a shim block) to enable accurate information for the pick-up material (in effect, the impression material). This step is to avoid the denture being inadvertently retained over the implants once the pick-up material has set (see the following step). The metal housings were also exposed through the denture to make sure that they were in a passive position when the patient bit down hard or clenched in occlusion. The next stage was to retrofit the denture by placing soft pick-up material on the internal aspects of the denture where space was created for this material at sites corresponding to the mini-implant positions. The denture was then carefully inserted over the mini-implants, the pick-up material allowed to set and the denture removed with the metal housings now incorporated into the denture. (Figures 44-48)

Figure 44. Mini-implants placed with metal housings in position

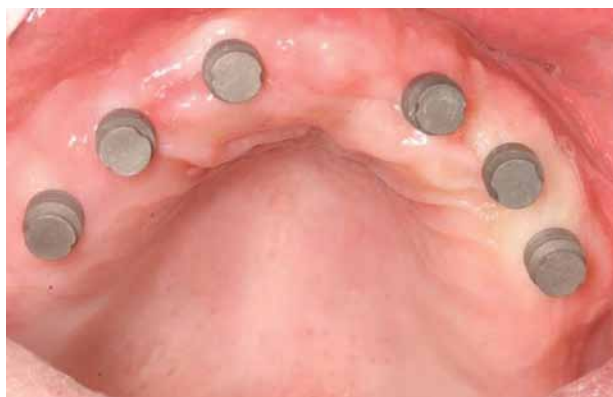

Figure 45. Sites marked for acrylic removal to create space for pick-up material

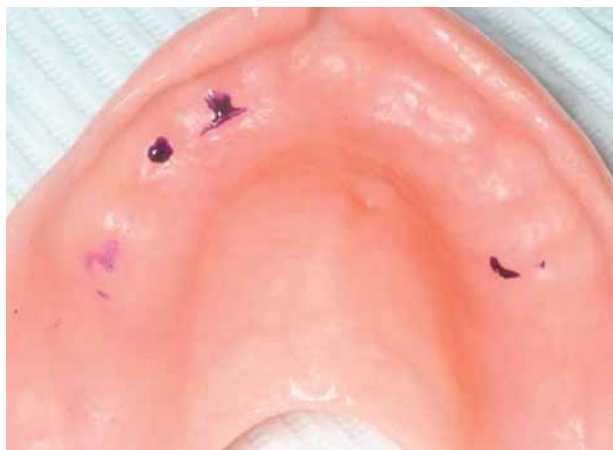

Figure 46. Use of shim block

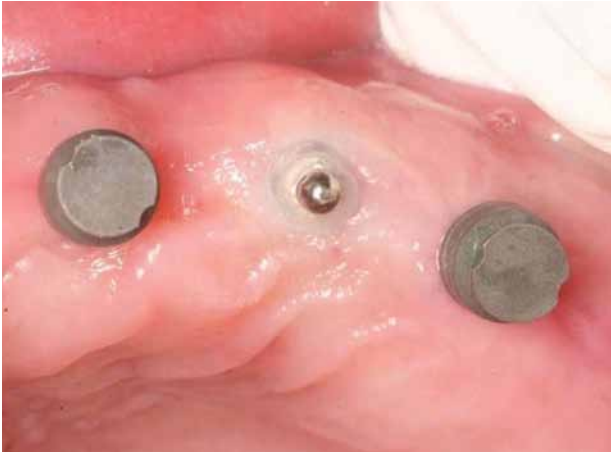

Figure 47. Metal housings exposed through the denture

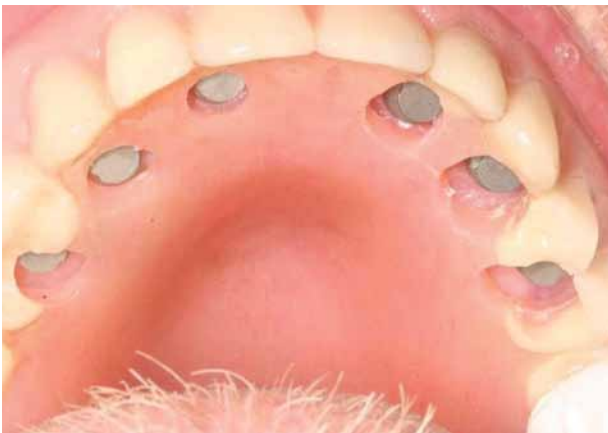
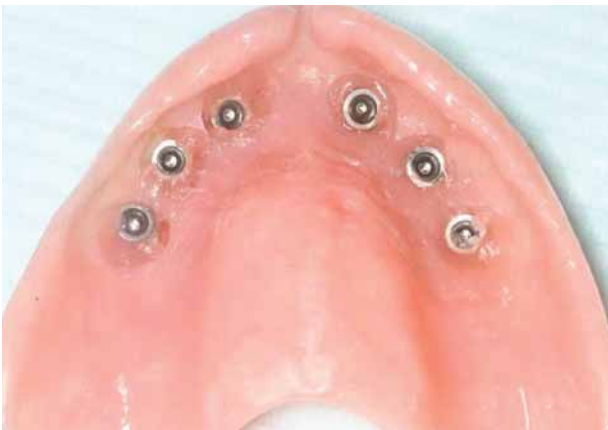
Figure 48. Internal aspect of the denture with the pick-up material and metal housings in position



Note that some pick-up material crept under the metal housings, underscoring the importance of blocking out undercuts.

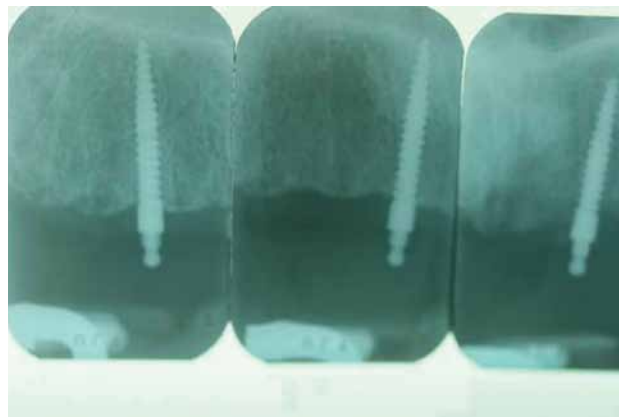
The patient was happy with the outcome and satisfied with the retention and stability of the retrofitted maxillary denture, as well as being happy with the newly fabricated

mandibular removable partial denture and his improved ability to chew. Six years post-treatment, the denture continues to serve the patient well and the mini-implants are osseointegrated with no loss of bone or soft tissue. (Figures 49,50)

Figure 49. Mini-implants in place after six years of function

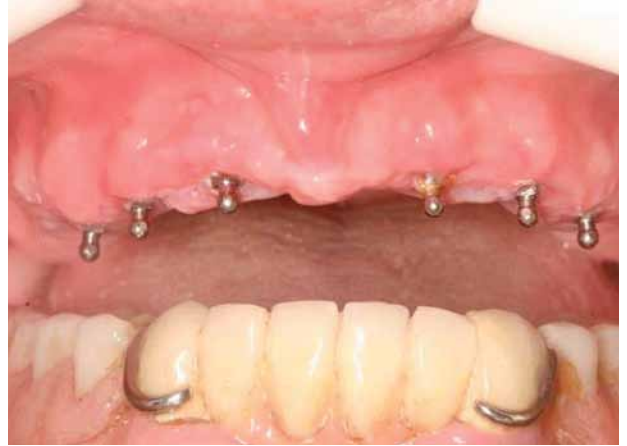

Figure 50. Radiographs of mini-implants after six years



### Summary

Implants of all diameters have improved options for providing patients with good treatment outcomes. This is certainly apparent in the case of complete dentures. Implants and mini-implants have been used and are indicated for single crowns, fixed prostheses, removable partial dentures and removable complete dentures. In the case of complete dentures, the use of mini-implants offers a less invasive treatment, requires little chairside time, is relatively inexpensive and results in significant improvements in complete denture stability and retention. Ultimately, it is the needs, desires and expectations of patients that matter. Implants and mini-implants have been found to not only improve denture functionality but also to result in improvements in patient satisfaction and overall outcomes.

## References

- 1 Christensen GJ. The 'mini'-implant has arrived. *J Am Dent Assoc.* 2006;137(3):387-90.
- 2 Reynders R, Ronchi L, Bipat S. Mini-implants in orthodontics: a systematic review of the literature. *Am J Orthod Dentofacial Orthop.* 2009 May;135(5):564.e1-19; discussion 564-5.
- 3 Degidi M, Piattelli A, Carinci F. Clinical outcome of narrow diameter implants: a retrospective study of 510 implants. *J Periodontol.* 2008 Jan;79(1):49-54.
- 4 Davarpanah M, Martinez H, Tecucianu JF, Celletti R, Lazzara R. Small-diameter implants: indications and contraindications. *J Esthet Dent.* 2000;12(4):186-94.
- 5 Mazor Z, Steigmann M, Leshem R, Peleg M. Mini-implants to reconstruct missing teeth in severe ridge deficiency and small interdental space: a 5-year case series. *Implant Dent.* 2004 Dec;13(4):336-41.
- 6 Vigolo P, Givani A. Clinical evaluation of single-tooth mini-implant restorations: a five-year retrospective study. *J Prosthet Dent.* 2000 Jul;84(1):50-4.
- 7 Flanagan D. Fixed partial dentures and crowns supported by very small diameter dental implants in compromised sites. *Implant Dent.* 2008 Jun;17(2):182-91.
- 8 Christensen GJ. The 'mini'-implant has arrived. *J Am Dent Assoc.* 2006;137(3):387-90.
- 9 Applebaum M. Plans of occlusion. *Dent Clin N America.* 1994;(28):273-6.
- 10 Douglass CW, Shih A, Ostry L. Will there be a need for complete dentures in the United States in 2020? *J Prosthet Dent.* 2002;87:5-8.
- 11 Managing xerostomia. *Vital* 6, 32–34 (1 March 2009) | doi:10.1038/vital944. Available at: <http://www.nature.com/vital/journal/v6/n2/full/vital944.html>
- 12 Shimazaki Y, Soh I, Saito T, Yamashita Y, Koga T, Miyazaki H, Takehara T. Influence of dentition status on physical disability, mental impairment, and mortality in institutionalized elderly people. *J Dent Res.* 2001 Jan;80(1):340-5.
- 13 Chetan Y. Textbook of Prosthodontics, 10.04.2010 Nallaswamy Syllabus of Complete Dentures.
- 14 Moses CH. Physical considerations in impression making. *J Prosthet Dent.* 1953;3:449-63.
- 15 Molligoda MA, Abuzar M, Berry DC. Measuring diurnal variation in the dispersion of occlusal contacts. *J Prosthet Dent.* 1988;60:235-8.
- 16 Gattozzi JG, Nichol BR, Somes GW, Ellinger CW. Variations in mandibular rest positions with and without dentures in place. *J Prosthet Dent.* 1976;36:159.
- 17 Pound E. Controlling anomalies of vertical dimension and speech. *J Prosthet Dent.* 1976;36:124.
- 18 Rugh JD, Johnson RW. Vertical dimension discrepancies and masticatory pain/dysfunction. In: Solberg WK, Clark G (eds). *Abnormal Jaw Mechanics.* Chicago: Quintessence, 1984:117-33.
- 19 Rugh JD, Drago CJ. Vertical dimension: A study of clinical rest position and jaw muscle activity. *J Prosthet Dent.* 1981;45:670-5.
- 20 Okeson JP. *Management of Temporomandibular Disorders and Occlusion*, ed 4. St. Louis: Mosby, 1998:98-101.
- 21 Pleasure, ME. Correct vertical dimension and freeway space. *J Am Dent Assoc.* 1951;43:160-3.
- 22 Bashir HJ, El Mahdy MM, El Masry SM. Evaluation of different occlusal vertical dimension recording techniques as regard to biting force in complete denture wearers (in vivo comparative study). *Egypt Dental J.* 2010;56 (3,1):
- 23 Davies SJ, Gray RM, McCord JF. Good occlusal practice in removable prosthodontics. *Brit Den J.* 2001;191:491-502.
- 24 Frush JP, Fisher RD. *J Pros Dent.* 1959;9(6):914-21.
- 25 Wojdyla SM, Wiederhold DM. Using intraoral gothic arch tracing to balance full dentures and determine centric relation and occlusal vertical dimension. *Clinical Insights. Deutch Dental Arts,* [www.deutschdentalarts.com](http://www.deutschdentalarts.com) 623 236 5249.
- 26 Patent 5722828 issued on March 3, 1998. Method of fabricating a dental bite registration mold using a gothic arch tracing.
- 27 El-Gheriani AS, Winstanley RB. The value of the gothic arch tracing in the positioning of denture teeth. *J Oral Rehabil.* 1988;15:367-71.
- 28 Halperin AR, King RE. Fabrication of a maxillary complete denture utilizing the neuromuscular or centric occlusion position. *J Am Dent Assoc.* 1980;100:67-70.
- 29 Goldfogel MH, Harvey WL. Fixed partial dentures: the use of a gothic arch tracer for jaw relations. *Gerodontics.* 1986;2:228-33.
- 30 Massad JJ, Connelly ME, Rudd KD, Cagna DR.

- Occlusal device for diagnostic evaluation of maxillomandibular relationships in edentulous patients: a clinical technique. *J Prosthet Dent.* 2004;91:586-90.
- 31 American Medical Association Physician Resources, Patient Physician Relationship Topics: Informed Consent. [www.ama-assn.org/ama/pub/physician-resources/legal-topics/patient-physician-relationship-topics/informed-consent.shtml](http://www.ama-assn.org/ama/pub/physician-resources/legal-topics/patient-physician-relationship-topics/informed-consent.shtml)
  - 32 Thomason JM, Lund JP, Chehade A, Feine JS. Patient satisfaction with mandibular implant overdentures and conventional dentures 6 months after delivery. *Int J Prosthodont.* 2003 Sep-Oct;16(5):467-73.
  - 33 Awad MA, Lund JP, Dufresne E, Feine JS. Comparing the efficacy of mandibular implant-retained overdentures and conventional dentures among middle-aged edentulous patients: satisfaction and functional assessment. *Int J Prosthodont.* 2003 Mar-Apr;16(2):117-22.
  - 34 Heydecke G, Locker D, Awad MA, Lund JP, Feine JS. Oral and general health-related quality of life with conventional and implant dentures. *Community Dent Oral Epidemiol.* 2003 Jun;31(3):161-8.
  - 35 Geckili O, Bilhan H, Bilgin T. Impact of mandibular two-implant retained overdentures on life quality in a group of elderly Turkish edentulous patients. *Arch Gerontol Geriatr.* 2010 December 21. Epub ahead of publication.
  - 36 Awad MA, Lund JP, Shapiro SH, Locker D, Klemetti E, Chehade A, et al. Oral health status and treatment satisfaction with mandibular implant overdentures and conventional dentures: a randomized clinical trial in a senior population. *Int J Prosthodont.* 2003 Jul-Aug;16(4):390-6.
  - 37 Turkyilmaz I, Company AM, McGlumphy EA. Should edentulous patients be constrained to removable complete dentures? The use of dental implants to improve the quality of life for edentulous patients. *Gerodontology.* 2010 Mar;27(1):3-10. Epub 2009 Mar 8.
  - 38 Pan S, Awad M, Thomason JM, Dufresne E, Kobayashi T, Kimoto S, et al. Sex differences in denture satisfaction. *J Dent.* 2008 May;36(5):301-8. Epub 2008 Apr 3.
  - 39 Bulard RA, Vance JB. Multi-clinic evaluation using mini-dental implants for long-term denture stabilization: A preliminary biometric evaluation. *Compend Contin Educ Dent.* 2005 Dec;26(12):892-7.
  - 40 Ahn MR, An KM, Choi JH, Sohn DS. Immediate loading with mini dental implants in the fully edentulous mandible. *Implant Dent.* 2004 Dec;13(4):367-72.
  - 41 Griffiths TM, Collins CP, Collins PC. Mini dental implants: an adjunct for retention, stability, and comfort for the edentulous patient. *Oral Surg Oral Med Oral Pathol Oral Radiol Endod.* 2005 Nov;100(5):e81-4.
  - 42 Shatkin TE, Shatkin S, Oppenheimer BD, Oppenheimer AJ. Mini dental implants for long-term fixed and removable prosthetics: a retrospective analysis of 2514 implants placed over a five-year period. *Compend Contin Educ Dent.* 2007 Feb;28(2):92-9; quiz 100-1.
  - 43 Degidi M, Piattelli A, Carinci F. Clinical outcome of narrow diameter implants: a retrospective study of 510 implants. *J Periodontol.* 2008 Jan;79(1):49-54.
  - 44 Christensen GJ. The increased use of small-diameter implants. *J Am Dent Assoc.* 2009;140(6):709-12.
  - 45 Becker W, Goldstein M, Becker BE, Sennerby L, Kois D, Hujuel P. Minimally invasive flapless implant placement: follow-up results from a multicenter study. *J Periodontol.* 2009 Feb;80(2):347-52.

### Author Profile



#### Jeffrey C. Hoos, DMD

Dr. Hoos is a highly respected, world renowned dental practitioner. He has invented many successful techniques to improve the quality of life for his patients.

Dr. Hoos graduated from Tufts University School of Dental Medicine with a DMD degree after receiving his MS degree in Biology from the University of Bridgeport and his BA degree in Zoology from Drew University. Dr. Hoos is a Fellow of both the Academy of General Dentistry and the Academy of Implant Dentistry.

### Acknowledgment

With thanks to Benjamin D. Oppenheimer, DDS for the mandibular case shown in this article.

### Disclaimer

The author(s) of this course has/have no commercial ties with the sponsors or the providers of the unrestricted educational grant for this course.

### Reader Feedback

We encourage your comments on this or any PennWell course. For your convenience, an online feedback form is available at [www.ineedce.com](http://www.ineedce.com).



## Online Completion

Use this page to review the questions and answers. Return to [www.ineedce.com](http://www.ineedce.com) and sign in. If you have not previously purchased the program select it from the "Online Courses" listing and complete the online purchase. Once purchased the exam will be added to your Archives page where a Take Exam link will be provided. Click on the "Take Exam" link, complete all the program questions and submit your answers. An immediate grade report will be provided and upon receiving a passing grade your "Verification Form" will be provided immediately for viewing and/or printing. Verification Forms can be viewed and/or printed anytime in the future by returning to the site, sign in and return to your Archives Page.

## Questions

- The first implant diameters to be introduced were the standard-diameter implants – typically around \_\_\_\_\_.
  - 2.75 mm
  - 3.25 mm
  - 3.75 mm
  - 4.25 mm
- The diameter of mini-implants typically ranges from \_\_\_\_\_.
  - 2.8 mm to 2.6 mm
  - 2.8 mm to 2.9 mm
  - 1.8 mm to 2.6 mm
  - 1.8 mm to 2.9 mm
- Root-form dental implants are utilized for implant-retained \_\_\_\_\_.
  - crowns
  - fixed prostheses
  - overdentures
  - all of the above
- Mini-implants were cleared by the FDA for long-term use in \_\_\_\_\_.
  - 1977
  - 1987
  - 1997
  - 2007
- In orthodontics, mini-implants are used \_\_\_\_\_.
  - to enable more rapid tooth movements
  - as temporary anchorage devices
  - to enable more complex tooth movements
  - all of the above
- \_\_\_\_\_ mini-implants are indicated for denture stabilization in cases where softer bone is present as well as for single crowns.
  - Narrower-diameter
  - Longer-diameter
  - Wider-diameter
  - all of the above
- \_\_\_\_\_ is a reason to place a mini-implant.
  - Lack of space
  - Insufficient bone
  - Reduced invasiveness
  - all of the above
- Mini-implants are available with \_\_\_\_\_ that aid advancement of the mini-implant into cancellous bone.
  - cylindrical tips
  - uni-width tapered tips
  - tapered, fluted tips
  - all of the above
- Mini-implants may be the only available solution for a single implant-supported crown in cases where there is \_\_\_\_\_.
  - insufficient bone interdentally or bucco-lingually
  - a thin alveolar crest
  - insufficient space between adjacent teeth or where teeth have narrow cervical diameters
  - all of the above
- An early five-year retrospective study of mini-implants for single crowns found a success rate of \_\_\_\_\_.
  - 87.2%
  - 91.3%
  - 94.2%
  - 97.1%
- In the two decades following 1991, the number of complete denture patients requiring up to 2 dentures will \_\_\_\_\_.
  - decrease
  - remain the same
  - increase
  - not matter
- An epulis fissuratum is a mucosal hyperplasia that results from chronic low-grade trauma induced by \_\_\_\_\_.
  - a loose denture
  - a too-tight denture
  - malignant transformation
  - none of the above
- \_\_\_\_\_ saliva can negatively affect denture function.
  - Thin and watery
  - Thick and ropery
  - A lack of
  - all of the above
- Bruxism is a risk factor for failure of \_\_\_\_\_.
  - mini-implants
  - standard implants
  - fluoride protection
  - a and b\*
- \_\_\_\_\_ is an important goal for the complete denture.
  - Support
  - Stability
  - Retention
  - all of the above
- Retention of a complete denture will be significantly better if the denture \_\_\_\_\_.
  - is well-adapted to the underlying and adjacent tissues
  - has adequate border extensions
  - has accurate border extensions
  - all of the above
- The vertical dimension is the distance between the mandible and maxilla when the opposing teeth are \_\_\_\_\_.
  - at least 5 mm apart
  - in contact
  - in protrusion
  - all of the above
- During denture fabrication, an Esthetic Control Base must be used to record the \_\_\_\_\_.
  - smile line
  - midline
  - bite relationship
  - a and b
- The denture occlusion that will be "ideal" for the patient is the one that will \_\_\_\_\_.
  - limit tilting of the dentures
  - limit manipulation of the dentures
  - minimize disruption of the peripheral seal
  - a and c
- In determining the occlusion that will be ideal, the \_\_\_\_\_ must be measured.
  - centric relation
  - lateral excursions
  - protrusive excursions
  - all of the above
- Using a Gothic arch tracer, the maxillary recording base is coated with \_\_\_\_\_.
  - crayon
  - articulating paper
  - a permanent felt-tip marker
  - any of the above
- The plane of occlusion \_\_\_\_\_.
  - must be established for new dentures
  - affects esthetics
  - affects function
  - all of the above
- The goals of complete denture fabrication cannot always be attained without adjunctive treatment such as \_\_\_\_\_.
  - implants
  - extra borders
  - mini-implants
  - a or c
- A signed informed consent must be obtained from the patient \_\_\_\_\_ treatment.
  - prior to embarking on
  - during
  - on completion of
  - any of the above
- Implant-retained overdentures have been found to improve \_\_\_\_\_.
  - patient satisfaction
  - quality of life
  - denture retention and stability
  - all of the above

## Questions

26. Mini-implants offer a solution to the problem of \_\_\_\_\_.  
a. denture instability  
b. lack of denture retention  
c. denture-related discomfort  
d. all of the above
27. One study involving placement of 116 mini-implants in 30 patients found a success rate of over \_\_\_\_\_.  
a. 93%  
b. 95%  
c. 97%  
d. 99%
28. 2,514 mini-implants placed almost equally in the mandible and maxilla were found to have an overall survival rate of \_\_\_\_\_.  
a. 92.2%  
b. 93.2%  
c. 94.2%  
d. none of the above
29. \_\_\_\_\_ was found to be a risk factor for failure of mini-implants in one study.  
a. Atrophic bone  
b. Cigarette smoking  
c. Placement in the posterior maxilla  
d. all of the above
30. \_\_\_\_\_ can be used as an overdenture attachment with mini-implants.  
a. An O-ball  
b. An O-ring  
c. Soft relin material  
d. all of the above
31. When planning treatment for mini-implant overdentures, \_\_\_\_\_ must be followed for successful complete denture fabrication.  
a. some of the standard steps  
b. all standard steps, in sequence,  
c. all standard steps, in a different sequence,  
d. any of the above
32. If it is impossible to provide a stable, retentive denture without placing standard or mini-implants, and the patient rejects this, it may be best to \_\_\_\_\_.  
a. place them anyway  
b. accept that the patient will still have overwhelming expectations  
c. deselect this patient for denture treatment  
d. a or c
33. \_\_\_\_\_ can help reduce the risk of implant fracture in bruxers.  
a. Selecting a wider diameter implant  
b. Careful treatment planning  
c. Smoking cessation  
d. a and b
34. "Accommodative chomping" is a result of a patient adapting his or her chewing pattern to \_\_\_\_\_.  
a. prevent the denture from dislodging  
b. prevent the denture from being swallowed  
c. prevent the denture from fracturing  
d. a and c
35. During placement of mini-implants, \_\_\_\_\_ can be performed.  
a. flapless surgery  
b. surgery with a raised flap  
c. surgery with a depressed flap  
d. a or b
36. Raising a flap to directly observe the amount of bone and proposed site for placement of implants may be advantageous to ensure \_\_\_\_\_.  
a. accurate placement of implants  
b. accurate angulation of implants  
c. sufficient hematogenous material is available for healing  
d. a and b
37. For mini-implants, flapless surgery \_\_\_\_\_.  
a. offers patients the possibility of high predictability of success  
b. is less traumatic for the patient  
c. treatment planning is still key  
d. all of the above
38. The sites for mini-implant placement can be determined from \_\_\_\_\_.  
a. the clinical examination  
b. the dental history  
c. radiographs  
d. a and c
39. No more than \_\_\_\_\_ of soft tissue should be left coronal to the cortical bone level when placing mini-implants.  
a. 1 mm  
b. 2 mm  
c. 3 mm  
d. 4 mm
40. When placing mini-implants, more than 15% divergence from parallel is \_\_\_\_\_.  
a. desirable  
b. undesirable  
c. necessary  
d. none of the above
41. When tightening an implant as shown in the case study, the \_\_\_\_\_ should be used before the \_\_\_\_\_.  
a. winged wrench; matching thumb wrench  
b. ratchet wrench; matching thumb wrench  
c. matching thumb wrench; winged wrench  
d. a or b
42. Metal housings placed over the O-balls of mini-implants \_\_\_\_\_.  
a. must fit passively  
b. must be tissue-borne  
c. must be implant-retained  
d. all of the above
43. If an undercut is present around a metal housing, this must be blocked out to \_\_\_\_\_.  
a. enable accurate information for the pick-up material  
b. prevent the pick-up material from entering through an incomplete seal into an undercut area  
c. to avoid the denture being inadvertently retained over the implants once the pick-up material has set  
d. all of the above
44. During complete denture fabrication with mini-implants, metal housings are exposed through the denture to make sure that they are in a passive position when the patient \_\_\_\_\_.  
a. bites down hard or clenches in occlusion  
b. is in a protrusive position  
c. is in lateral excursions  
d. all of the above
45. A shim block is used to \_\_\_\_\_.  
a. check the articulation of the denture during set-up  
b. check the occlusion intraorally  
c. block out undercuts around metal housings  
d. all of the above
46. Existing denture can be retrofitted with mini-implants and attachments chairside in just \_\_\_\_\_.  
a. one week  
b. one visit  
c. two visits  
d. none of the above
47. It is possible to prepare the surgical site for a mini-implant using \_\_\_\_\_.  
a. a single surgical bur  
b. a high-speed bur  
c. air abrasion  
d. a minimum of three surgical burs
48. A denture marking stick is used during the placement of mini-implants to mark \_\_\_\_\_.  
a. the outer aspect of the denture  
b. the mini-implant sites intraorally  
c. the occlusion  
d. none of the above
49. \_\_\_\_\_ osseointegrate.  
a. Implants  
b. Mini-implants  
c. Precision attachments  
d. a and b
50. Implants and mini-implants have been found to improve \_\_\_\_\_.  
a. denture functionality  
b. patient satisfaction  
c. overall outcomes  
d. all of the above

# An overview of mini-implants and their role in complete denture treatment

Name: \_\_\_\_\_ Title: \_\_\_\_\_ Specialty: \_\_\_\_\_  
 Address: \_\_\_\_\_ E-mail: \_\_\_\_\_  
 City: \_\_\_\_\_ State: \_\_\_\_\_ ZIP: \_\_\_\_\_ Country: \_\_\_\_\_  
 Telephone: Home ( ) \_\_\_\_\_ Office ( ) \_\_\_\_\_ Lic. Renewal Date: \_\_\_\_\_

Requirements for successful completion of the course and to obtain dental continuing education credits: 1) Read the entire course. 2) Complete all information above. 3) Complete answer sheets in either pen or pencil. 4) Mark only one answer for each question. 5) A score of 70% on this test will earn you 3 CE credits. 6) Complete the Course Evaluation below. 7) Make check payable to PennWell Corp. **For Questions Call 216.398.7822**

## Educational Objectives

- List and describe the indications for implants and mini-implants
- List and describe the clinical challenges that may be present in edentulous patients
- List and describe the goals of complete denture fabrication
- List and describe the types of mini-implants and overdenture attachments
- List and describe the steps involved in providing patients with mini-implants.

## Course Evaluation

Please evaluate this course by responding to the following statements, using a scale of Excellent = 5 to Poor = 0.

1. Were the individual course objectives met?	Objective #1: Yes No	Objective #3: Yes No
	Objective #2: Yes No	Objective #4: Yes No
	Objective #5: Yes No	

2. To what extent were the course objectives accomplished overall?	5	4	3	2	1	0
3. Please rate your personal mastery of the course objectives.	5	4	3	2	1	0
4. How would you rate the objectives and educational methods?	5	4	3	2	1	0
5. How do you rate the author's grasp of the topic?	5	4	3	2	1	0
6. Please rate the instructor's effectiveness.	5	4	3	2	1	0
7. Was the overall administration of the course effective?	5	4	3	2	1	0
8. Do you feel that the references were adequate?		Yes	No			
9. Would you participate in a similar program on a different topic?		Yes	No			
10. If any of the continuing education questions were unclear or ambiguous, please list them.	_____					
11. Was there any subject matter you found confusing? Please describe.	_____					
12. What additional continuing dental education topics would you like to see?	_____					

If not taking online, mail completed answer sheet to  
**Academy of Dental Therapeutics and Stomatology,**  
 A Division of PennWell Corp.

P.O. Box 116, Chesterland, OH 44026  
 or fax to: (440) 845-3447

**For IMMEDIATE results,  
 go to [www.ineedce.com](http://www.ineedce.com) to take tests online.  
 Answer sheets can be faxed with credit card payment to  
 (440) 845-3447, (216) 398-7922, or (216) 255-6619.**

Payment of \$59.00 is enclosed.  
**(Checks and credit cards are accepted.)**

If paying by credit card, please complete the following:  MC  Visa  AmEx  Discover

Acct. Number: \_\_\_\_\_  
 Exp. Date: \_\_\_\_\_

**Charges on your statement will show up as PennWell**

- |                     |                     |
|---------------------|---------------------|
| 1. (A) (B) (C) (D)  | 26. (A) (B) (C) (D) |
| 2. (A) (B) (C) (D)  | 27. (A) (B) (C) (D) |
| 3. (A) (B) (C) (D)  | 28. (A) (B) (C) (D) |
| 4. (A) (B) (C) (D)  | 29. (A) (B) (C) (D) |
| 5. (A) (B) (C) (D)  | 30. (A) (B) (C) (D) |
| 6. (A) (B) (C) (D)  | 31. (A) (B) (C) (D) |
| 7. (A) (B) (C) (D)  | 32. (A) (B) (C) (D) |
| 8. (A) (B) (C) (D)  | 33. (A) (B) (C) (D) |
| 9. (A) (B) (C) (D)  | 34. (A) (B) (C) (D) |
| 10. (A) (B) (C) (D) | 35. (A) (B) (C) (D) |
| 11. (A) (B) (C) (D) | 36. (A) (B) (C) (D) |
| 12. (A) (B) (C) (D) | 37. (A) (B) (C) (D) |
| 13. (A) (B) (C) (D) | 38. (A) (B) (C) (D) |
| 14. (A) (B) (C) (D) | 39. (A) (B) (C) (D) |
| 15. (A) (B) (C) (D) | 40. (A) (B) (C) (D) |
| 16. (A) (B) (C) (D) | 41. (A) (B) (C) (D) |
| 17. (A) (B) (C) (D) | 42. (A) (B) (C) (D) |
| 18. (A) (B) (C) (D) | 43. (A) (B) (C) (D) |
| 19. (A) (B) (C) (D) | 44. (A) (B) (C) (D) |
| 20. (A) (B) (C) (D) | 45. (A) (B) (C) (D) |
| 21. (A) (B) (C) (D) | 46. (A) (B) (C) (D) |
| 22. (A) (B) (C) (D) | 47. (A) (B) (C) (D) |
| 23. (A) (B) (C) (D) | 48. (A) (B) (C) (D) |
| 24. (A) (B) (C) (D) | 49. (A) (B) (C) (D) |
| 25. (A) (B) (C) (D) | 50. (A) (B) (C) (D) |

AGD Code 691,692

### PLEASE PHOTOCOPY ANSWER SHEET FOR ADDITIONAL PARTICIPANTS.

**AUTHOR DISCLAIMER**  
 The author(s) of this course has/have no commercial ties with the sponsors or the providers of the unrestricted educational grant for this course.

**SPONSOR/PROVIDER**  
 This course was made possible through an unrestricted educational grant. No manufacturer or third party has had any input into the development of course content. All content has been derived from references listed, and/or the opinions of clinicians. Please direct all questions pertaining to PennWell or the administration of this course to Machele Galloway, 1421 S. Sheridan Rd., Tulsa, OK 74112 or macheleg@pennwell.com.

**COURSE EVALUATION and PARTICIPANT FEEDBACK**  
 We encourage participant feedback pertaining to all courses. Please be sure to complete the survey included with the course. Please e-mail all questions to: macheleg@pennwell.com.

**INSTRUCTIONS**  
 All questions should have only one answer. Grading of this examination is done manually. Participants will receive confirmation of passing by receipt of a verification form. Verification forms will be mailed within two weeks after taking an examination.

**EDUCATIONAL DISCLAIMER**  
 The opinions of efficacy or perceived value of any products or companies mentioned in this course and expressed herein are those of the author(s) of the course and do not necessarily reflect those of PennWell.

Completing a single continuing education course does not provide enough information to give the participant the feeling that s/he is an expert in the field related to the course topic. It is a combination of many educational courses and clinical experience that allows the participant to develop skills and expertise.

**COURSE CREDITS/COST**  
 All participants scoring at least 70% on the examination will receive a verification form verifying 3 CE credits. The formal continuing education program of this sponsor is accepted by the AGD for Fellowship/Mastership credit. Please contact PennWell for current term of acceptance. Participants are urged to contact their state dental boards for continuing education requirements. PennWell is a California Provider. The California Provider number is 4527. The cost for courses ranges from \$49.00 to \$110.00.

Many PennWell self-study courses have been approved by the Dental Assisting National Board, Inc. (DANB) and can be used by dental assistants who are DANB Certified to meet DANB's annual continuing education requirements. To find out if this course or any other PennWell course has been approved by DANB, please contact DANB's Recertification Department at 1-800-FOR-DANB, ext. 445.

**RECORD KEEPING**  
 PennWell maintains records of your successful completion of any exam. Please contact our offices for a copy of your continuing education credits report. This report, which will list all credits earned to date, will be generated and mailed to you within five business days of receipt.

**CANCELLATION/REFUND POLICY**  
 Any participant who is not 100% satisfied with this course can request a full refund by contacting PennWell in writing.

© 2011 by the Academy of Dental Therapeutics and Stomatology, a division of PennWell

3M511MiniDE