

# Small-Diameter Implants: Indications and Contraindications

MITHRIDADE DAVARPANAH, MD, DDS\*  
HENRY MARTINEZ, DDS†  
JEAN-FRANÇOIS TECUCIANU, MD, DDS‡  
RENATO CELLETTI, DDS§  
RICHARD LAZZARA, DMD, MScD\*

## ABSTRACT

The choice of implant diameter depends on the type of edentulousness, the volume of the residual bone, the amount of space available for the prosthetic reconstruction, the emergence profile, and the type of occlusion. Small-diameter implants are indicated in specific clinical situations, for example, where there is reduced interradicular bone or a thin alveolar crest, and for the replacement of teeth with small cervical diameter. Before using a small-diameter implant, the biomechanical risk factors must be carefully analyzed. Preliminary reports of this type of implant show good short- and medium-term results.

## CLINICAL SIGNIFICANCE

Specific clinical situations indicate the use of small-diameter implants: a reduced amount of bone (thin alveolar crest) and where the replacement tooth requires a small cervical diameter. In some cases, the use of small-diameter implants avoids bone reconstruction.

(*J Esthet Dent* 12:186–194, 2000)

Many longitudinal studies have demonstrated the reliability of osseointegration in the treatment of different types of edentulousness.<sup>1–4</sup> The standard implant (3.75 or 4.00 mm) has been used in the majority of these studies. A certain minimum volume of bone is essential for the placement of a standard implant. A minimum of 1 mm of bone must surround the entire

implant surface. Placing a standard implant in suboptimal anatomic situations increases the risks of complications and failure.<sup>5</sup> A small-diameter implant (3.0 to 3.4 mm) may be indicated where the alveolar crest is narrow or where the mesiodistal space available is less than 7 mm. In some cases, the use of small-diameter implants prevents the need for bone reconstruction

(bone grafts, guided bone regeneration, crest expansion) or the enlargement of the mesiodistal space, at the level of bone or future prosthesis (orthodontics).<sup>6</sup> In all cases, before small-diameter implants are used, the biomechanical risk factors must be carefully assessed. The aim of this article is to present the indications and contraindications for 3i Implant Innovations

\*Clinical Assistant Professor, Department of Periodontology, Hôpital Pitié-Salpêtrière, Paris; and Private Practice, Paris, France

†Clinical Assistant Professor, Department of Oral Surgery, Faculty of Odontology, University of Paris 7, Paris, France

‡Professor and Chairman of Periodontics, Department of Periodontology, Hôpital Pitié-Salpêtrière, Paris; and Private Practice, Paris, France

§Clinical Assistant Professor, Department of Periodontology, University of G. d'Annunzio, Chieti; and Private Practice, Rome, Italy

\*Clinical Assistant Professor, Periodontal and Implant Regenerative Center, University of Maryland, Baltimore, Maryland

(Palm Beach Gardens, Florida) small-diameter implants (Figure 1).

REVIEW OF THE LITERATURE

Several types of small-diameter implants have been commercially available since the end of the 1980s (Calcitek®, Sulzer Calcitek, Inc., Carlsbad, California; IMZ®, Nobel Biocare AB, Göteborg, Sweden; 3i Implant Innovations; ITI®, Straumann, Waldenburg, Switzerland). Few articles have been published on small-diameter implants.<sup>6,7</sup> Although there has been no report in the literature of any longitudinal study relating to this type of implant, the majority of authors who have reported on the reliability of different implant systems mention their results with small-diameter implants (Table 1).<sup>8-14</sup>

In an 8-year clinical and radiographic study of 1374 hydroxyapatite-coated implants (Integral® Sulzer Calcitek, Inc.), Block et al reported

good results for 238 implants of 3.25-mm diameter.<sup>8</sup> Among these implants, 43% were placed in posterior segments. There was no analysis of complications or failures. Spiekermann and colleagues studied the clinical and radi-

ographic results of 300 IMZ implants of 3.3-mm and 4.0-mm diameter over 1 to 10 years (mean 5.7 yr).<sup>9</sup> They were used to stabilize mandibular overdentures in 136 patients. One hundred and twenty-seven small-diameter implants

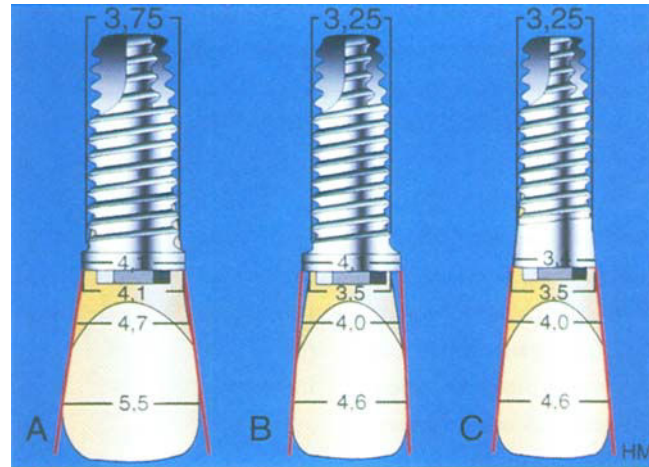


Figure 1. A, Standard implant: the collar diameter of the implant (4.1 mm) allows an appropriated emergence profile for a maxillary central incisor. B, Small-diameter implants with standard collar (4.1 mm) (Miniplant™) are indicated for thin alveolar ridges. C, Small-diameter implants with narrow collar (3.4 mm) (Micro-miniplant™) are indicated for reduced mesiodistal prosthetic space.

TABLE 1. RESULTS OF STUDIES OF SMALL-DIAMETER IMPLANTS.

Author (yr)	Type of Implant	Follow-up Period (yr)	Implant Diameter (mm)	Total Number of Implants	Number of Implant Failures	Success Rate (%)
Block et al (1993) <sup>8</sup>	Integral	8	3.25	238	2	99
Nobel Biocare (1996) <sup>14</sup>	Branemark	NS	3.00	201	7	93
Spiekermann et al (1995) <sup>9</sup>	IMZ	1-10	3.30	127	8	95
Saadoun & Le Gall (1996) <sup>10</sup>	Steri-Oss	8	3.25	306	34	89
Sethi et al (1996) <sup>11</sup>	Osteo Ti	3	2.75	51	0	100
			3.00	58	0	100
Lazzara et al (1996) <sup>12</sup>	3i	5	3.30	202	8	96
Buser et al (1997) <sup>13</sup>	ITI	8	3.30	213	NS	NS

NS = not specified.

(3.3 mm) were placed in 61 patients with narrow alveolar crests. After 5 years, the authors showed a success rate of 95% for the 3.3-mm diameter implants.

In 1996, Saadoun and Le Gall published the 8-year clinical results of 1499 Steri-Oss® (Nobel Biocare) implants in 605 patients undergoing treatment for various types of edentulousness.<sup>10</sup> Four different types of implant were used: 3.25-mm screwed titanium implants, 4.5-mm screwed hydroxyapatite-coated implants, 3.8-mm hydroxyapatite-coated implants, and 3.8-mm titanium plasma sprayed (TPS) implants. Three hundred and six small-diameter implants of different lengths (8, 10, 12, 14, and 16 mm) were inserted, and 296 of them were brought into function. The authors reported 34 failures (89% success rate). It is interesting to note that 16 of the 34 failures involved the 8-mm long implants (failure rate 43.2%). The authors advise against the use of short small-diameter implants.

In 1996, Sethi and colleagues presented preliminary 3-year results of 370 Osteo Ti® implants (Osteo Implant Corp., New Castle Pennsylvania) that had been placed in 135 patients.<sup>11</sup> Four different implant diameters were used (2.75, 3.0, 3.75, and 4.5 mm). The small-diameter implants were manufactured from titanium alloy. Fifty-one of the implants placed were 2.75-mm,

and 58 were 3.0-mm diameter; 48% were placed in the maxillary anterior segment; 13% in the mandibular anterior segment; 39% in posterior segments. No failures were reported among these small-diameter implants.

In a multicenter retrospective study, Lazzara and colleagues showed the results of 1871 implants (3i Implant Innovations) after 5 years.<sup>12</sup> The authors reported on 202 plasma-sprayed cylinder implants of 3.3-mm diameter. Twenty implants were excluded from the study because of lack of follow-up information. Success rates in the mandible and maxilla were 96% and 95.5%, respectively. Of the eight failures reported, five were of 7-mm long implants. The causes of failure were absence of osseointegration for six implants and excessive bone loss for two implants.

Buser and co-workers analyzed the results for 2359 ITI implants in 1003 patients over 8 years.<sup>13</sup> Four different types of implants were used: 4.1-mm solid screw implants (n = 1141); 4.1-mm hollow screw implants (n = 639); hollow-cylinder implants (n = 366); and 3.3-mm solid-screw implants (n = 213). The observation period was less than 5 years, and the authors did not report the results for the small-diameter implants.

At the beginning of the 1990s Nobel Biocare marketed 3-mm fixtures. The 20% reduction of

implant diameter from 3.75 to 3.0 mm reduced the resistance to fracture by approximately 50%.<sup>14</sup> A preliminary report of a multicenter study that began in 1988 showed a success rate of 93% for 201 implants placed in 106 patients.

**INDICATIONS FOR SMALL-DIAMETER IMPLANTS**

The choice of implant diameter depends on the type of edentulousness, the volume of residual bone, the amount of available space for the prosthesis, the emergence profile, and the type of occlusion (Figure 2).

The indications for small-diameter implants are (1) reduced amount of interradicular bone, (2) narrow ridges, and (3) replacement of tooth with reduced mesiodistal prosthetic space.

There are two types of threaded small-diameter implants (3i Implant Innovations): Miniplant (standard collar: 4.1 mm), indicated for narrow ridges (Figure 3), and Micro-miniplant (narrow collar: 3.4 mm), indicated for reduced mesiodistal prosthetic space (Figure 4). Both implant designs are manufactured from high-strength grade 1 commercially pure titanium to ensure maximum strength. Also, the original body design of small-diameter implants provides more bulk material between threads. The goal of this design is to increase implant strength and to decrease the risk of fracture.

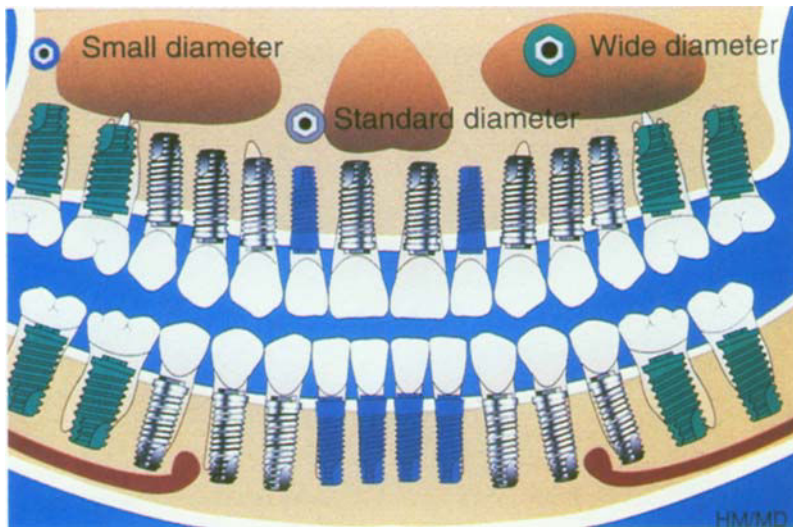


Figure 2. The choice of the implant diameter depends on the coronal anatomy.

crest, the duration of any possible orthodontic treatment, and the magnitude of the occlusal forces (Figure 5).

**Narrow Ridges**

The point at which the crown emerges has a profound effect on the esthetic result.<sup>16</sup> Where the alveolar crest is less than 6 mm in thickness, the use of small-diameter implants should be considered. A buccal undercut or advanced buccal resorption can lead to an emergence that is too far to the lingual (Figure 6).<sup>16</sup> Sometimes it is necessary to treat maxillary bone loss with bone reconstructive techniques.

**Reduced Mesiodistal Prosthetic Space**

Where there is reduced space available for the prosthesis, the choice of implant depends upon the diameter of the crown at the cervical margin

**Reduced Interradicular Bone**

In the anterior segments, an interradicular distance of less than 6 mm contraindicates the use of a 3.75-mm diameter implant. The risk of damage to the adjacent roots must be borne in mind.<sup>15</sup> Where the mesiodistal bony space available is 5 to

6 mm, several treatment options can be considered: enlargement of the space by orthodontic treatment, the use of small-diameter implants, or conventional prosthetic treatment. The choice of treatment is guided by the site of the tooth loss, the thickness of the alveolar bone

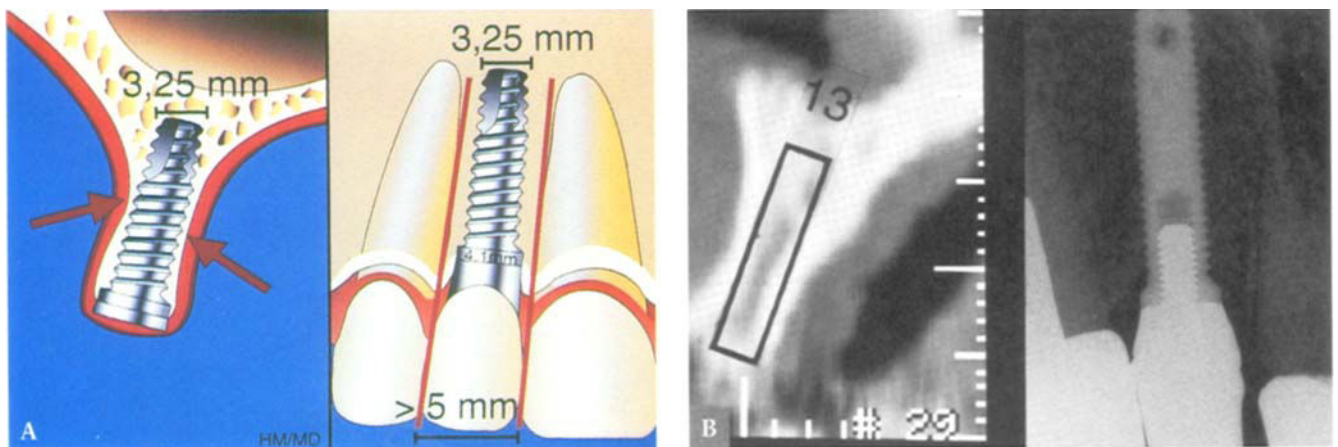


Figure 3. A, Small-diameter implants with standard collar (4.1 mm) are indicated for narrow ridges or reduced amount of bone between adjacent roots. B, Oblique cuts enabling the choice of the implant diameter (left); and radiographic view of a small-diameter 3i implant with a standard collar (right).

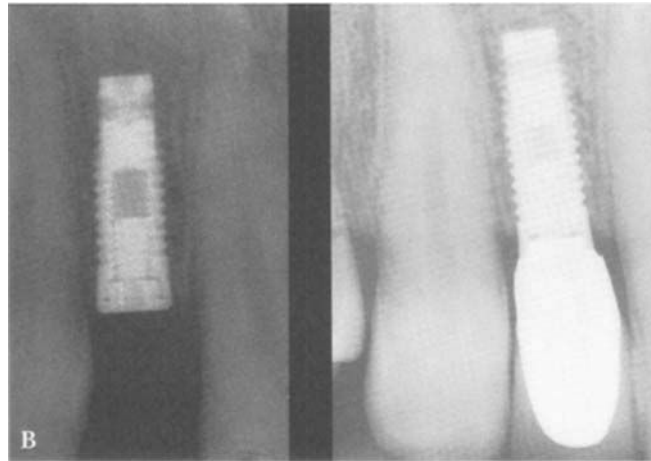
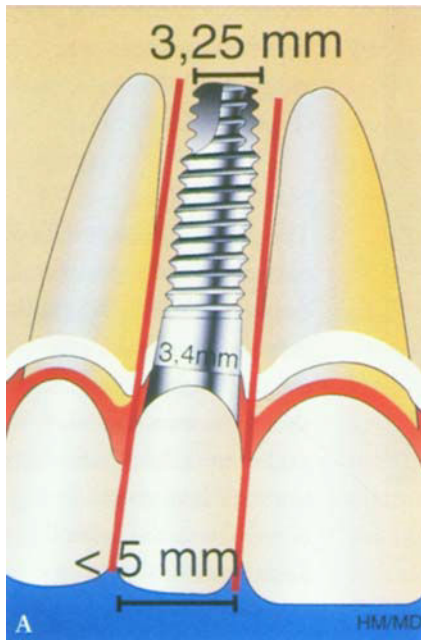


Figure 4. A, Small-diameter implants are indicated for reduced mesiodistal space. B, Radiograph of a small-diameter 3i implant with a narrow collar to replace the maxillary right lateral incisor (left). Note the reduced mesiodistal space available. Appropriate emergence profile for a maxillary lateral incisor (right). (Dr. F. Hazan)

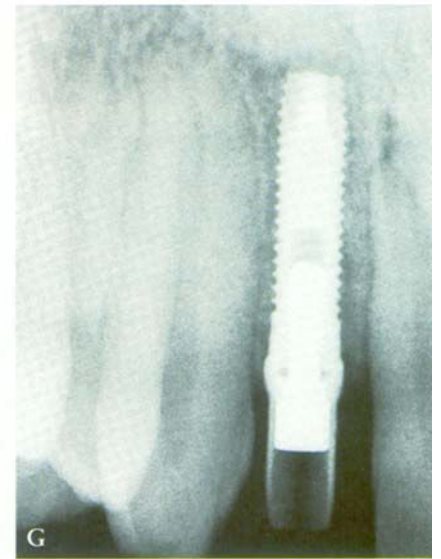
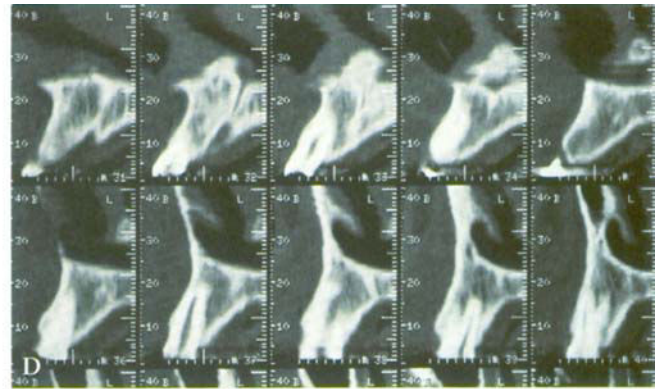
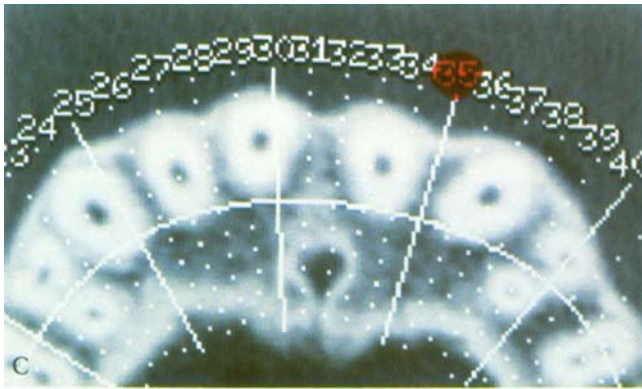
and the emergence profile.<sup>17</sup> The mesiodistal prosthetic space for lower incisors and sometimes for

maxillary lateral incisors is less than 4.5 mm. It is often impossible to obtain a satisfactory esthetic

result with a standard implant, which has a diameter at the collar of 4.1 mm. It is essential for the

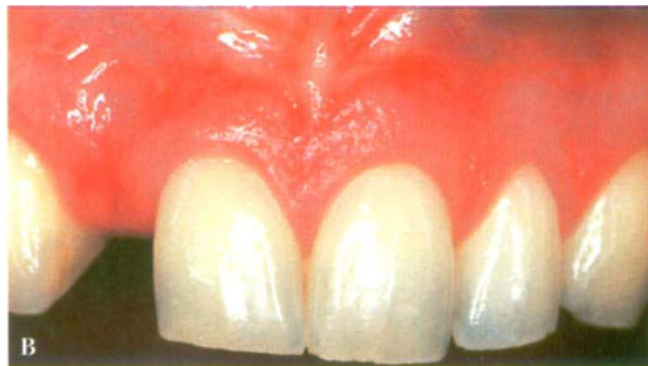
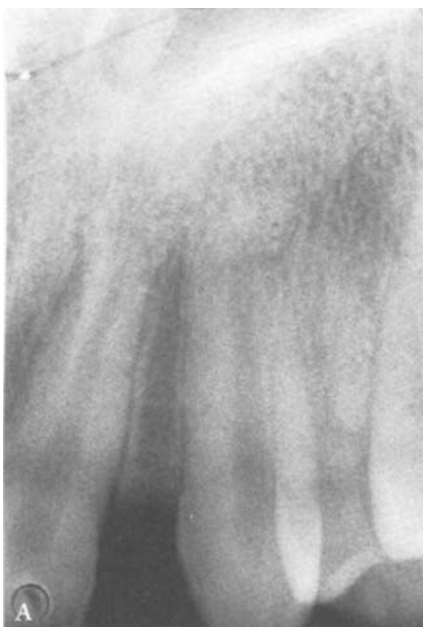
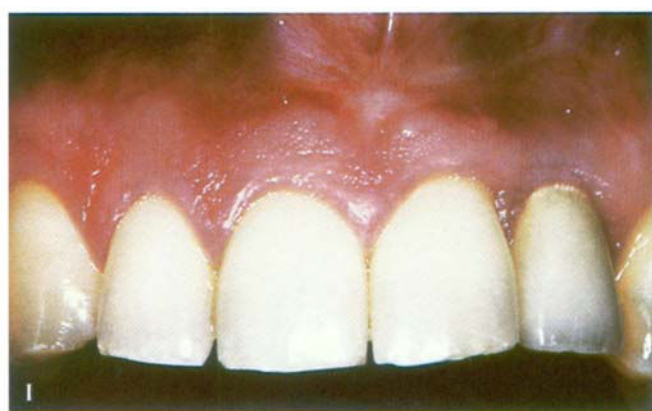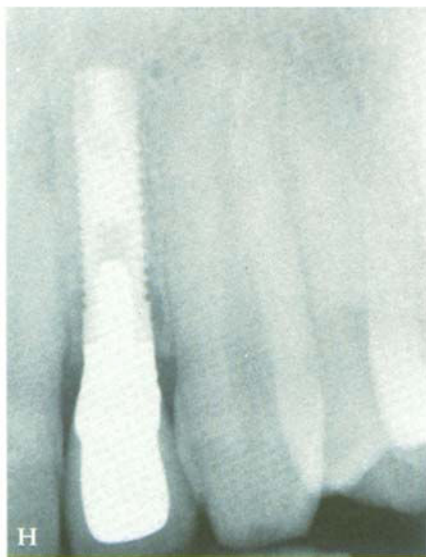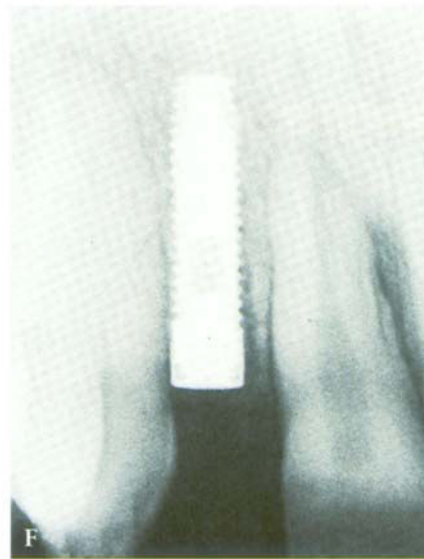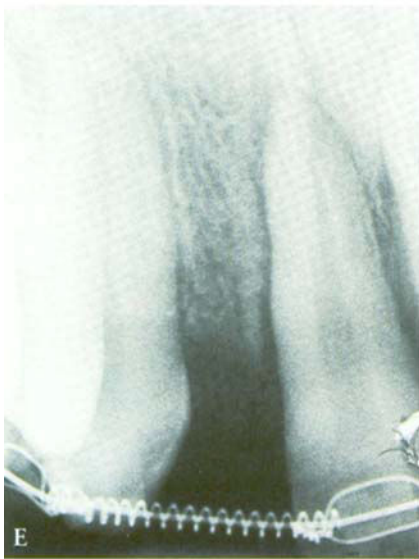Figure 5. A, Hypodontia of a maxillary lateral incisor. Note the reduced space between adjacent roots. B, Clinical view of the edentulous site. C, Axial CT scan. Note the proximity between central incisor and canine roots. D, The oblique CT scan cuts confirm the minimal space available. E, Radiographic view after 6 months of orthodontic treatment. Note the amount of the mesiodistal space. F, Radiographic control after placement of a small-diameter implant (3i Implant Innovations, Micro-miniplant). G, Periapical radiograph after placement of the prosthetic abutment. H, Final radiographic view. Note the respect of adjacent roots and the adequate emergence profile. I, Clinical view of the final crown at 6 months.



cervical mesiodistal diameter of the implant to be slightly less than that of the future prosthetic crown, to

achieve a better esthetic result (see Figure 4). In addition, the implant must be buried 2 to 4 mm more

apical than the cementoenamel junction (CEJ) of the adjacent teeth. At this level, the diameter of the

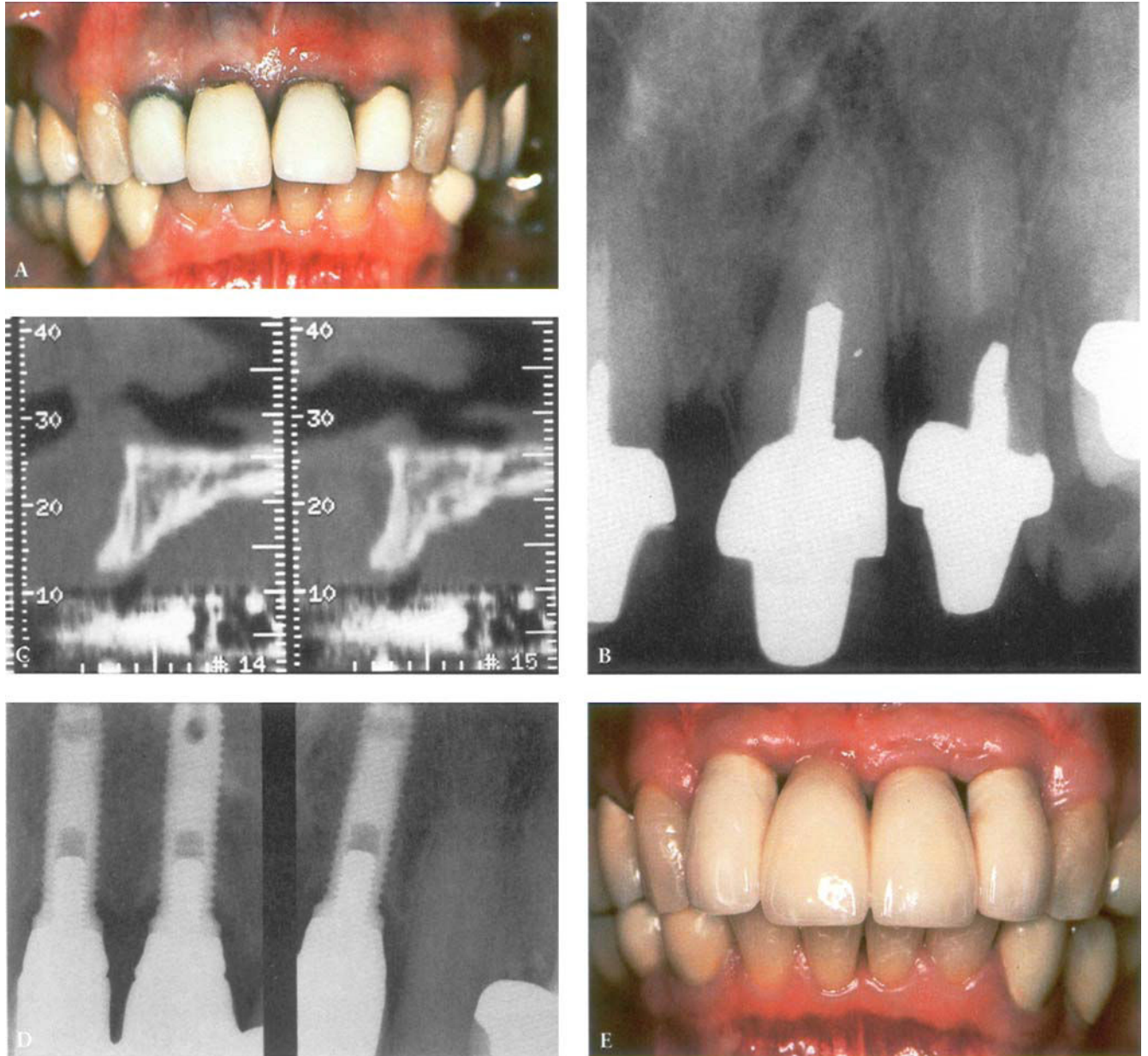


Figure 6. A, Clinical and B, radiographic views of maxillary incisors. Note the lesions of the periodontium and endodontium associated with teeth # 21 and 22. C, Oblique CT scan cuts indicate the type of small-diameter implant to be used. If the alveolar crest had not been narrow, two standard implants supporting a four-unit bridge would have been a treatment option. D, Radiographic view 1 year after stage II surgery. Three small-diameter 3i Implant Innovations Miniplant implants (collar diameter: 4.1 mm) were placed in the area of teeth # 11, 12, and 22. E, Clinical view of the final restorations after 1 year. (Dr. Ed Cohen)

root is necessarily less. To replace a tooth with a mesiodistal diameter equal to or less than 4 mm, an implant with a small collar diameter (less than 4 mm) must be considered and may result in a more natural emergence profile.

**TOOTH MORPHOLOGY AND HYPODONTIA**

In cases of hypodontia (e.g., a missing mandibular incisor or maxillary lateral incisor), frequently, there is a limited volume of bone or space for the prosthetic reconstruction. Convergence of the roots or crowns of the adjacent teeth can be corrected by orthodontic treatment prior to placing a small-diameter implant (see Figure 5).

In the anterior segment, the morphology of the future prosthetic crown should resemble that of the contralateral tooth. A significant difference may be regarded as an esthetic failure. Average cervical and coronal

dimensions of the incisor teeth and sometimes of the premolars act as a guide to the selection of a small-diameter implant (Table 2).<sup>18</sup>

**BIOMECHANICAL CONSIDERATIONS**

Compared with standard implants, the small-diameter ones have less surface area for anchorage and reduced resistance to fracture.<sup>14</sup> Before the use of this type of implant is considered, the occlusal forces must be properly analyzed. Lack of long-term studies for all types of small-diameter implants dictates caution. Small-diameter implants are contraindicated for the replacement of canines and molars. According to Forsmalm, there is an increased risk of fracture with fixtures of 3.3-mm diameter.<sup>15</sup> Their resistance to fracture is 25% less than that of standard fixtures.

At the beginning of the 1990s, several teams studied the biomechanical forces imposed on bone

with implants of different diameters.<sup>7,19-20</sup> Matsushita and colleagues analyzed the forces imposed on bone by cylindrical implants of 3-, 4-, 5-, 6-, 7-, and 8-mm diameter in response to vertical and lateral forces of 100 N.<sup>19</sup> With these forces, the major loading was in the cortical bone at the level of the neck of the implant. These authors considered that the distribution of forces was less favorable with small-diameter implants. Interestingly, Rieger and co-workers considered that the small-diameter implants improved the distribution of forces to the bone.<sup>20</sup>

Block and colleagues investigated the traction forces needed to remove hydroxyapatite-coated implants (Calcitek) after 15 weeks of osseointegration in dogs.<sup>7</sup> Different lengths (4, 8, and 15 mm) and diameters (3.0, 3.3, and 4.0 mm) were studied. The increase in the magnitude of the force needed to remove

**TABLE 2. AVERAGE MEASUREMENTS OF ANTERIOR TEETH.\***

Tooth	Coronal Diameter (mm)		Cervical Diameter (mm)	
	Mesiodistal	Buccolingual	Mesiodistal	Buccolingual
Maxillary central	8.5	7.0	7.0	6.0
Maxillary lateral	6.5	6.0	5.0	5.0
Maxillary 1st premolar	7.0	9.0	5.0	8.0
Maxillary 2nd premolar	7.0	9.0	5.0	8.0
Mandibular central	5.0	6.0	3.5	5.3
Mandibular lateral	5.5	6.5	3.8	5.8
Mandibular 1st premolar	7.0	7.5	5.0	6.5
Mandibular 2nd premolar	7.0	8.0	5.0	7.0

\*Modified from Wheeler RC. Dental anatomy, physiology, and occlusion. Philadelphia: WB Saunders, 1974.



the implants was proportional to their length. In contrast, the reported traction forces did not vary with different implant diameters.

Unfortunately, the studies on implants of various diameters have produced contradictory results. The research protocols and methods used have been too diverse. Analyses of forces have been undertaken on laboratory models using bone substitutes. Small-diameter implants can be indicated after careful evaluation of occlusal forces. Only long-term clinical results will provide information on the reliability of small-diameter implants.

#### CONCLUSIONS

Small-diameter implants are indicated for specific clinical situations: a reduced amount of interradicular bone, a narrow alveolar crest, and where the replacement tooth requires a small cervical diameter. This treatment option must take into account the emergence profile, the contour of the residual crest, the morphology of the future tooth replacement, and biomechanical factors. It is necessary to underline the importance of a careful occlusal analysis. Long-term multicenter studies are essential to confirm the good clinical results that recently have been obtained.

#### REFERENCES

- Adell R, Lekholm U, Rockler B, Brånemark P-I. A 15-year study of osseointegrated implants in the treatment of edentulous jaw. *Int J Oral Surg* 1981; 10:387-416.
- Adell R, Eriksson B, Lekholm U, Brånemark P-I, Jemt T. A long-term follow-up study of osseointegrated implants in the treatment of totally edentulous jaw. *Int J Oral Maxillofac Implants* 1990; 5:347-359.
- Engquist B, Bergendal T, Kallus T, Linden U. A retrospective multicenter evaluation of osseointegrated implants supporting overdentures. *Int J Oral Maxillofac Implants* 1988; 2:129-134.
- Jemt T, Lekholm U, Adell R. Osseointegrated implants in the treatments of partially edentulous patients: a preliminary study on 875 consecutively placed fixtures. *Int J Oral Maxillofac Implants* 1989; 4: 211-217.
- Davarpanah M, Martinez H, Kebir M, Renouard F. Complications et échecs de l'ostéointégration. *J Parodontol Implantologie Orale* 1996; 15:285-314.
- Dexter Barber H, Seckinger R. The role of the small diameter dental implant: a preliminary report on the Miniplant System. *Compendium* 1994; 15:1390-1392.
- Block MS, Delgado A, Fontenot MG. The effect of diameter and length of hydroxylapatite-coated dental implants on ultimate pullout force in dog alveolar bone. *J Oral Maxillofac Surg* 1990; 48:174-178.
- Block M, Kent JN. Cylindrical HA-coated implants 8-year observations. *Compend Cont Educ Dent* 1993; 14(Suppl): 5526-5532.
- Spiekermann H, Jansen VK, Ritcher EJ. A 10-year follow-up study of IMZ and TPS implants in the edentulous mandible using bar-retained overdentures. *Int J Oral Maxillofac Implants* 1995; 10:231-243.
- Saadoun A, Le Gall MG. An 8-year compilation of clinical results obtained with Steri-Oss endosseous implants. *Compendium* 1996; 17:669-688.
- Sethi A, Harding S, Sochor P. Initial results of the Osteo Ti implant system in general dental practice. *Eur J Prosthodont Restor Dent* 1996; 4:21-28.
- Lazzara RJ, Siddiqui AA, Binon P, et al. Retrospective multicenter analysis of 3i endosseous dental implants placed over a five-year period. *Clin Oral Impl Res* 1996; 7:73-83.
- Buser D, Mericske-Stern R, Bernard JP, et al. Long-term evaluation of non-submerged ITI implants. Part 1: 8-year life table analysis of a prospective multicenter study with 2359 implants. *Clin Oral Implants Res* 1997; 8:161-172.
- Jornicus H. Developing the narrow platform. *The Nobel Biocare Global Forum* 1996; 10(4):3.
- Forsmal G. Evaluating implant post strength. *The Nobel Biocare Global Forum* 1996; 10(3):5.
- Davarpanah M, Kebir M, Tecucianu J-F, Etienne D, Martinez H. Implants unitaires: impératifs chirurgicaux et prothétiques. *J Parodontol Implantologie Orale* 1995; 14:423-434.
- Lazzara RJ. Criteria for implant selection: surgical and prosthetic considerations. *Implant Report* 1994; 6:55-62.
- Wheeler RC. *Dental anatomy, physiology, and occlusion*. Philadelphia: WB Saunders, 1974.
- Matsushita Y, Kitoh T, Mizuta K, Ikeda H, Suetsugu T. Two-dimensional FEM analysis of hydroxyapatite implants: diameter effects on stress distribution. *J Oral Implantol* 1990; 16:6-11.
- Rieger MR, Adams WK, Kinzel GL. A finite element survey of eleven endosseous implants. *J Prosthet Dent* 1990; 63: 457-465.

Reprint requests: Mithridate Davarpanah, MD, DDS, 174 rue de courcelles, 75017 Paris; e-mail: m.davarpanah@wanadoo.fr  
© 2000 B.C. Decker Inc.