

CASE REPORT

Denture Stabilization with Mini Dental Implants

Paresh B Patel

ABSTRACT

Mini dental implants can provide support for stabilization of a removable full denture and can be a minimally invasive surgery. In addition mini implants can be used in cases where there may be anatomical, medical or financial constraints.

Keywords: Denture stabilization, Mini dental implants, Minimally invasive surgery.

How to cite this article: Patel PB. Denture Stabilization with Mini Dental Implants. *Int J Clin Implant Dent* 2015;1(3):101-103.

Source of support: Nil

Conflict of interest: None

INTRODUCTION

With the population of baby boomers increasing in number and size, the number of edentulous and partially edentulous patients is also increasing. Since tooth loss and age are related, these types of patients are demanding a variety of implant-retained restorations. Whether it is due to neglect, caries, medications, or other systemic reasons, patients are presenting to practices everywhere, needing extractions of a few teeth or of full mouth.

Patients that undergo extractions are concerned about ill-fitting or loose dentures and the inability to eat or function without teeth. Because of these concerns, most dentists do not wish to provide this kind of dentistry. The use of implants in the restorative plan can increase case acceptance as well as success for the patient and doctor. Implants, whether small or traditional, allow patients with dentures to eat and function similar to when they had teeth. In other words, having some type of implant-retained prosthesis makes life much better for a denture patient and the treating dentist.

Endosseous implants have been successfully used to restore edentulous ridges with implant-supported fixed bridges, hybrid prosthetic dentures, and removable overdenture prostheses for many years. However, due to deficiencies in the remaining bone, complicated medical history, or financial reasons, not everyone is a candidate for traditional sized implants. I have found that with a

highly resorbed ridge small diameter dental implants can offer a great alternative treatment to stabilize dentures.

Small diameter implants placed with flapless surgery to support dentures presents an alternative method of restoring patients with atrophic jaws. They dramatically broaden the spectrum of overdenture patients who can be successfully treated. These small diameter implants (1.8–3.0 mm) differ from their full-sized counterparts in a number of significant ways. The configuration of the implant permits a more conservative placement protocol. No tissue flaps or tapping procedures are required, which results in fewer traumas to both gingival tissue and bone. Their smaller size also permits placement in ridges that might not otherwise be suitable for full-sized implants.

The implants are firmly seated in place in intimate contact with bone. Once they have been fixed in place, they can be immediately loaded. There is no need for a long waiting period or second stage surgery. The simplified protocols, conservative procedures, and elimination of gingival surgery make small diameter implants ideal for medically, anatomically, and financially compromised patients.

CASE REPORT

A man in his late sixties presented to our office frustrated with his upper and lower complete dentures. He complained that his upper denture was nonretentive and nonfunctional, always falling out during speech or eating. His use of moderate amounts of adhesive to keep the prosthesis retained would gag him severely. He reported similar complaints with his lower denture as well (Fig. 1).

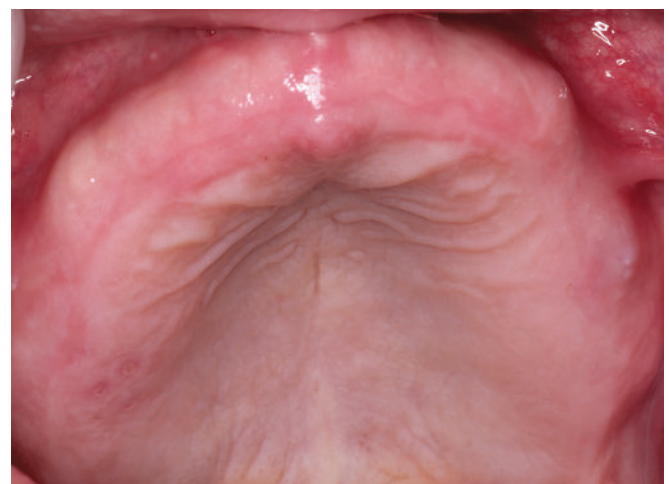

Fig. 1: Preoperative condition maxillary residual ridge

General Dentist

Dr. Paresh Patel Dental Clinic, Lenoir, North Carolina, USA

Corresponding Author: Paresh B Patel, 310, Mulberry St SW Lenoir, North Carolina, USA, Phone: +18287547881, e-mail: pareshpateldds2@gmail.com

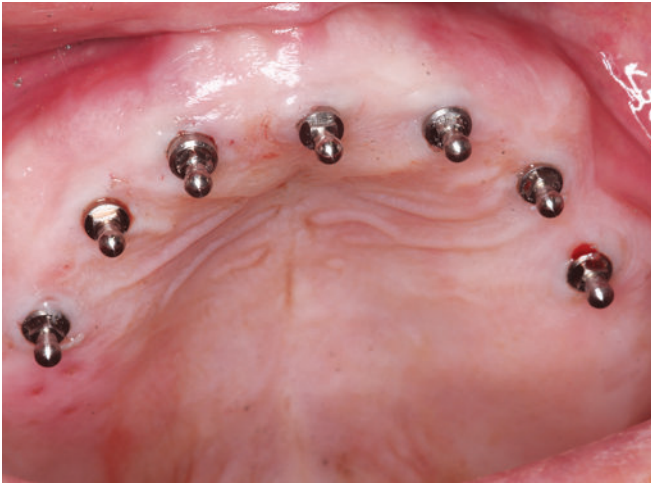

Fig. 2: Immediate condition after mini dental implant insertion

Palpation and radiographic examination revealed a moderately narrowed maxillary and mandibular ridge. Because of this, it was important to utilize small diameter implants so that there was at least 1 mm of bone on the buccal and lingual sides of the implants.

In order to stabilize his denture, seven mini dental implants of various diameters would be placed in the premaxilla area to aid in the retention of the prosthesis. Our selection consisted of one-piece O-ball mini dental implants. These small diameter implants (2.5–3.0 mm) were selected for this particular case because of the active aggressive thread design. The self-tapping and bone condensing features also would help in establishing primary stability. In summary, it is important to select an implant that allows for immediate loading with deeper threads by resisting lateral occlusal forces, especially when softer bone is present.

A 1.5mm pilot drill was placed in the sites and advanced to half of the depth of the implant using a surgical motor with generous amounts of cooled sterile water. Paralleling pins were placed in the sites of the osteotomies and an X-ray taken to check the angulations

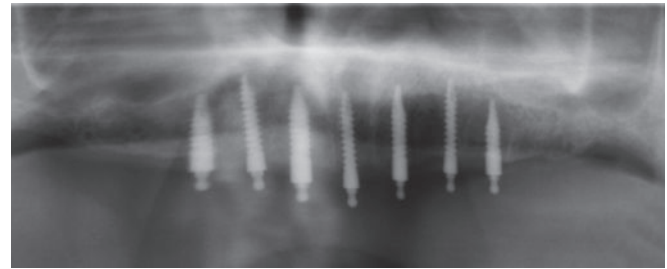


Fig. 3: Final pan X-ray

to ensure proper orientation among the implant sites. No other drills were used as the mini dental implant would drive its way into the bone to full depth. Once the osteotomies were completed, seven mini dental implants were placed in the osteotomies using a surgical handpiece set at 15 rpm and 40 Ncm of torque. The ratchet wrench was then connected to the adapter and the implants torqued to final depth, reaching a torque level of greater than 35 Ncm (Fig. 2). A postoperative radiograph was made of the implants before initiating the prosthetic phase of treatment (Fig. 3).

Once the implants were placed, the denture was relieved to allow full seating of the denture with no rocking on the implants. A soft liner was placed and impressions taken to fabricate a metal-reinforced horseshoe-shaped denture (Figs 4 and 5). Once the new metal frame was returned from the lab, the traditional steps to fabricating a complete denture were followed. After the final wax setup was approved, the denture was finalized. The undercut below the O-balls were blocked out. The cleaned and dried recesses that were created in the denture were filled with self-cure acrylic and seated onto the implants and allowed to polymerize. Upon setting, the denture was relieved of any excess flash and any voids were filled in with pink composite (Figs 6 and 7). The patient was very pleased with the fit, function, and esthetics of the new denture. This same process was repeated on the lower arch with five mini dental implants (Figs 7 to 9).

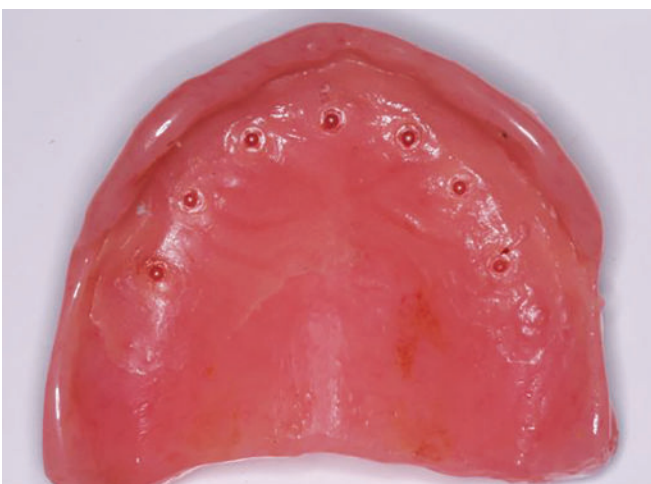

Fig. 4: Soft lined upper full denture

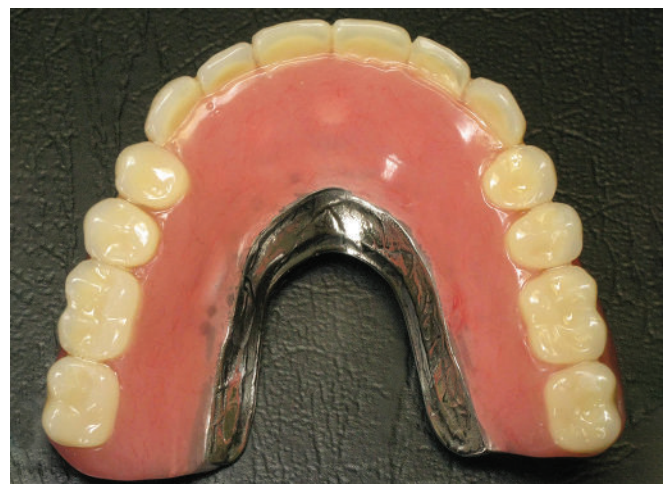

Fig. 5: Final cast metal reinforced upper overdenture

Mini dental implants can provide clinical and economic benefits to your practice and restore function and confidence in your patients. Denture retention and function are dramatically improved and the results usually require no

ridge augmentation. The advent of the mini dental implant has given general dentists an easy, less costly, and rapid way of solving many of the difficult problems that arise in dental practice with complete dentures (Figs 10 and 11).

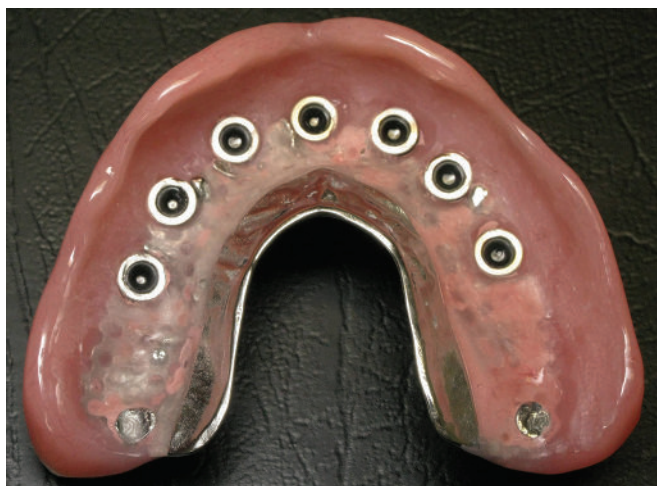

Fig. 6: Final cast metal overdenture with retentive housing inserted

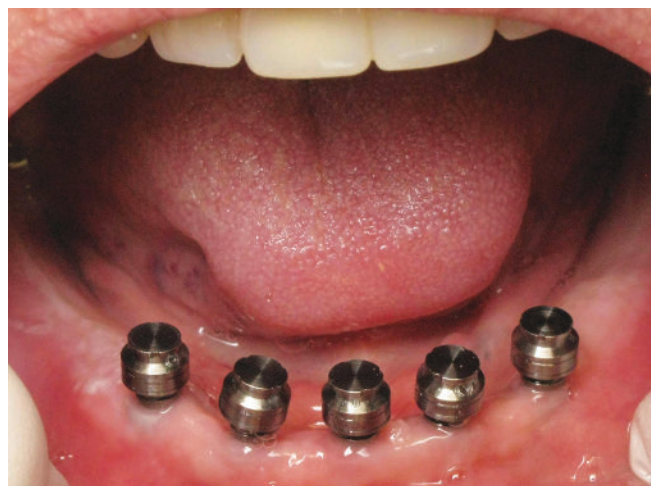

Fig. 7: Mandibular ridge with mini implant retentive housings

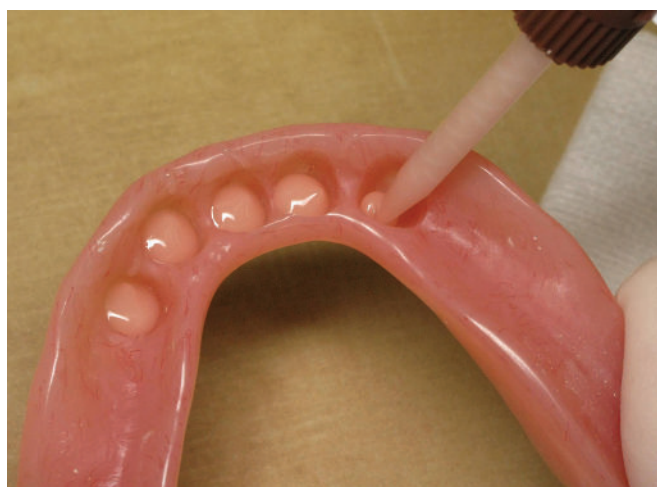

Fig. 8: Chairside pickup material injected into lower denture

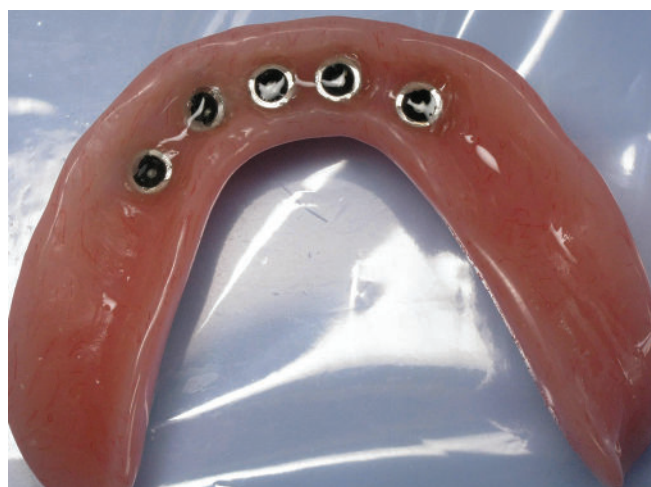

Fig. 9: Final retentive housing secured into lower denture

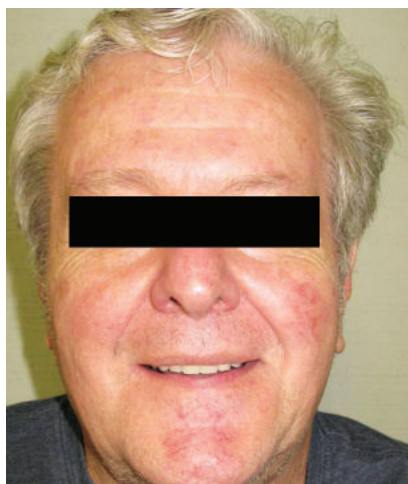

Fig. 10: Patient full face with proper lip support and correct VDO

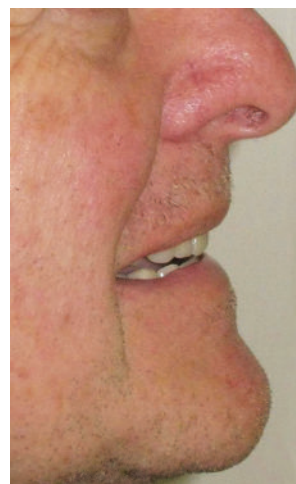

Fig. 11: Patient full face with proper lip support and correct VDO