

## 'One-piece' immediate-load post-extraction implants in labial bone-deficient upper jaws

F Rossi<sup>1\*</sup>, ME Pasqualini<sup>2</sup>, F Carinci<sup>3</sup>, F Meynardi<sup>4</sup>, P Diotallevi<sup>5</sup>, E Moglioni<sup>6</sup>, S Fanali<sup>7</sup>

### Abstract

#### Introduction

Contusive trauma or malocclusion-related periodontal disease can severely compromise the upper anterior teeth, leading to labial bone resorption and ultimately loss of function and unsightly root exposure. To resolve these issues, we propose the replacement of compromised teeth using one-piece, immediate-load, post-extraction implants. These can be implanted and fitted with customised temporary crowns in a single surgical procedure, restoring function and aesthetics and allowing recovery of the bone deficit with reduced healing times and limited patient discomfort. This study aims to assess the one-piece, immediate-load, post-extraction implants in labial bone-deficient upper jaws.

#### Materials and methods

One-piece, wide diameter, titanium screw implants with thread measurements of 3.5 mm and 4.5 mm, with an abutment of 2.5 mm, were positioned and splinted by intraoral welding.

#### Results

These implants yielded satisfactory functional and aesthetic outcomes

in bone-deficient upper anterior sectors, without invasive regenerative procedures.

#### Conclusion

The low invasiveness of the approach used in this research study consents rapid healing, reduced biological burden and greater patient benefit.

#### Introduction

Root fracture and, more often, occlusal trauma-related periodontal disease<sup>1-3</sup> can severely compromise the teeth in the upper anterior sector, leading to labial bone deficit, root exposure, loss of function and poor aesthetics.

The front teeth, i.e. the central and lateral incisors and the canines, are particularly susceptible to these problems. This is due to their natural inclination, which causes them to develop transversal forces upon contact, unlike the vertical forces that develop in molars and premolars, where the occlusal forces are dispersed along the long axis of the root and are therefore well tolerated. Hence, in physiological static occlusion, the anterior teeth should barely touch their antagonists if these damaging forces are to be avoided<sup>4</sup>. At the occurrence of centric pre-contacts in these teeth, stable static mandibular support is compromised, disturbing both swallowing and chewing mechanisms and the harmony of the neuromuscular system. In order to counteract this occlusal instability, the lower jaw, which is unable to rotate, moves forwards and/or to the side (prochoresis) in the search for replacing static contacts and achieving new equilibrium. Although this compensatory position consents mastication and swallowing, it is in

fact pathological because it is based on traumatic non-centric contacts. During swallowing, the dysfunctional occlusal loads and transversal forces are mainly dispersed into the portion of the bone that is labial to the front teeth, leading to ischaemia and gradual atrophy of the alveolar ridge<sup>5-12</sup>. If this condition is left untreated, it can severely compromise the integrity of the entire periodontium and the stability of the teeth, ultimately leading to their loss and the consequent functional and aesthetic damage.

In order to restore both function and aesthetics in such cases of bone deficit, multiple surgical procedures are scheduled. In addition to being burdensome and uncomfortable for the patient, these procedures neither consent the immediate loading of implants nor the healing times before temporary prosthetics and definitive fixed prosthetics can be fitted.

Hence, we propose a minimally invasive alternative using one-piece, immediate-load, screw implants which consent rapid resolution of functional and aesthetic issues by means of a single surgical procedure<sup>13-18</sup>.

#### Materials and methods

This study conforms to the values laid down in the Declaration of Helsinki (1964). The protocol of this study has been approved by the relevant ethics committee associated to our institution in which it was performed. All subjects gave their informed consent to participate in this study.

One-piece, titanium, single-structure fixtures featuring an abutment of 2.5 mm and thread diameters of 3.5 mm and 4.5 mm, were implanted.

\* Corresponding author  
Email: francorossi020@gmail.com

<sup>1</sup> Private practice in Busto Arsizio (Varese) Italy

<sup>2</sup> Private practice in Milano, Italy

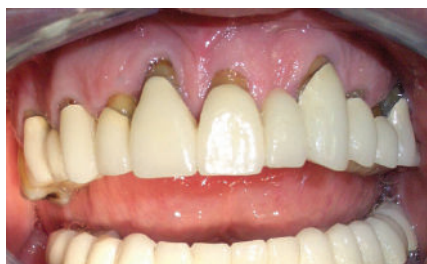<sup>3</sup> Department of D.M.C.C.C., Section of Maxillofacial and Plastic Surgery, University of Ferrara, Ferrara, Italy

<sup>4</sup> Private practice in Cuneo, Italy

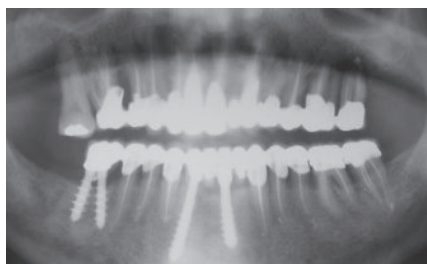
<sup>5</sup> Medical Director and Head of Radiology EO-SMED UO, Rome, Italy

<sup>6</sup> Private practice in Rome, Italy

<sup>7</sup> Department of Oral Science, Nano and Biotechnology, University 'G. D'Annunzio', Chieti, Italy

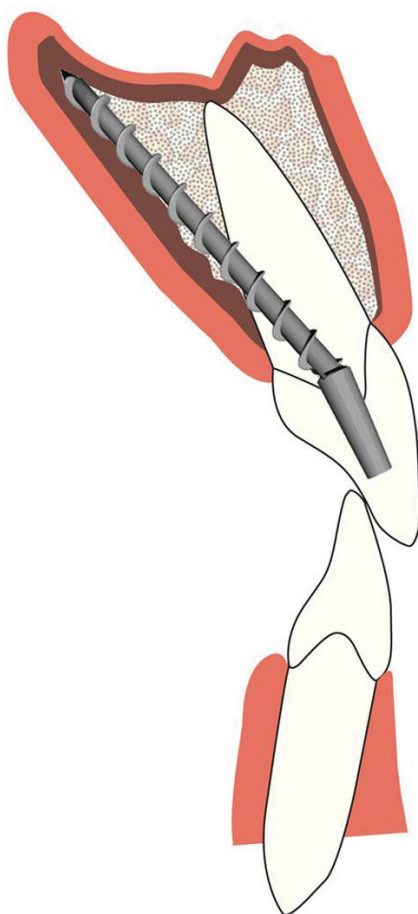


**Figure 1:** Bone loss, mucosal retraction and root exposure consequent to occlusal trauma.



**Figure 2:** Enlarged detail of upper jaw oral provocation test. Vertical and horizontal resorption is evident.

The wide diameter of the thread is the prime component of the proposed protocol as it confers good primary stability. Different implant lengths can be opted to suit the case so that the cortex of the nasal fossae is engaged (bicortical anchorage), as good anchorage—the second component of the protocol—is indispensable for primary stability. Splinting of the implants—the third component of the protocol—is performed by means of Mondani intraoral welding to a cylindrical supporter bar of 1.2 mm diameter resting on the palatal mucosa<sup>19-23</sup>. The implantation site is prepared with Pasqualini self-centring drills<sup>24,25</sup> of diameters increasing progressively up to 2.6 mm, starting with a 1.1 mm diameter probe drill, which is initially used to penetrate the cortex of the nasal fossae. After X-ray confirmation of the correct depth, the other self-centring drills are measured accordingly in order to complete the osteotomy, whose precision and minimal invasiveness is guaranteed by the



**Figure 3:** Direct implant by parallel insertion technique.

pyramidal cutting tip and bevelled triangular shank of the drills in question.

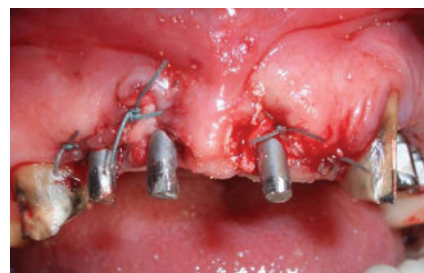Bone deficit filling is performed using porcine bone putty, and the heterologous implant is protected by placement of a lyophilised bovine pericardial membrane.

The implants are immediately loaded with acrylic resin crowns, prior to the fixture of definitive metal ceramic prostheses.

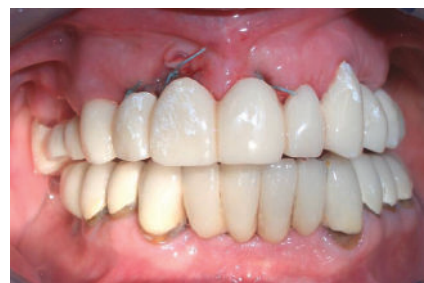## Results

### Case 1

We present the case of a 62-year-old male patient with visible exposure of the anterior teeth roots and bone loss as confirmed by the oral provocation test (Figures 1 and 2). Extraction of the teeth revealed severe



**Figure 4:** Three post-extraction implants were inserted. After their parallelisation, deficient bone was replaced using porcine bone putty and a protective bovine pericardial membrane.

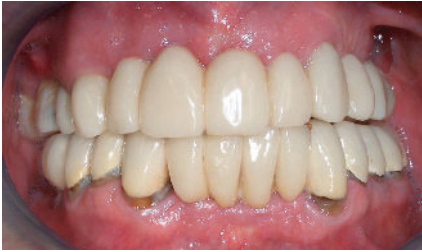

**Figure 5:** Immediate loading with temporary resin crowns; occlusal harmony upon completion of surgery.

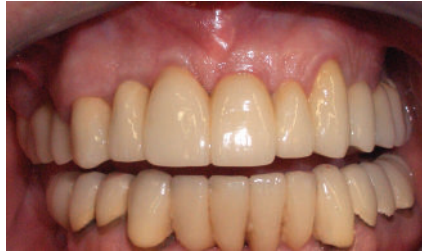alveolar bone deficit, particularly on the labial side. Insertion of the implants, without flap opening, was performed parallel and contiguous to the palatal cortical bone rather than following the natural direction of the alveolus (Figure 3). Because of the reduced dimensions of the abutment, the labial mucosa is not subjected to tension; in fact, it tends to collapse as it is no longer supported by the alveolar ridge. Therefore, it is possible to introduce the biomaterial filler and pericardial membrane without generating tension in the labial mucosa, which is an indispensable condition for complete aesthetic recovery (Figure 4).

According to our protocol, the implanted fixtures are splinted by intraoral welding to a titanium supporter bar in the same sitting<sup>26-28</sup>. At the end of this surgical phase, temporary resin crowns are

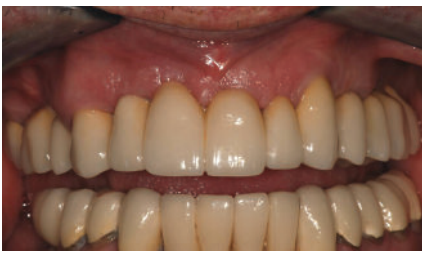



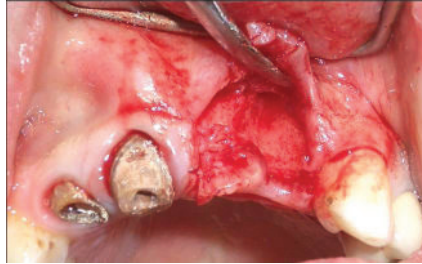
**Figure 6:** Mucosal healing after four months, without removing temporary crowns, and restored function and aesthetics.



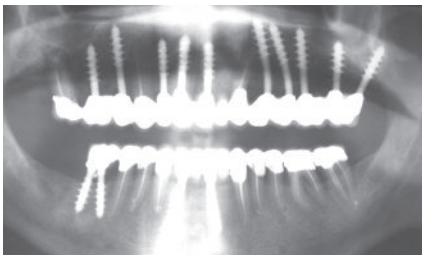
**Figure 10:** Five years of follow-up. The 'orange-peel' appearance of the mucosa.



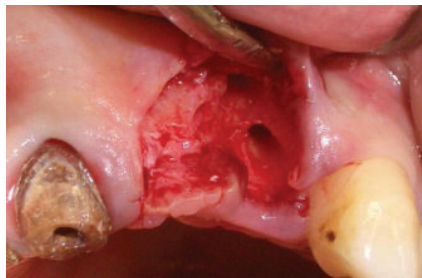**Figure 7:** Permanent metal/porcelain prosthesis.



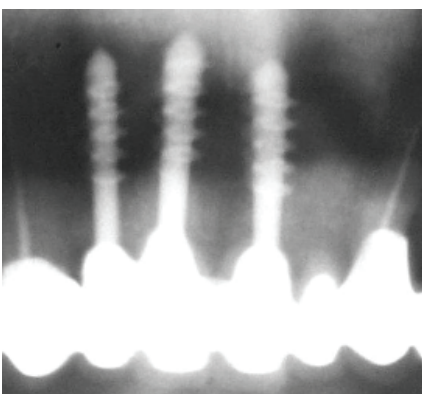
**Figure 11:** Evident severe labial bone loss.



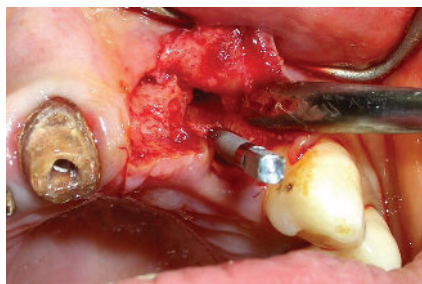
**Figure 8:** Final oral provocation test. Bone tissue healing is evident.



**Figure 12:** Osteotomy exploits the inclination of the palate rather than following the natural direction of the alveolus.



**Figure 9:** Detail of final oral provocation test. The reduced abutment dimensions do not preclude precise crown fitting.



**Figure 13:** Insertion of the post-extraction implant along the palatal cortex.

cemented in place, thereby achieving immediate loading in a single sitting (Figure 5).

The lack of labial tension generated using the described technique (without flap opening) accelerates the healing process and aesthetic recovery of the tissues (Figure 6), and the generation of the labial tension consents porcelain-fused-metal permanent crowns to be fitted without lengthy delays (Figures 7 and 8). Moreover, it is worthy to note that the small size of the abutments (2.5 mm) does not compromise the precision of the prosthetic crowns in any way (Figures 9 and 10).

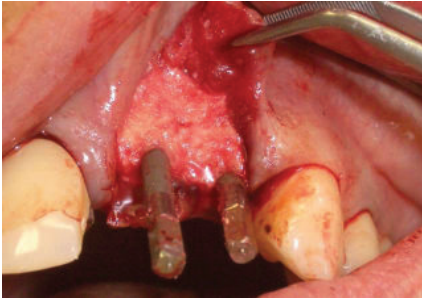
#### Case 2

We present the case of a 45-year-old female patient with a fractured left upper lateral incisor root that was used to support a gold/ceramic bridge. The patient's prosthesis, still fixed with temporary cement were removed this manoeuvre permitted recovery of, the crowns of teeth 11 and 12, which were not scheduled for replacement. After flap opening, extraction of the fractured root revealed a severe deficit of labial alveolar bone, extending almost to its apex (Figure 11).

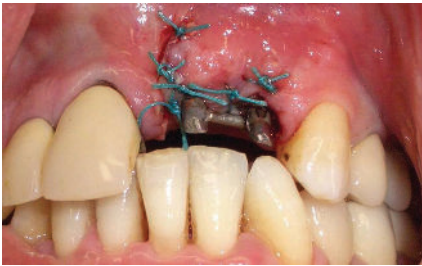
Osteotomy was performed according to the protocol described earlier by inserting the implant parallel and contiguous to the palatal cortical bone (Figures 12 and 13)<sup>29,30</sup> until the cortex of the nasal fossae was delicately engaged. Following the same procedure, a second implant was inserted into the edentulous space corresponding to the left central incisor, and the two implants were subsequently supported with a welded titanium bar splint.

The bone-deficient labial area was filled with porcine bone putty (Figure 14) and protected by means of a bovine pericardial membrane. At the end of the surgery, two temporary resin crowns were immediately cemented in place (Figures 15 and 16).

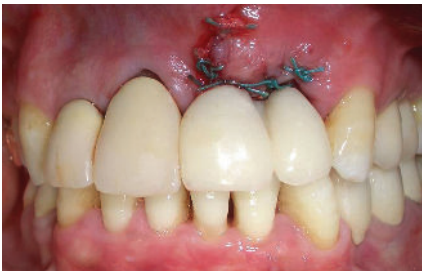Licensee OA Publishing London 2013. Creative Commons Attribution Licence (CC-BY)



**Figure 14:** Lost bone replaced with porcine bone putty.



**Figure 15:** Implants upon insertion, before immediate loading. Note welding to titanium supporter bar.



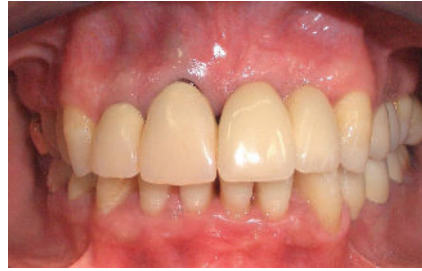**Figure 16:** Loading with temporary resin crowns immediately after surgery.

Rapid tissue healing consented permanent gold/porcelain crowns to be fitted after 90 days (Figures 17 and 18).

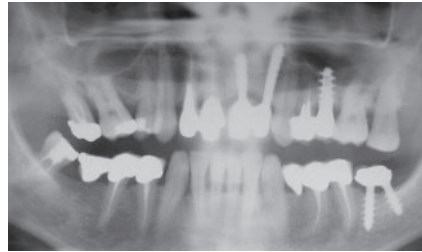
Six-year follow-up of the patient is shown in Figure 19.

### Discussion

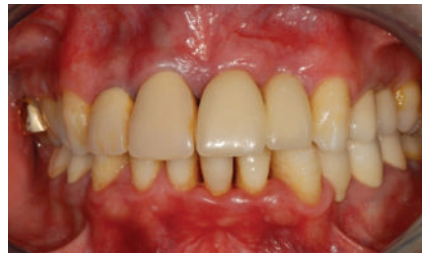Traumatic static occlusion of the upper anterior teeth can lead to progressive ischaemic atrophy of the labial portion of the alveolar bone because of the stress generated by transversal forces during swallowing. The treatment of choice for these



**Figure 17:** Definitive porcelain-fused-metal prosthesis.



**Figure 18:** Final oral provocation test.



**Figure 19:** Six years follow-up before scale and polish. Note the good appearance of the mucosa. Maintenance of occlusal harmony conditioned the spontaneous aesthetic recovery of the gingival border of the contiguous central incisor.

dystrophic, dysfunctional lesions consists of removing pre-contacts and restoring physiological occlusion. When the bone deficit occurs to an extent that the natural tooth must be removed, then this treatment procedure can be replaced by an implant. As an alternative to the techniques most commonly described in the published literature<sup>31-35</sup>, one-piece implants can be positioned exploiting the post-extraction edentulous spaces, which are often unusable with other types of implants without resorting

to more invasive surgical techniques and long healing times.

The biphasic implants should be positioned in the alveolus along the direction of the natural tooth root in cases of similar bone deficit; their threads would be exposed on the labial side, necessitating guided regeneration to be undertaken. This technique, despite its validity, does not always mean guarantee complete recovery of the lost bone. In fact, dehiscence can often occur at the top threads of the fixture, leading to unsightly exposure of the implant. However, this problem is rare in the use of one-piece implants and an appropriate surgical technique, i.e. the fixture (threaded shank) is inserted to a depth below the natural apex of the missing tooth, into the compact bone of the nasal fossae, leaving the abutment, with a uniform diameter of 2.5 mm, exposed. This can be immediately loaded with a temporary prosthesis, to be replaced by a permanent crown upon complete healing of the tissues, without the need for advanced planning.

One-piece implants are derived from Stefano Tramonte's titanium screws, which have been morphologically adapted for immediate loading<sup>36</sup>. Recent studies have demonstrated that abutments of smaller diameter than the fixture itself (platform switching), as in the case of one-piece screw implants, only rarely lead to crestal resorption. Despite their suitability for immediate loading, the incredible array of revolutionary implantation products entering the market has meant that one-piece screw implants have been rather overlooked. Nevertheless, we contend that because of their width and versatility with regards to the insertion technique, these implants remain useful. They guarantee good primary stability due to their insertion and parallelisation contiguous to the palatal cortex, thereby allowing them to adapt to the residual bone, and contrast transversal occlusal forces

Licensee OA Publishing London 2013. Creative Commons Attribution Licence (CC-BY)

**FOR CITATION PURPOSES:** Rossi F, Pasqualini ME, Carinci F, Meynardi F, Diotallevi P, Moglioni E, et al. 'One-piece' immediate-load post-extraction implants in labial bone-deficient upper jaws. *Annals of Oral & Maxillofacial Surgery* 2013 Apr 01;1(2):14.



and micromovements of over 150  $\mu$  that may compromise osteointegration<sup>37,38</sup>. Moreover, during dynamic mastication contacts, little strain will develop in the marginal labial bone, thereby limiting resorption and favouring bone remodelling.

### Conclusion

In cases of severely receding labial bone tissue in the upper anterior zones, the insertion of one-piece, post-extraction implants may be performed without the need to adhere to the direction of the root of the extracted tooth. Instead, according to the protocol proposed herein, insertion can be performed parallel and contiguous to the palatal cortical bone so as to engage the cortex of the nasal fossae. Inserted in this fashion, with the threaded shank completely embedded in the cortical bone, the implant is extremely stable and can therefore be immediately loaded without precluding bone regeneration procedures that exploit the lack of tension in the labial mucosa.

Using this protocol, extraction of compromised teeth, positioning of the implants, application of biomaterial and fixing of temporary crowns can be performed in one sitting, by means of a single surgical procedure, thereby substantially reducing the biological burden and patient discomfort. After a relatively short healing period, the permanent crowns can be fitted without further ado.

### References

- Pasqualini U. Le patologie occlusali: eziopatogenesi e terapia. Milan: Elsevier-Masson Milano Italy; 1993 Nov. p3-23, p176-92. Italian.
- Pasqualini U, Pasqualini ME. Treatise of Implant Dentistry. Carimate Como: AriesDue; 2009 Oct. p141-57. Italian.
- Meynardi F, Rossi F, Battaglio C, Biancotti PP, Pasqualini ME. Correlation between periodontal-peri-implant bacterial profile and abnormal occlusal loads. Doctor Os. 2011 Apr;22(4):341-5.
- Floris PL. Atlante di implantoprotesi. Cap. 12°: l'occlusione e il carico masticatorio nella protesi implantare. Rome: CIC Edizioni Internazionali; 2009 Nov. p169-212. Italian.
- Pasqualini U. Le patologie occlusali: eziopatogenesi e terapia. Milan: Elsevier-Masson Italy; 1993 Nov. p60-200. Italian.
- Glickman I. Occlusion and the periodontium. J Dent Res. 1967 Jan-Feb;46(1):53-9.
- Chasens A. The effect of traumatic occlusion on the periodontium and the associated structures and treatment by selective grinding of the natural dentition. Dent Clin North Am. 1962;6-63.
- Stallard RE. Occlusion: a factor in periodontal disease. Int Dent J. 1968 Mar;18(1):121-32.
- Asikainen P, Klemetti E, Vuillemin T, Sutter F, Rainio V, Kotilainen R. Titanium implants and lateral forces. An experimental study with sheep. Clin Oral Implants Res. 1997 Dec;8(6):465-8.
- Rinchuse DJ, Kandasamy S, Sciote J. A contemporary and evidence-based view of canine protected occlusion. Am J Orthod Dentofacial Orthop. 2007 Jul;132(1):90-102.
- Walton G, Heasman P. The role of occlusion in periodontal disease. Dent Update. 1998 Jun;25(5):209-10, 212-4, 216.
- Glaros AG, Williams K, Lausten L, Friesen LR. Tooth contact in patients with temporomandibular disorders. Cranio. 2005 Jul;23(3):188-93.
- Pasqualini U, Pasqualini ME. Treatise of Implant Dentistry. Carimate Como: AriesDue; 2009 Oct. p168-83.
- Pasqualini ME, Mangini F, Colombo D, Rossi F. Stabilisation of immediately loaded emerging implants: endoral soldering. Dent Cadmos. 2001;9:67-71. Italian.
- Rossi F, Pasqualini ME, Mangini F, Manenti P. Surgical protocol for immediate loading of monophasic implants in the upper jaw. Dent Cadmos. 2005;5:65-9. Italian.
- Bertele G, Pasqualini ME, Bilucaglia L, Mirandola A. Oral implantology: from hypothesis to immediate loading. Eur J Implant Prosthodont. 2005 May-Aug;(1):65-87.
- Mogliani E, Diotallevi P, Pezzuti E, Ferrante G, Pasqualini ME, Floris PL. Success rates in subject rehabilitated with immediate loading technique on according to AISI guide-lines. Annali di Stomatologia. 2008 Jul-Sep;LVI(1-2):19-23. Italian.
- Dal Carlo L. Il trattamento con impianti della zona degli incisivi inferiori. Implantologia protesicamente e anatomicamente guidata con viti in monoblocco. Doctor OS. 2011 Giu;22(6):635-47. Italian.
- Dal Carlo L. Tecnica di protesi fissa su barra saldata nelle contenzioni definitive. Doctor OS. 2004 Giu;15(6):637-45. Italian.
- Hruska AR. Intraoral welding of pure titanium. Quintessence Int. 1987 Oct;18(10):683-8.
- Hruska A, Borelli P, Bordanaro AC, Marzaduri E, Hruska KL. Immediate loading implants: a clinical report of 1301 implants. J Oral Implantol. 2002; 28(4): 200-9.
- Lorenzon G, Bigliardi C, Zanetti EM, Pertugio R. Analisi biomeccanica dei sistemi implantari. Dental Cadmos. 2003 Oct;10:63-86. Italian.
- Fanali S, Perrotti V, Riccardi L, Piatelli A, Piccirilli M, Ricci L, et al. Inflammatory infiltrate, microvessel density, vascular endothelial growth factor, nitric oxide synthase, and proliferative activity in soft tissues below intraorally welded titanium bars. J Periodontol. 2010 May;81(5):748-57.
- Bucci Sabatini V. Tecniche ricostruttive e rigenerative dei mascellari atrofici. I biomateriali: scelta, indicazioni e metodi di uso. TU.E.OR. 2007 Giu;284-8. Italian.
- Pasqualini U, Pasqualini ME. Treatise of Implant Dentistry. Carimate Como: AriesDue; 2009 Oct. p168-77. Italian.
- Degidi M, Gehrke P, Spanel A, Piatelli A. Syncrystallization: a technique for temporization of immediately loaded implants with metal-reinforced acrylic resin restorations. Clin Implant Dent Relat Res. 2006;8(3):123-34.
- Fanali S, Vannini F. Impianti bifasici solidarizzati con saldatrice endorale. Doctor OS. 2007 Nov-Dec;18(9):1047-56. Italian.
- orenzon G. Implantologia funzionale. Dalla osteointegrazione alla fisiointegrazione. Bologna Ed. Martina; 2010 Jan. p269-74. Italian.
- Rossi F. Impianti post estrattivi stabilizzati, a carico immediato e differito. Atti del Convegno di Implantologia "Impianti post-estrattivi. Passato, Presente, Futuro. Chieti. 2002 Giu;45-8. Italian.
- Floris PL. Atlante di implantoprotesi. Cap. 12°: L'occlusione e il carico masticatorio nella protesi implantare. Rome: CIC Edizioni Internazionali; 2009 Nov. p170-4. Italian.

Licensee OA Publishing London 2013. Creative Commons Attribution Licence (CC-BY)

**FOR CITATION PURPOSES:** Rossi F, Pasqualini ME, Carinci F, Meynardi F, Diotallevi P, Mogliani E, et al. 'One-piece' immediate-load post-extraction implants in labial bone-deficient upper jaws. Annals of Oral & Maxillofacial Surgery 2013 Apr 01;1(2):14.

## Original research study

31. Bianchi A. Implantologia e impianto-protesi. Turin: Utet; 1999. Mai. p111–65. Italian.
32. Caprioglio D, Pasqualini U. Treatment of dental agenesis in the child. *Av Odontostomatol.* 1989 May;5(5):299–304, 307–12, 314–5.
33. Muratori G. Implant isotopy (II). *J Oral Implantol.* 1995;21(1):46–51.
34. Garbaccio D. La vite autofilettante bicorticale: principio bio-meccanico, tecnica chirurgica e risultati clinici. *Dental Cadmos.* 1981 Giu;49(6):19–31. Italian.
35. Mondani PL, Mondani PM. La saldatrice elettrica intraorale di Mondani: principi, evoluzione e spiegazione della saldatura per sincristallizzazione. *Odonstom: Implantoprot.* 1982 Jul-Aug; (4):28–32. Italian.
36. Tramonte SM. L'impianto a vite autofilettante. *Riv It Implant.* 1966 Jan;1:95. Italian.
37. Szmukler-Moncler S, Salama H, Reingewirtz Y, Dubruille JH. Timing of loading and effect of micromotion on bone-dental implant interface: review of experimental literature. *J Biomed Mater Res.* 1998 Summer;43(2): 192–203.
38. Cameron HU, Pilliar RM, MacNab I. The effect of movement on the bonding of porous metal to bone. *J Biomed Mater Res.* 1973 Jul;7(4):301–11.

Licensee OA Publishing London 2013. Creative Commons Attribution Licence (CC-BY)

**FOR CITATION PURPOSES:** Rossi F, Pasqualini ME, Carinci F, Meynardi F, Diotallevi P, Moglioni E, et al. 'One-piece' immediate-load post-extraction implants in labial bone-deficient upper jaws. *Annals of Oral & Maxillofacial Surgery* 2013 Apr 01;1(2):14.