

PRESENT

FUTURE

PAST

Earn
3 CE credits
This course was written for dentists, dental hygienists, and assistants.

Past, Present, and Future of Narrow Diameter Implants

A Peer-Reviewed Publication
Written by Dr. Tera Greene

Abstract

Narrow diameter implants, mini-implants, small diameter implants, category 1 implants—whatever you choose to call implants defined as less than 3.0 mm in diameter—have been cleared by the Food and Drug Administration for a considerable period of time. They are indicated for several treatment modalities, including fixed prostheses, removable complete dentures, and temporization. They have been found to improve treatment acceptance, particularly where anatomical, financial, and/or medical challenges are present that otherwise impede conventional implant treatment.

Educational Objectives

During this course the participant will:

1. Recognize when to use a narrow diameter implant.
2. List and describe the clinical challenges that may limit implant treatment.
3. Expand treatment options to include more patients previously excluded from implant candidacy.
4. Gain insights on treatment presentation that will increase case acceptance.
5. Determine fact from fiction and debunk the myths surrounding narrow diameter implants.

Author Profile

Dr. Greene has always believed that without dental health, an individual is not healthy. Her practice Accure Dental & Dentures, Meridian, ID, offers extractions, dentures, partials, implants, and all forms of general dentistry. The practice makes its own brand of dentures in its onsite dental lab, providing custom dentures the same day as tooth extraction.

Author Disclosure

Dr. Greene has no commercial ties with the sponsors or the providers of the unrestricted educational grant for this course.

INSTANT EXAM CODE 15236

Go Green, Go Online to take your course

Publication date: Oct. 2017
Expiration date: Sep. 2020

Supplement to PennWell Publications

ADA CERP® Continuing Education Recognition Program

PennWell is an ADA CERP recognized provider. ADA CERP is a service of the American Dental Association to assist dental professionals in identifying quality providers of continuing dental education. ADA CERP does not approve or endorse individual courses or instructors, nor does it imply acceptance of credit hours by boards of dentistry.

Concerns or complaints about a CE provider may be directed to the provider or to ADA CERP at www.ada.org/goto/ceip.

PennWell designates this activity for 3 continuing educational credits.

Dental Board of California: Provider 4527, course registration number CA# 03-4527-15236
"This course meets the Dental Board of California's requirements for 3 units of continuing education."

The PennWell Corporation is designated as an Approved PACE Program Provider by the Academy of General Dentistry. The formal continuing dental education programs of this program provider are accepted by the AGD for Fellowship, Mastership and membership maintenance credit. Approval does not imply acceptance by a state or provincial board of dentistry or AGD endorsement. The current term of approval extends from (11/1/2015) to (10/31/2019) Provider ID# 320452.



This educational activity has been made possible through an unrestricted grant from Dentatus USA, LTD. **This course was written for dentists, dental hygienists and assistants, from novice to skilled.**

Educational Methods: This course is a self-instructional journal and web activity.

Provider Disclosure: PennWell does not have a leadership position or a commercial interest in any products or services discussed or shared in this educational activity nor with the commercial supporter. No manufacturer or third party has had any input into the development of course content.

Requirements for Successful Completion: To obtain 3 CE credits for this educational activity you must pay the required fee, review the material, complete the course evaluation and obtain a score of at least 70%.

CE Planner Disclosure: Heather Hodges, CE Coordinator does not have a leadership or commercial interest with products or services discussed in this educational activity. Heather can be reached at hhodges@pennwell.com

Educational Disclaimer: Completing a single continuing education course does not provide enough information to result in the participant being an expert in the field related to the course topic. It is a combination of many educational courses and clinical experience that allows the participant to develop skills and expertise.

Image Authenticity Statement: The images in this educational activity have not been altered.

Scientific Integrity Statement: Information shared in this CE course is developed from clinical research and represents the most current information available from evidence based dentistry.

Known Benefits and Limitations of the Data: The information presented in this educational activity is derived from the data and information contained in reference section. The research data is extensive and provides direct benefit to the patient and improvements in oral health.

Registration: The cost of this CE course is \$59.00 for 3 CE credits.

Cancellation/Refund Policy: Any participant who is not 100% satisfied with this course can request a full refund by contacting PennWell in writing.



Educational Objectives

The overall goal of this course is to provide the reader with information on the indications and use of narrow diameter implants. On completion of this article, the reader will be able to do the following:

1. Recognize when to use a narrow diameter implant.
2. List and describe the clinical challenges that may limit implant treatment.
3. Expand treatment options to include more patients previously excluded from implant candidacy.
4. Gain insights on treatment presentation that will increase case acceptance.
5. Determine fact from fiction and debunk the myths surrounding narrow diameter implants.

Abstract

Narrow diameter implants, mini-implants, small diameter implants, category 1 implants—whatever you choose to call implants defined as less than 3.0 mm in diameter—have been cleared by the Food and Drug Administration for a considerable period of time. They are indicated for several treatment modalities, including fixed prostheses, removable complete dentures, and temporization. They have been found to improve treatment acceptance, particularly where anatomical, financial, and/or medical challenges are present that otherwise impede conventional implant treatment.

There is a crucial gap between the numbers of patients who would benefit from implant treatment and the number of procedures that are performed. According to the American College of Prosthodontists, 178 million people in the United States are missing at least one tooth. And yet only 2.3 million implant-supported crowns are made annually.¹


Implant Breakthrough

In the early 1990s, Bernard Weissman understood why so many implant treatment plans did not receive case acceptance and summarized it in terms of time, bone, money, and fear of surgery. This drove him to develop the first narrow diameter implant that was 1.8 mm in diameter. It was a one-piece, self-threading implant designed for transitional use that would be placed at the same time of stage-one implant surgery, and was immediately loaded so that (1) patients never had to be without teeth, and (2) surgical sites would remain completely protected. This was an amazing breakthrough.

Questions then arose. How long would these narrow diameter implants last? Would they actually osseointegrate? Those questions were answered in 2004 when the FDA approved narrow diameter implants for “long-term use and for any length of time as decided by the health-care provider.”² Further, Dr. Stuart Froum, clinical professor and director of clinical research, Department of Periodontology and Implant Dentistry, New York University Dental Center, along with Dr. Michael Rohrer, Professor and Director of the Hard Tissue Research Laboratory, School of Den-

tistry, University of Minnesota, Department of Diagnostic and Biological Sciences, Division of Oral and Maxillofacial Pathology, et al. published a histology report concluding that “the percentage of bone to implant contact achieved with these implants was similar to that documented in the literature for conventional turned, screw-shaped, machine-surfaced implants.”³

The percentage of BIC achieved was similar to that documented in the literature for conventional turned, machine-surface implants



Histology of Dentatus Narrow Diameter Implants

Calls For Action

In November 2004, the American Dental Education Association (ADEA) called a special meeting of deans and industry representatives to review the status of implant dentistry in the curriculum. Two initiatives resulted from this meeting: (1) a call for use of a single implant to replace the three-unit bridge and prevent cutting virgin teeth, and (2) a two-implant overdenture should become the first choice of treatment for the edentulous mandible.⁴ The McGill Consensus statement reported overwhelming evidence in support of the two-implant overdenture.⁵ Jung, Lang, et al. deemed an implant-supported crown the evidence-based option of choice for replacement of a single anterior tooth with adjacent virgin teeth neighbors in an otherwise sound dentition.⁶ And yet, today there are still barriers to these levels of care.

In order to increase implant treatment acceptance, Dr. Avishai Sadan, former editor in chief of Quintessence International, urged dentists to focus on objective data rather than descriptive terms. “Patients described how the treatment plan for a three-unit fixed partial denture versus a single implant restoration was presented: ‘You are missing a tooth and it needs replacement. We can file down the teeth adjacent to the missing tooth and give you the bridge in about four weeks. Alternatively, we can drill a hole in your jaw, put a screw in there, and put a crown on that. This approach will take about a year.’ Even patients who did not want their teeth prepared for a fixed partial denture opted for that treatment plan because the hole in the head alternative was less appealing.”⁷

It is well documented and generally accepted today that if a tooth is missing, an implant is the option of choice. Just as important as the language we select in treatment presentation is the ability to offer multiple solutions within the field of implantology. The end goal is the same: we want our patients to benefit from the numerous advantages of implants with regard to function and preservation of bone and esthetics, irrespective of size or brand.

Many times narrow diameter implants can overcome patient objections because they address specific, and often overlapping, well-known concerns. They offer a minimally invasive, affordable solution that is within reach for most patients. They eliminate the need for a two-stage surgery and having to wait for their teeth. Another advantage of the narrow diameter implant is that flap surgery is often unnecessary and sutures are not needed.⁸

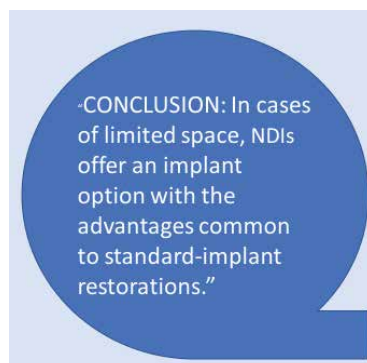
Turning Point

The right combination of factors—both technical and economical, among others—align to shift a product from that of a luxury to an everyday item. Today, the adoption of new products is happening at an increasingly rapid pace. Considering dental implants in this context, the trend toward this treatment becoming commonplace is clear.

We see medical practices redefining their roles. They are recognizing a broader societal responsibility to acknowledge the real value of health-care expenses and the treatment results. Thus, medical doctors are urged to consider the economic consequences of their decisions.⁹

Likewise, in dentistry, we recognize that a one-size-fits-all approach to implantology is no longer viable. Textbook dentistry—the gold-standard, top-of-the-line, A-one treatment plans—must adapt to circumstances to meet the needs of a larger patient population. The benefits of narrow diameter implants offer one such solution to overcoming obstacles relating to clinical, medical, emotional, and/or financial means.

Today, we see numerous authors reporting successful results when narrow diameter implants were used to support definitive prostheses.¹⁰⁻¹⁴ Bidra and Almas reported a 94.7% survival rate of narrow diameter implants when used exclusively for definitive prosthodontic treatment in a systematic review of literature in 2013.¹⁵ Sohrabi et al. also conducted a literature review and concluded “no significant difference in failure and complication rates between narrow body implants and standard-diameter implants.”¹⁶



Had a **survival rate** comparable to standard-diameter implants

Displayed **an annual bone loss** comparable to standard-diameter implants

Achieved favorable **esthetic results**²¹

Research shows that when used appropriately, narrow diameter implants offer a practical and predictable solution. As best explained by Dr. Dennis Tarnow, clinical professor of periodontology and director of implant education at Columbia School of Dental Medicine, “The bone does not know the dif-

ference between a 1 mm implant or a 9 mm implant. What matters is what you do on top of it.”¹⁷

Since their inception, narrow diameter implants—classified here as under 3.0 mm in diameter—have undergone advances in **material** (grade V Ti-alloy), **surface** (treated to increase surface area and improve osseointegration), and **prosthetic design** (screw-retained with abutment variety comparable to conventional implants), all working to improve the ease of use and success rates.

Increasing Access to Care

As it stands today, of the patient population that actually goes to the dentist, only 10% of those that could benefit from an implant actually proceed with treatment.¹⁸⁻²⁰

According to the American Academy of Implant Dentistry (AAID), the dental implant and prosthetic market in the US is projected to reach \$6.4 billion by 2018—a \$6.4 billion-dollar industry fueled by 10% of the population.²⁰ In order to maximize profits, a conventional implant company needs to add to their product offerings. We see that happening with the likes of grafting materials, new membranes, and the advent of digital dentistry, all of which are amazing advances making implantology more predictable and successful. But those advances add cost to the procedure and fail to address the 90% who go without treatment.

Narrow diameter implants are particularly effective where anatomical, financial, and medical challenges are present that otherwise impede conventional implant treatment.

Increasing Treatment Options

Because they require less overall intervention, often eliminate the need for bone grafting procedures, and greatly reduce the number of chairside visits, narrow diameter implants are quickly being recognized as one of the best additions to the armamentarium for dentists to treat patients who are missing one tooth or more. The high success rate of implants has also expanded treatment options for both dentists and patients.

Primarily, narrow diameter implants can be placed into anatomically challenging areas that would be contraindicated for standard diameter implants without site modification procedures—procedures that add to treatment time, overall cost, and morbidity, all of which can deter patients from dental implant therapy.

Advantages of Narrow Diameter Implants

Eliminate grafting
Often flapless technique
Immediately loaded restoration
Reduced chair time / number of visits
Cost effective
No preparation of adjacent teeth
Retrievability

Narrow Spaces

In areas of limited bone width, limited mesial-distal space, or converging roots, narrow diameter implants are an ideal solution. A narrow diameter implant makes it possible to maintain adequate bone dimensions and proper implant spacing without augmentation, as well as preserving the buccal plate, because less bone is prepared for the osteotomy. The tapered design facilitates the one-stage surgery and is more conducive to a minimally invasive, flapless implant placement. This eliminates many post-operative challenges and decreases patient post-op discomfort.

Narrow diameter implants avoid the need for preparation and/or reduction to the adjacent natural dentition. They allow patients who normally would have to proceed with a fixed bridge or resin-bonded bridge the option of dental implants. These patients include those with congenitally missing incisors, reduced interdental space following orthodontic movement, one or two missing mandibular incisors, or space collapse in the maxillary anterior area where orthodontic work was not considered a viable option.

A screw-retained abutment offers many prosthetic options and affords more flexibility for long-term maintenance. The restoration is retrievable and thus allows for repair or recoloring of the crown.

In a 14-year retrospective case series, Dr. Froum et al. reported an annual bone loss of <0.02 mm on narrow diameter implants, which is considerably less than that typically reported for standard diameter implants (.22-.80mm)²¹ due in part to the solid, one-piece implant design that eliminates the microgap, reducing crestal bone loss.

Overdentures

An implant-retained denture can sometimes be considered the preferred treatment method, as it can provide support in cases of facial collapse. Numerous authors show successful results using two to four implants to retain an overdenture, both in terms of implant survival and patient satisfaction.²²⁻²⁷ But oftentimes, anatomic limitations and resorbed ridges compromise the number of implants, length, and position.²⁸ Narrow diameter implant protocol recommends that four implants be placed between mental foramina, offering stabilization and cross-arch support and preventing rocking often seen with two-implant techniques.

In elderly patients with advanced medical issues or on anticoagulant therapy, the placement of more than one implant has been shown to have a statistically increased risk of complication.²⁹ Narrow diameter implants simplify the procedure for patients who are not candidates for conventional implants—a minimally invasive flapless surgery without bone augmentation results in little post-op bleeding and decreased pain. Narrow diameter implants also preserve the jaw structure, preventing atrophy from bone loss.

A University of Gothenburg study on narrow diameter implants for overdenture retention by Tomasi et al. noted positive patient-centered outcomes of 100% satisfaction and reduced treatment times for patients presenting with compromised health

conditions (61%) and not in a condition to receive conventional implant surgical treatment. For the other patients, economic restrictions (29%) and fear of surgical treatment (10%) were reasons to opt for narrow diameter implant treatment rather than conventional surgery.³⁰

Temporization

When narrow diameter implants are not considered for a long-term solution, they still present a valuable modality in supporting fixed provisional restorations. At times when bone grafting is necessary to place and restore an implant, narrow diameter implants can protect the augmented site with a fixed provisional restoration, offering a comfortable and acceptable solution as compared to a removable denture. Narrow diameter implants allow a patient to undergo lengthy treatments without ever losing function or suffering the embarrassment of having to go without teeth.

In some instances, the implants intended for provisionalization can be incorporated into the definitive prosthesis as well. In a case study with 11-year follow up, Froum, Misch, et al. found that “these implants achieve excellent osseointegration and may be used long term to support the definitive prosthesis when splinted to standard diameter implants.”³¹

Areas of Use

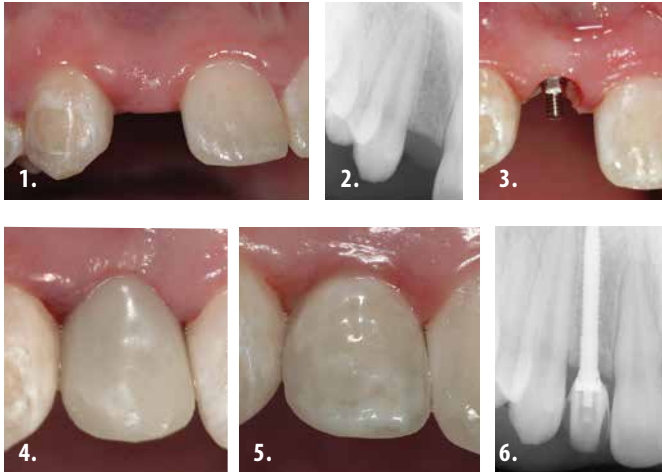
Single-tooth restorations	Congenitally missing laterals, converging roots, limited interdental space
Multi-unit bridges	Thin ridges
Immediate temporization	Protection of grafted sites, surgical guide stabilization, tissue architecture
Overdenture retention	Can later be converted to fixed restoration with Elypse coping

Case Studies

Limited interdental spaces

Case courtesy of Dr. Paul Petrunger, periodontist, Chicago, IL. Case originally appeared in *Inside Dentistry*, March 2006.

A 14-year-old nonsmoking girl presented for replacement of the congenitally missing right lateral incisor (tooth No. 7). The patient's orthodontic treatment had resulted in a compromised implant receptor site. Along with her parents, the patient refused any reduction of the virgin natural teeth, and did not accept the option of a resin-bonded bridge. The use of a removable prosthesis was contraindicated because of the patient's significant gag reflex. At the gingival level, the edentulous space measured 4.7 mm from the mesial of tooth No. 6 to the distal of tooth No. 8. Conventional implant dimensions were unacceptable to treat this compromised edentulous space. For these reasons, the Dentatus ANEW 2.4-mm x 14-mm implant was selected for placement, and the immediate provisionalization procedure was selected to allow the patient to have a nonremovable tooth option.



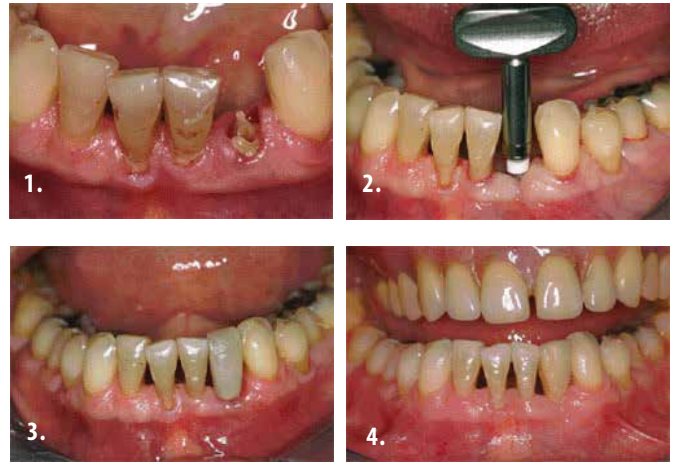
1. Preoperative view of the maxillary right lateral incisor space
2. Preoperative periapical radiograph
3. Placement of the Dentatus ANEW™ implant
4. The completed provisional restoration
5. The final implant-supported restoration
6. The digital periapical radiograph of the completed case

Long-term in patients unable to receive conventional implants

Case courtesy of Tommaso Ravasini, DMD, Parma, Italy. Case originally appeared in *Inside Dentistry*, Jul/Aug 2007.

A distraught 70-year-old female patient presented with a missing tooth. Her dentist assured the patient that her tooth could be replaced and presented the range of available treatment options. She could have a fixed bridge that would require cutting and preparing the healthy adjacent teeth, or she could replace her tooth with a Maryland-type bridge with extending wings that would be cemented to the lingual side of her adjacent teeth. The least appealing of the options was to make a removable tooth that would be held by friction and that might ultimately require a clasp design that would keep the removable more firmly in place. Because of her limiting bone and the restrictive space, the author recommended the more economical procedure for replacing her tooth with a porcelain crown supported by a narrow diameter implant (Dentatus ANEW). She ultimately selected to have her tooth replaced with a porcelain crown. She was much relieved to hear that the cost would be within her means and that this would be accomplished speedily within a few number of visits and in a painless manner.

Because of her limiting bone and the restrictive space, the author recommended the more economical procedure for replacing her tooth with a porcelain crown supported by a narrow diameter implant (Dentatus ANEW).

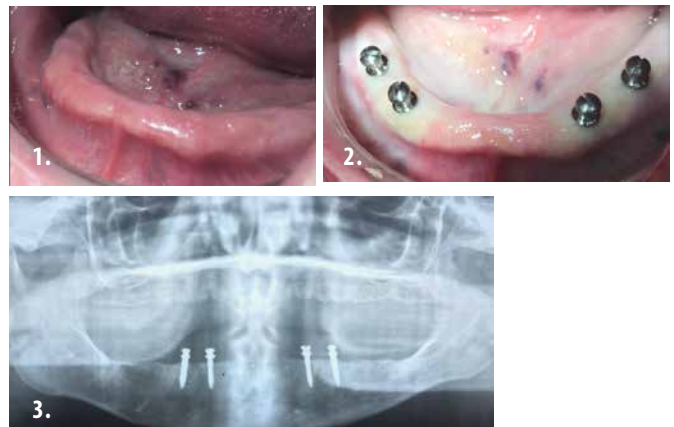

1. The root was extracted in a straight, upward motion and the area was allowed to mature and fully heal
2. The manual winged key was used to complete the installation
3. A temporary polycarbonate crown was selected to fit into the space
4. After osseointegration, the final crown was copied from the patient's fractured tooth

Overdentures in patients with anatomical limitations

Case courtesy of Dr. Tera Greene, Meridian, ID

A 54-year-old female presented with autoimmune hepatitis and was on heavy doses of prednisone, causing extreme dry mouth that resulted in teeth becoming grossly carious. The patient opted for full-mouth extractions and complete immediate dentures retained by four Dentatus Atlas implants; 2.2 x 10 mm was selected for both posterior implants and 1.8 x 10 mm for anterior implants. Dentatus implants were selected because the patient had a considerable anterior ridge undercut and the Tuf-Link silicone relines was ideal to regain her comfort.

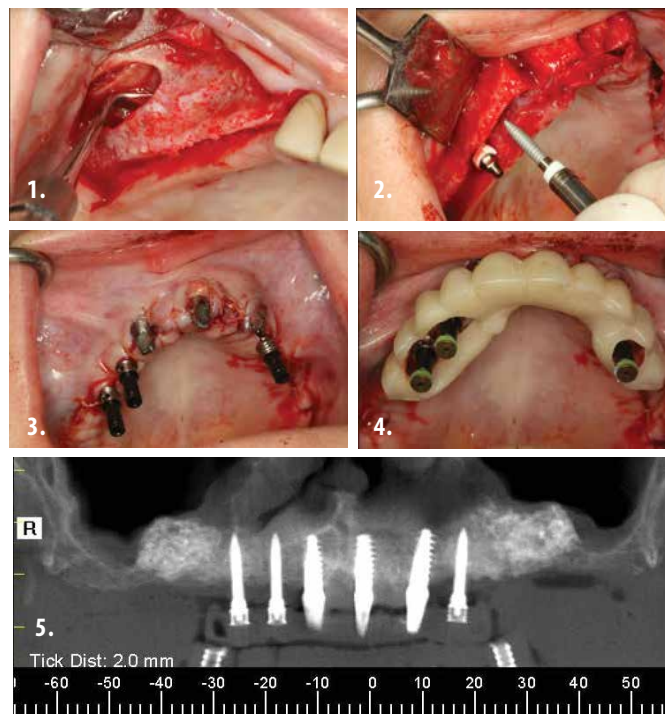


1. Considerable undercut in the anterior maxilla
2. Placement of four Atlas implants
3. Panorex of implants in place

Overdentures in patients with limited finances

Case courtesy of Paresh Shah, DMD, Winnipeg, Canada. Case originally appeared in *Oral Health*, July 2008.

A 76-year-old male presented with three remaining lower anterior teeth that required extractions. The teeth were non-salvageable. He had been wearing an ill-fitting partial denture for many years. His health was noncontributory except for one prophylactic aspirin tablet daily. His major complaint was a lower denture that was not secure enough to allow him to eat and speak properly. Several treatment options were presented including conventional implant placement (as the ideal scenario) or the option of a more conservative implant procedure utilizing narrow diameter implants with a minimally invasive surgical procedure. The patient selected to use narrow diameter implants due to cost, ease of placement, and the ability to function immediately.



1. Sinus lift and ridge augmentation
2. Placement of Dentatus ANEW implants
3. Prosthetic buildup for bridge
4. Components processed into bridge
5. CT scan of temporized bridge

Future Considerations

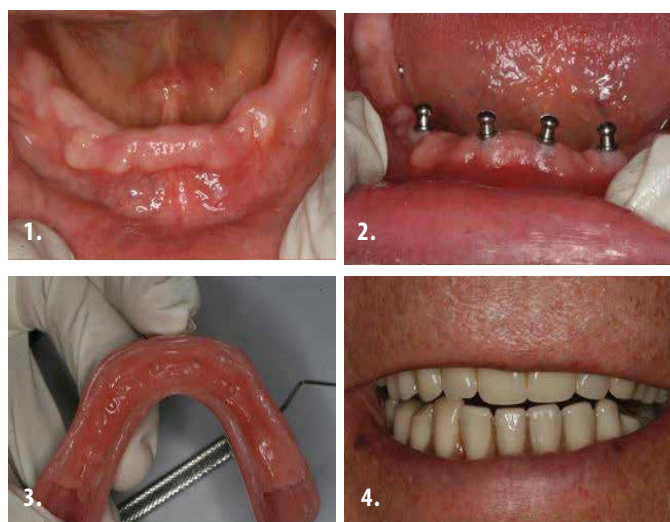
In recent years, we've seen an increased focus on health-care reform. In this economic climate and with the cost of health care constantly on the rise, dentists are rapidly becoming more proactive in considering alternative treatment modalities that offer solutions when patient objections limit access to care.

According to Dr. Carl Misch, there is an ever-increasing demand for dental implants resulting from the combined effects of several factors, most notably that our aging population is living longer and is more socially active.³²

With an increasingly aging population, higher costs of health care, and an overwhelming 90% of people rejecting implant treatment, it is time to embrace change to treat more patients with reliable, safe, and economical options.

Consider the social implications for seniors who look forward to meeting their friends for lunch or attending family celebrations—or even those at the opposite end of the spectrum—teens with congenitally missing laterals or sports injuries who are even more apt to feel self-conscious or excluded.

Education is essential. Even if dentists are not placing implants themselves, they need to recognize when implants should be recommended. For dentists looking to treat more patients, narrow diameter implants are an essential part of the implant armamentarium. Patients report overwhelmingly of their improved quality of life and express their appreciation for treatment that they once thought was impossible.



1. Edentulous ridge prior to implant surgery
2. All four implants placed in position without raising a flap
3. The denture base was prepared and retrofitted with the resilient Tuf-Link liner
4. Patient reported denture was comfortable and secure, and that he was able to speak and eat better than prior to treatment

Temporization during ridge augmentation

Case courtesy of Ziv Mazor, DMD Tel Aviv, Israel

A 55-year-old woman presented with severe ridge atrophy, needing bilateral ridge augmentations and sinus lifts. Postextraction treatment plan options were discussed with the patient during initial evaluation; a fixed implant-supported restoration was selected in order to achieve undisturbed healing and prevent migration of grafting material. Dentatus ANEW implants were selected as anchors for the temporary prosthesis due to the screw-retained feature, as the temporary bridge would need to be removed several times throughout treatment. 2.2 x 10 mm ANEW implants were inserted—two posteriorly on the right side and one anteriorly on the left, which securely held the temporary bridge in place.

Reach out to your patients—make available to them choices that make it easier for them to say “yes.” It won’t only make them feel good; it will make you feel good as well.

References

1. <https://www.gotoapro.org/facts-figures/>
2. Nats Corp. FDA Compliance; Endosseous Implants.; 2004.
3. Froum S, Simon H, Cho S, Elian N, Rohrer M, Tarnow D. Histologic evaluation of bone-implant contact of immediately loaded transitional implants after 6 to 27 months. *The International Journal of Oral & Maxillofacial Implants*. Volume 20, Number 1. 2005. 54-60.
4. Petropoulos VC, Arbree NS, Tarnow D, Rethman M, Malmquist J, Valachovic R, Brunson WD, Alfano MC. Teaching implant dentistry in the predoctoral curriculum: a report from the ADEA Implant Workshop's Survey of Deans. *Journal of Dental Education*. 2004. Vol 70, No 5: 580-588.
5. Feine JS, Carlsson GE, Awad MA, et al. McGill Consensus Statement on Overdentures. *The International Journal of Oral & Maxillofacial Implants*. Volume 17, Number 4. 2002. 601-602.
6. Jung RE, Pjetursson BE, Glauser R, Zembic A, Zwahlen M, Lang NP. A systematic review of the 5-year survival and complication rates of implant-supported single crowns. *Clin Oral Implants Res*. 2008. Feb;19(2):119-30. Epub 2007 Dec 7.
7. Sadan A. Editorial: Implant dentistry and the standard of care in dental education. *Quintessence International*. 2005. Vol 36; Number 6: 327.
8. Rossein K. Narrow-body implants preserve patients' quality of life. *Oral Health*. Aug. 2007. 39-44, 47-50.
9. Pollack A. Treatment cost could influence doctors' advice. *New York Times*. April 18, 2014:A1.
10. Vigolo P, Givani A. Clinical evaluation of single-tooth mini-implant restorations: a five-year retrospective study. *J Prosthet Dent*. 2000. 84(1):50-54.
11. Mazor Z, Steigmann M, Leshem R, Peleg M. Mini-implants to reconstruct missing teeth in severe ridge deficiency and small interdental space: a 5-year case series. *Implant Dent*. 2004. 13(4):336-341.
12. Froum SJ, Cho SC, Cho YS, et al. Narrow-diameter implants: a restorative option for limited interdental space. *Int J Periodontics Restorative Dent*. 2007. 27(5):449-455.
13. Shatkin TE, Petrotto CA. Mini dental implants: a retrospective analysis of 5640 implants placed over a 12-year period. *Compend Contin Educ Dent*. 2012. 33 spec 3:2-9.
14. Anitua E, Saracho J, Begoña L, Alkhraisat MH. Long-term follow-up of 2.5-mm narrow-diameter implants supporting a fixed prosthesis. *Clin Implant Dent Relat Res*. 2015. Apr 27. doi: 10.1111/cid.12350.
15. Bidra AS, Almas K. Mini implants for definitive prosthodontic treatment: a systematic review. *J Prosthet Dent*. 2013. 109(3):156-164.
16. Sohrobi K, Mushantat A, Esfandiari S, Feine J. How successful are small-diameter implants? A literature review. *Clin Oral Implants Res*. 2012. 23(5):515-25.
17. Tarnow D. Implants - High Cost, Low Cost and Everything in Between. 31st Annual AACD Scientific Session. San Francisco, CA. 2017.
18. Cole A. The top 50 European Manufacturers of Dental Implants (2nd Ed). Millenium Research Group. 2014.
19. Straumann proprietary survey 2010
20. American Academy of Implant Dentistry. Dental Implants Facts and Figures —

- AAID. aaidcom. 2017. Available at: http://www.aaid.com/about/Press_Room/Dental_Implants_FAQ.html. Accessed May 31, 2017.
21. Froum SJ, Shi Y, Fisselier F, Cho SC, et al. Long-term Retrospective Evaluation of Success of Narrow-diameter implants in Esthetic Areas: A Consecutive Case Series with 3 to 14 Years Follow-up. *Int J Periodontics Restorative Dent*. 2017. 37(5):629-637.
 22. Cho, S.C.; Froum, S.; Tai, C.H.; Cho, Y.S.; Elian, N.; Tarnow, D. "Immediate Loading of Narrow Diameter Implants in Severely Atrophic Mandibles" *Practical Procedures & Aesthetic Dentistry*, Vol. 19, No. 3, Apr. '07 pgs. 167-174
 23. Batenburg RHK, Meijer HJA, Raghoebar GM, Vissink A. Treatment concept for mandibular overdentures supported by endosseous implants: A literature review. *Int J Oral Maxillofac Impl*. 1998. 13(4):539-545.
 24. Mericske-Stern R, Schaffner TS, Marti P, Geering AH. Peri-implant mucosal aspects ITI implants supporting overdenture. *Clin Oral Impl Res*. 1994. 5(1):9-
 25. Heydenrijk K, Raghoebar GM, Meijer HJ, van der Reijden WA, van Winkelhoff AJ, Stegenga B. Two-stage IMZ implants and ITI implants inserted in a single-stage procedure. A prospective comparative study. *Clin Oral Implants Res*. 2002 Aug;13(4):371-80.
 26. Jemt T, Chai J, Harnett J, Heath MR, Hutton JE, Johns RB, et al. A 5-year prospective multicenter follow-up report on overdentures supported by osseointegrated implants. *Int J Oral Maxillofac Implants*. 1996 May-Jun;11(3):291-8.
 27. Naert, I., Gizani, S., Vuylsteke, M., & van Steenberghe, D. (1999). A 5-year prospective randomized clinical trial on the influence of splinted and unsplinted oral implants retaining a mandibular overdenture: Prosthetic aspects and patient satisfaction. *Journal of Oral Rehabilitation*, 26, 195-202.
 28. Sadowsky SJ (2001) Mandibular implant-retained overdentures: A literature review. *J Prosthet Dent* 86:468-473.
 29. Smith RA, Berger R. Risk factors associated with dental implants in healthy and medically compromised patients. *Int J Oral Maxillofac Impl* 1992;7(3):367-372
 30. Tomasi C, Idmyr BO, Wennstrom JL. Patient satisfaction with mini-implant stabilised full dentures. A 1-year prospective study. *Journal of Oral Rehabilitation*. 2013. 3.
 31. Froum S, Cho SC, Florio S, Misch C. Use of narrow-diameter implants in treatment of severely atrophic maxillary anterior region with implant-supported fixed restorations. *Compendium*. Volume 37, Issue 5, May 2016.
 32. Misch CE. *Dental Implant Prosthetics*, 2nd Edition.

Author Profile

Dr. Tera Greene has always believed that without dental health, an individual is not healthy. Her practice Accure Dental & Dentures, Meridian, ID, offers extractions, dentures, partials, implants, and all forms of general dentistry. The practice makes its own brand of dentures in its onsite dental lab, providing custom dentures the same day as tooth extraction.

Author Disclosure

Dr. Tera Greene has no commercial ties with the sponsors or the providers of the unrestricted educational grant for this course.

Online Completion **INSTANT EXAM CODE 15236**

Use this page to review the questions and answers. Return to www.DentalAcademyOfCE.com and sign in. If you have not previously purchased the program select it from the "Online Courses" listing and complete the online purchase. Once purchased the exam will be added to your Archives page where a Take Exam link will be provided. Click on the "Take Exam" link, complete all the program questions and submit your answers. An immediate grade report will be provided and upon receiving a passing grade your "Verification Form" will be provided immediately for viewing and/or printing. Verification Forms can be viewed and/or printed anytime in the future by returning to the site, sign in and return to your Archives Page.

Questions

1. Narrow diameter implants are defined as implants:
 - a. less than 3.0mm in diameter
 - b. between 3-3.5mm in diameter
 - c. 1.8mm diameter implants
 - d. above 4.0mm in diameter
2. Narrow diameter implants are indicated for:
 - a. fixed prostheses
 - b. removable dentures
 - c. temporization
 - d. all of the above
3. The first narrow diameter implant was:
 - a. 1.0mm diameter
 - b. 1.8mm diameter
 - c. 2.0mm diameter
 - d. 2.8mm diameter
4. Narrow diameter implants are FDA approved for:
 - a. temporization
 - b. long-term use or any length of time
 - c. 20 years
 - d. none of the above
5. According to the American College of Prosthodontics _____ people in the United States are missing at least 1 tooth:
 - a. 1 million
 - b. 2.3 million
 - c. 178 million
 - d. 248 million
6. Narrow diameter implants are:
 - a. immediately loaded
 - b. out of occlusion
 - c. allow patients to never be without teeth
 - d. all of the above

Questions- Continued

7. What drove the need to develop the first narrow diameter implant:
- patients never had to be without teeth
 - surgical sites would remain completely protected
 - both a & b
 - neither a nor b
8. A 2004 ADEA initiative called for use of a single implant to replace a 3-unit bridge and
- prevent cutting virgin teeth
 - reduce lab fees
 - increase fees
 - none of the above
9. According to Jung & Lang et al, this is the evidence-based option of choice for replacement of a single anterior tooth with adjacent virgin teeth:
- an implant
 - a bridge
 - a flipper
 - none of the above
10. The bone to implant contact achieved with narrow diameter implants is:
- less than seen with conventional implants
 - on par with conventional implants
 - more than seen with conventional implants
 - has not been tested
11. The one-size fits all approach to dentistry is:
- becoming mainstream
 - the only way to practice
 - the approach of choice
 - no longer viable
12. Bidra and Almas reported ___ survival rate in a 2013 review of literature:
- 92.3%
 - 93.7%
 - 94.7%
 - 95.5%
13. What percentage of patients who visit the dentist, and are candidates for implant treatment, actually proceed with treatment:
- 90%
 - 75%
 - 10%
 - none
14. Narrow diameter implants may eliminate the need for:
- reflecting a full flap
 - bone grafting
 - to fabricate a Maryland bridge
 - all of the above
15. Narrow diameter implants are particularly effective where _____ challenges are present that otherwise impede treatment:
- medical
 - financial
 - anatomical
 - all of the above
16. Narrow diameter implants are indicated for use in:
- congenitally missing laterals
 - where there is reduced interdental space
 - converging roots
 - all of the above
17. In a 14-year retrospective case series, Dr. Froum et al. reported an annual bone loss of <0.02 mm on narrow diameter implants, which is considerably _____ that typically reported for standard diameter implants.
- less than
 - more than
 - exactly the same as
 - on par
18. An implant retained overdenture can sometimes be _____ as it can provide support in cases of facial collapse
- considered for treatment
 - considered the preferred treatment method
 - rejected as a treatment option
 - none of the above
19. Tomasi's narrow diameter implant study on overdenture retention at the University of Gothenburg noted:
- patients with medical conditions were not ideal candidates
 - financial constraints are never a consideration
 - all patients treated were very satisfied
 - fear of surgery is not a factor in treatment acceptance
20. Narrow diameter implants simplify the procedure for patients who are not candidates for conventional implants because
- it's a minimally invasive flapless surgery
 - doesn't require bone augmentation
 - results in little post-op bleeding and decreased pain.
 - all of the above
21. A minimally invasive flapless surgery without bone augmentation results in:
- a lot of post-op bleeding
 - little post-op bleeding & decreased pain
 - no post-op bleeding
 - a lot of pain
22. Narrow diameter implants offer a _____ & _____ solution that is within reach for most patients:
- invasive & expensive
 - invasive & affordable
 - minimally invasive & affordable
 - minimally invasive & expensive
23. When narrow-diameter implants are not considered for a long-term solution, they
- still can be used to support a fixed provisional restoration
 - shouldn't be used at all
 - should only be used for dentures
 - none of the above
24. With implants patient benefits include:
- function
 - preservation of bone
 - esthetics
 - all of the above
25. In recent years there is increased focus on healthcare reform and dentists are
- more proactive in alternative treatment modalities
 - attending more CE courses
 - sticking to what they know
 - referring out patients
26. There is ever increasing demand for dental implants most notably because:
- our aging population is living longer & more socially active
 - our aging population has more disposable income
 - our aging population is on social media
 - none of the above
27. As a temporary solution, narrow diameter implants are:
- comfortable and acceptable solution as compared to removable dentures
 - require more maintenance than removable dentures
 - uncomfortable and unacceptable solution as compared to removable dentures
 - none of the above
28. Narrow diameter implants allow patients to undergo lengthy treatments without:
- losing function
 - suffering embarrassment
 - both a and b
 - neither a nor b
29. Narrow diameter implants
- can be incorporated into a definitive prosthesis
 - should never be incorporated into a definitive prosthesis
 - must be evaluated
 - none of the above
30. Narrow diameter implants improve:
- treatment acceptance
 - patient comfort
 - neither a nor b
 - both a and b

Past, Present, and Future of Narrow Diameter Implants

Name: _____ Title: _____ Specialty: _____

Address: _____ E-mail: _____

City: _____ State: _____ ZIP: _____ Country: _____

Telephone: Home (_____) Office (_____)

Lic. Renewal Date: _____ AGD Member ID: _____

Requirements for successful completion of the course and to obtain dental continuing education credits: 1) Read the entire course. 2) Complete all information above. 3) Complete answer sheets in either pen or pencil. 4) Mark only one answer for each question. 5) A score of 70% on this test will earn you 3 CE credits. 6) Complete the Course Evaluation below. 7) Make check payable to PennWell Corp. **For Questions Call 800-633-1681**

Educational Objectives

1. Recognize when to use a narrow diameter implant.
2. List and describe the clinical challenges that may limit implant treatment.
3. Expand treatment options to include more patients previously excluded from implant candidacy.
4. Gain insights on treatment presentation that will increase case acceptance.
5. Determine fact from fiction and debunk the myths surrounding narrow diameter implants.

Course Evaluation

1. Were the individual course objectives met?

Objective #1: Yes No Objective #2: Yes No Objective #3: Yes No

Objective #4: Yes No Objective #5: Yes No

Please evaluate this course by responding to the following statements, using a scale of Excellent = 5 to Poor = 0.

- | | | | | | | |
|---|-------|---|---|---|-----|----|
| 2. To what extent were the course objectives accomplished overall? | 5 | 4 | 3 | 2 | 1 | 0 |
| 3. Please rate your personal mastery of the course objectives. | 5 | 4 | 3 | 2 | 1 | 0 |
| 4. How would you rate the objectives and educational methods? | 5 | 4 | 3 | 2 | 1 | 0 |
| 5. How do you rate the author's grasp of the topic? | 5 | 4 | 3 | 2 | 1 | 0 |
| 6. Please rate the instructor's effectiveness. | 5 | 4 | 3 | 2 | 1 | 0 |
| 7. Was the overall administration of the course effective? | 5 | 4 | 3 | 2 | 1 | 0 |
| 8. Please rate the usefulness and clinical applicability of this course. | 5 | 4 | 3 | 2 | 1 | 0 |
| 9. Please rate the usefulness of the supplemental webliography. | 5 | 4 | 3 | 2 | 1 | 0 |
| 10. Do you feel that the references were adequate? | | | | | Yes | No |
| 11. Would you participate in a similar program on a different topic? | | | | | Yes | No |
| 12. If any of the continuing education questions were unclear or ambiguous, please list them. | _____ | | | | | |
| 13. Was there any subject matter you found confusing? Please describe. | _____ | | | | | |
| 14. How long did it take you to complete this course? | _____ | | | | | |
| 15. What additional continuing dental education topics would you like to see? | _____ | | | | | |

If not taking online, mail completed answer sheet to
PennWell Corp.
 Attn: Dental Division,
 1421 S. Sheridan Rd., Tulsa, OK, 74112
 or fax to: 918-831-9804

**For IMMEDIATE results,
 go to www.DentalAcademyOfCE.com to take tests online.**

INSTANT EXAM CODE 15236

**Answer sheets can be faxed with credit card payment to
 918-831-9804.**

Payment of \$59.00 is enclosed.
(Checks and credit cards are accepted.)

If paying by credit card, please complete the following: MC Visa AmEx Discover

Acct. Number: _____

Exp. Date: _____

Charges on your statement will show up as PennWell

- | | |
|---------------------|---------------------|
| 1. (A) (B) (C) (D) | 16. (A) (B) (C) (D) |
| 2. (A) (B) (C) (D) | 17. (A) (B) (C) (D) |
| 3. (A) (B) (C) (D) | 18. (A) (B) (C) (D) |
| 4. (A) (B) (C) (D) | 19. (A) (B) (C) (D) |
| 5. (A) (B) (C) (D) | 20. (A) (B) (C) (D) |
| 6. (A) (B) (C) (D) | 21. (A) (B) (C) (D) |
| 7. (A) (B) (C) (D) | 22. (A) (B) (C) (D) |
| 8. (A) (B) (C) (D) | 23. (A) (B) (C) (D) |
| 9. (A) (B) (C) (D) | 24. (A) (B) (C) (D) |
| 10. (A) (B) (C) (D) | 25. (A) (B) (C) (D) |
| 11. (A) (B) (C) (D) | 26. (A) (B) (C) (D) |
| 12. (A) (B) (C) (D) | 27. (A) (B) (C) (D) |
| 13. (A) (B) (C) (D) | 28. (A) (B) (C) (D) |
| 14. (A) (B) (C) (D) | 29. (A) (B) (C) (D) |
| 15. (A) (B) (C) (D) | 30. (A) (B) (C) (D) |

AGD Code 690

PLEASE PHOTOCOPY ANSWER SHEET FOR ADDITIONAL PARTICIPANTS.

COURSE EVALUATION and PARTICIPANT FEEDBACK
 We encourage participant feedback pertaining to all courses. Please be sure to complete the survey included with the course. Please e-mail all questions to: htodges@pennwell.com.

INSTRUCTIONS
 All questions should have only one answer. Grading of this examination is done manually. Participants will receive confirmation of passing by receipt of a verification form. Verification of Participation forms will be mailed within two weeks after taking an examination.

COURSE CREDITS/COST
 All participants scoring at least 70% on the examination will receive a verification form verifying 3 CE credits. The formal continuing education program of this sponsor is accepted by the AGD for Fellowship/Mastership credit. Please contact PennWell for current term of acceptance. Participants are urged to contact their state dental boards for continuing education requirements. PennWell is a California Provider. The California Provider number is 4527. The cost for courses ranges from \$20.00 to \$110.00.

PROVIDER INFORMATION
 PennWell is an ADA CERP Recognized Provider. ADA CERP is a service of the American Dental Association to assist dental professionals in identifying quality providers of continuing dental education. ADA CERP does not approve or endorse individual courses or instructors, nor does it imply acceptance of credit hours by boards of dentistry.

Concerns or complaints about a CE Provider may be directed to the provider or to ADA CERP at www.ada.org/cotocerp/

The PennWell Corporation is designated as an Approved PACE Program Provider by the Academy of General Dentistry. The formal continuing dental education programs of this program provider are accepted by the AGD for Fellowship, Mastership and membership maintenance credit. Approval does not imply acceptance by a state or provincial board of dentistry or AGD endorsement. The current term of approval extends from (11/1/2015) to (10/31/2019) Provider ID# 320452

RECORD KEEPING
 PennWell maintains records of your successful completion of any exam for a minimum of six years. Please contact our offices for a copy of your continuing education credits report. This report, which will list all credits earned to date, will be generated and mailed to you within five business days of receipt.

Completing a single continuing education course does not provide enough information to give the participant the feeling that s/he is an expert in the field related to the course topic. It is a combination of many educational courses and clinical experience that allows the participant to develop skills and expertise.

CANCELLATION/REFUND POLICY
 Any participant who is not 100% satisfied with this course can request a full refund by contacting PennWell in writing.

IMAGE AUTHENTICITY
 The images provided and included in this course have not been altered.

© 2017 by the Academy of Dental Therapeutics and Stomatology, a division of PennWell

NDI1710DIG



When Choosing a NARROW DIAMETER IMPLANT, Listen to the Most Trusted Names in Implantology

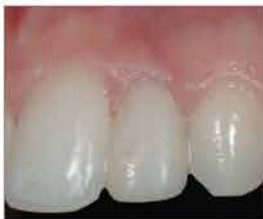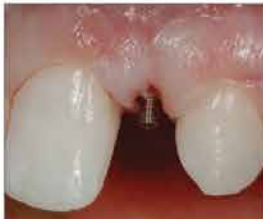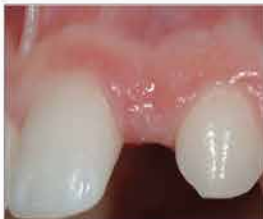Since first appearing in the dental marketplace 20 years ago, narrow diameter implants have fought an uphill battle to be accepted as a "real implant". Fast track to 2016 and you'll find research supporting safe and effective use. **Dentatus®** has proven that there is a place for the narrow diameter in implant dentistry with overwhelming publication and clinical references substantiating long term success. As best explained by Dr. Dennis Tarnow, "The bone does not know the difference between a 1mm implant or a 9mm implant. What matters is what you do on top of it."

Imagine that you can now offer treatment to patients whose ridges are worn thin, without building bone. Or that you can replace missing teeth where there is limited interdental space. What about those teenagers who struggle with their self-esteem during high school years due to congenitally missing laterals? Or the elderly, who worry about the time and cost for treatment?

Dentatus ANEW® narrow diameter implants afford dentists the possibility of treating more patients than ever before; everyday patients who are the backbone of your practice; patients with real life concerns who want and are deserving of teeth just like their very own.

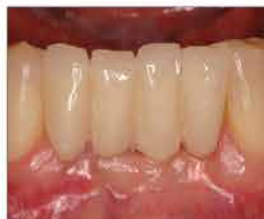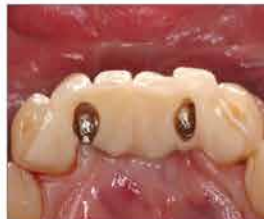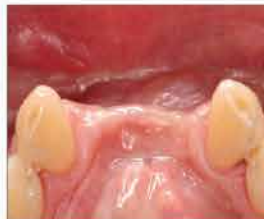Only **Dentatus** offers a narrow diameter implant system that can grow with you: from overdentures, to single tooth, to full mouth reconstruction. Whether you place implants yourself or refer them to a specialist, **Dentatus ANEW** offers the versatility to ensure that your patients can benefit from the treatment they deserve.

MISSING LATERALS



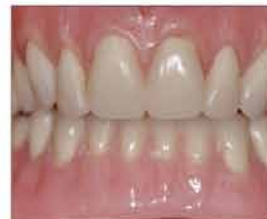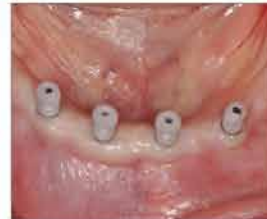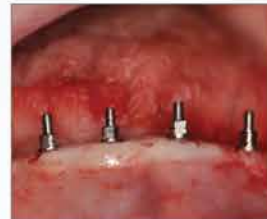Courtesy Dr. Stuart Froum, 1999

THIN RIDGES & DEFECTS



Courtesy Dr. Sang-Choon Cho, 2002

OVERDENTURES



Courtesy Dr. Mark Iacobelli, 2010

(800) 323-3136

dentatususa.com

