

See discussions, stats, and author profiles for this publication at: <https://www.researchgate.net/publication/279801706>

Minimally invasive implant therapy in geriatric patients using small diameter implants

Article · September 2011

CITATION

1

READS

154

2 authors:



Andrea Mascolo

Universidade Fernando Pessoa

32 PUBLICATIONS 82 CITATIONS

[SEE PROFILE](#)



Paresh Patel

AAID

7 PUBLICATIONS 6 CITATIONS

[SEE PROFILE](#)

Some of the authors of this publication are also working on these related projects:



full arch immediate loading [View project](#)

Minimally invasive implant therapy in geriatric patients using small diameter implants

Drs. Paresh B. Patel and Andrea Mascolo explore the benefits of mini dental implants for senior patients

Introduction

Several studies demonstrate high implant survival rates, a relatively low need for recurrent care, and improved quality of patients' lives. This modality is an accepted treatment option for all ages.^{1,2} Consequently, implant-supported prosthodontic rehabilitation for function and esthetics is indicated more frequently.

The aging population is growing, and these older adults have more teeth and more oral problems than previous generations. In 1900, 4% of the population was 65 years or older; by 2005, that number had increased to 12.4%, a 10-fold increase.³ It is expected by 2030 that some 70 million Americans will be over the age of 65, and many will have osteoporosis, diabetes, heart disease, and other health problems. All of these issues may pose challenges for implant dentists by making treatment decisions more difficult and complex.

In 2007, the American Academy of Implant Dentistry stated that as the population ages, dentists will see an increase in the number of elderly patients seeking dental implants. New solutions to combat these complex medical conditions in the geriatric population will be required.

Minimally invasive surgical procedures, applied to implantology, could play a key role in the treatment of this population. This concept of reduced surgery can be facilitated by the use of CBCT, surgical guides, and flapless procedures.

Mini dental implants are easy to place and can be used for a variety of prosthetics.⁴ Originally introduced 15 years ago to stabilize dentures, they now have been used in several other clinical applications, such as successfully restoring missing teeth with single or multiple-unit, splinted,

fixed-partial dentures (FPDs).

The procedure for mini-implant placement is typically flapless, and requires less surgery than traditional implant protocols. With less surgery, the reported complications are extremely low.⁵ Other advantages include that systemic contraindications are greatly reduced. Patients with controlled diabetes, autoimmune disorders, osteoporosis, and cigarette use can now be considered for implant therapy. This could include geriatric patients, patients with anxiety, dental phobias, and patients with bleeding disorders.

Evidence shows that mini implants have excellent results with a 5-year and 7-year overall survival rate of more than 90%.^{6,7} It is expected that number will increase as correct placement protocols are established.

A recent literature review highlights that primary stability is a prerequisite for long-term success.^{8,9} If functional loads are correctly managed, secondary stability will occur, and osseointegration will be maintained.¹⁷

Bone quality is another important factor in determining the predictability of long-term success with mini dental implants. Type I and Type II bone are required for immediate loading and reduced healing times. Type III bone requires increased healing time and great care when applying functional load. Type IV bone is contraindicated for this procedure.^{6,7,10-12} The minimum number of mini implants required for appropriate retention of a complete removable denture may be six in the maxilla and four in the mandible.^{6,9,13,14}

The protocol for the restoration of anterior teeth should be one mini implant for each tooth. In the posterior region, two mini implants should

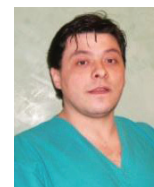be used to increase the implant-to-bone surface area when considering a fixed crown. All prostheses, fixed or removable, require a careful analysis of the occlusion to minimize and reduce axial forces.^{6,7,12,15,16}

The proposed protocols for mini-implant prostheses require a greater number of implants than conventional techniques, and a more accurate assessment of the position and angles to better distribute occlusal forces.

A rehabilitation of the upper arch, for example, would include six mini implants to support a full denture while 10-12 mini implants are recommended for a fixed solution. Splinting the superstructure in the fixed prosthesis results in a reduction of micromovement when load is applied. According to the literature, this micromovement is responsible for



Paresh B. Patel, DDS, graduated from the University of North Carolina-Chapel Hill School of Dentistry in 1996. He has a Mastership in the International Academy of Mini Dental Implants (IAOMDI), and is a founding member and on the editorial board of the *Journal of the International Academy of Mini Dental Implants*. Dr. Patel is vice president of the Iredell County Dental Society. He is also a 2009 graduate of the American Academy of Implant Dentistry Maxi Course, Medical College of Georgia. Dr. Patel is a past guest lecturer for Shatkin FIRST and lecturer for OCO Biomedical on mini dental implants. He practices in Mooresville, NC.



Andrea Mascolo, DDS, has a Masters in Oral Surgery from the University of Pisa. She is qualified for Implantology, Brånemark Clinic, Gothenburg, and attended the Summer School Clinical Implantology Periodontology, at the University of Heidelberg. He is founder and an active member of the Computer Aided Implantology (CAI) Academy; and has been a Professor at the University of Genoa since 2001. He is a speaker and author in Italy and abroad, and an international peer reviewer. He maintains a private practice in Novi Ligure, Italy; devoted to minimally invasive surgical procedures on special needs, is UK registered, and is an expert in periodontics and implantology in private clinics in the UK.

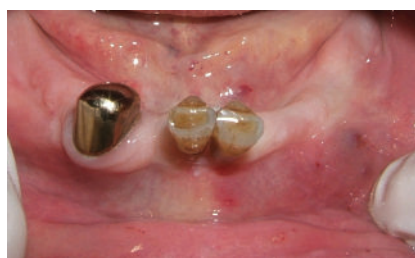

Figure 1: Initial situation, before surgery

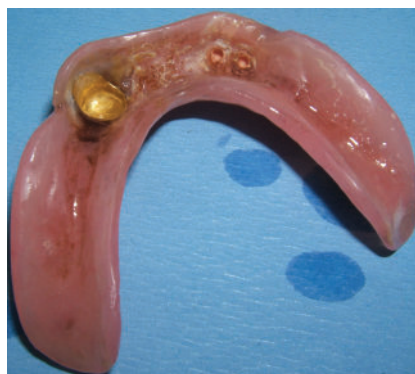

Figure 4: Prosthetic re-evaluation after 2 years

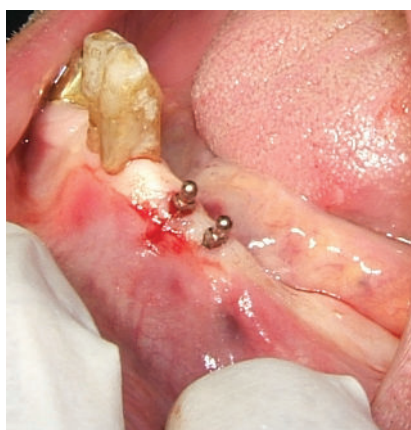

Figure 2: Mini implants placed, no bleeding

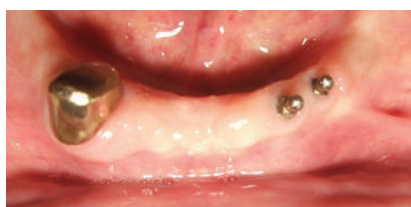

Figure 5: 2-year clinical re-evaluation

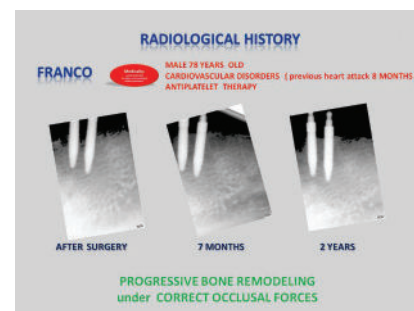


Figure 3: Radiological step: bone remodeling, occlusal effects of load

failure in immediate loading.²⁰

Several studies demonstrate the long-term success of full-arch fixed prostheses supported by mini implants.⁶

Materials and methods

Geriatric patients are likely to develop several chronic diseases (for example, arthritis, diabetes, cardiovascular disease). These disease processes occur at increasing rates with advancing age and can be treated with an ever-expanding variety of medications. There are relatively few contraindications for implant therapy due to systemic diseases.¹⁸

When discussing the impact of various medical conditions on implant failure, it is necessary to keep in mind that recorded data may be interrelated. Potential risk factors, particularly those found more frequently in geriatric patients—systemic chronic diseases, medications taken on a long-term basis, reduced salivary flow—may not be independent of each other. In contrast, one single factor alone may not influence the risk measurably, whereas a combination of multiple independent factors may have a significant impact.

Clinical examples

Two patients will help to describe the versatility and benefits obtained with mini dental implants in geriatric

patients affected by several medical conditions.

The patients will be the starting point for the authors to propose a new concept: The progressive treatment plan; a strategy designed for geriatric patients, taking into account the progressive deterioration not only of the patients' mouths but also their manual skills.

A 78-year-old man presented with a medical history of heart attack. His prescribed medicines included the following drugs: metoprolol, torvast, Lipitor® (Pfizer), lansoprazole, and a baby aspirin.

The patient presented with a removable prosthesis anchored with a telescopic system. The telescopic crown on tooth No. 22 (left canine) was lost and resulted in denture instability. Also present were serious periodontal problems on the central incisors (Figure 1). One hour prior to surgery, the patient was given 1 g of Augmentin® (GlaxoSmithKline). Two small-diameter implants (2.5 mm) were placed in the canine region flaplessly, and the central incisors were extracted (Figure 2). The antiplatelet therapy was not discontinued in accordance with recent guidelines of British Committee for Standards in Hematology.

The surgical procedure required less than 20 minutes with low stress for the patient. No surgical or

postoperative complications were recorded, and there was high patient satisfaction. The flapless approach significantly reduced surgery time and drastically reduced bleeding. The denture was adapted with the retentive housings, and the extracted teeth were added. The patient was re-evaluated after 1 week, and 1, 6, 12, and 24 months. Clinical evaluation indicated an interesting process of bone remodeling influenced by occlusal forces and not related to age (Figure 3).

The second patient, an 88-year-old man, presented with a history of cancer therapy, cardiovascular disease, and a multitude of prescribed medications. Of significance to implant therapy was the need to be on anticoagulative therapy. His request was to have a more secure feel to his upper denture. Six mini dental implants (OCO Biomedical) were treatment planned (Figure 4). After flapless implant placement, the patient functioned for 3 months with the retrofitted upper denture. The patient reported that the denture felt more secure. At a routine re-care visit, 3 months later, the patient reported that he was having difficulty inserting and removing the denture. He would routinely leave the denture in for days at a time, fearful that he would not be able to get it back in. Further inquiry revealed that this was due to a lack of physical strength and dexterity needed for proper insertion/removal of his denture. Finger notches were placed in the acrylic but had limited success.

The patient felt that a fixed solution would enable him to control his anxiety of not getting his denture inserted. His upper denture was modified to reflect a fixed hybrid design and was cemented with temporary cement. Instructions were given to maintain his oral hygiene

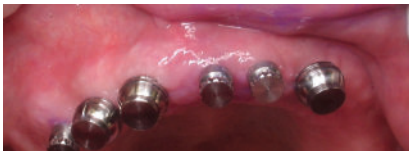

Figure 6: OCO Mini® implants with retentive housings

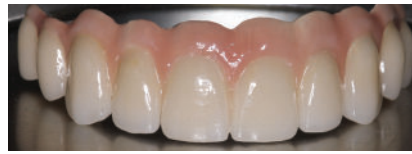

Figure 7: 10-unit bridge

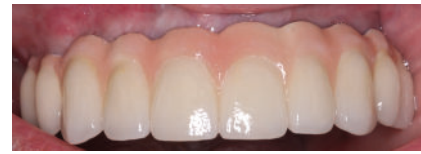

Figure 8: Mini implant bridge 1 month post-op

with a Water Pik® and toothbrush. Upon removal of the modified denture, the oral cavity, implants, and prosthesis were free of debris. With this information, a treatment plan was formulated to place an additional three mini implants to support a 10-unit fixed partial denture 10-unit FPD (Evolution Dental Lab) (Figure 5).

The progressive treatment plan took into account the physiological deterioration of the patient, and allowed us to propose the most minimally invasive solution to improve his quality of life (Figure 6, 1-month post-op).

Discussion

A peer-reviewed study of 133 edentulous patients who were 80 or older²¹ concluded that, "Implant treatment in elderly patients showed treatment results comparable to those observed in younger age groups." The acceptance of dental implants in the elderly population might be increased by providing detailed information and promoting oral health in general. Regardless of age, dental implants should be placed when patients are still in good health and live independently.¹⁹

The *Journal of the American*

Dental Association notes that despite the availability of dental implants, dentists still routinely recommend only dentures for elderly patients.²²

Accurate planning and case evaluation are imperative for success. The versatility of the mini implant offers the opportunity to propose a wide array of prosthetic solutions and is a very innovative, minimally invasive solution. Three groups that can benefit from this are patients with severe medical, anatomical, and economic constraints.

Conclusion

The demand for minimally invasive dentistry is growing from both clinicians and patients. This concept, applied to implantology, offers advantages intra-operatively, postoperatively, and during the healing process. It also offers considerable advantages to patients with systemic conditions.

"Progressive treatment planning" is a new concept and incorporates the use of mini implants. This will allow the treatment of geriatric patients through progressive steps. When patients present with edentulous areas combined with a restoratively and functionally sound dentition, mini

implants are well suited to support both removable and fixed solutions. As time, function, and age continue their relentless effects on the oral cavity, additional mini implants can easily be placed to support a larger prosthesis when needed.

The progressive treatment plan is founded on the demands of patients but takes into consideration the physical response to mini implants and the capacity to maintain oral hygiene.

Mini implant-retained dentures offer functional advantages in chewing and stability. In geriatric patients, where manual skills are often reduced, having a removable appliance can allow for proper hygiene maintenance. However as this geriatric population ages, insertion and removal of a multi-implant-supported prosthesis often is quite difficult, due in most cases to lack of physical force required. At this point, a fixed solution may provide better function and better compliance in oral hygiene.

This staggered approach of the progressive treatment plan allows patients to function properly, and gradually brings the patient, when possible and requested, to the ideal goal in prosthodontics: a fixed solution. **IP**

References

1. De Baat C (2000) Success of dental implants in elderly people—a literature review. *Gerodontology* 17(1):45-48.
2. Visser A, Meijer HJA, Raghoobar GM, et al (2006) Implant-retained mandibular overdentures versus conventional dentures: 10 years of care and aftercare. *Int J Prosthodont* 19(2):271-278.
3. U.S. Census Bureau, Population Division, Population Projections Branch. National population projections I: summary files. Total population by age, sex, race, and Hispanic origin. Available at: www.census.gov/population/www/projections/natsum-T3.html. Accessed June 28, 2011.
4. Flanagan D, Mascolo A (2011) The mini dental implant in fixed and removable prosthetics: a review. *J Oral Implantol* 37(2):123-132.
5. Flanagan D (2007) Flapless dental implant placement. *J Oral Implantol* 33(2):75-83.
6. Shatkin TE, Shatkin S, Oppenheimer BD, et al (2007) Mini dental implants for long-term fixed and removable prosthetics: a retrospective analysis of 2514 implants placed over a five-year period. *Compend Contin Educ Dent* 28(2):92-100.
7. Flanagan D (2008) Fixed partial dentures and crowns supported by very small diameter dental implants in compromised sites. *Implant Dent* 17(2):182-191.
8. Dilek O, Tezulas E, Dincel M (2008) Required minimum primary stability and torque values for immediate loading of mini dental implants: an experimental study in nonviable bovine femoral bone. *Oral Surg Oral Med Oral Pathol Oral Radiol Endod* 105(2):e20-27.
9. Sendax VI (1996) Mini-implants as adjuncts for transitional prostheses. *Dent Implantol Update* 7(2):12-15.
10. Favero LG, Pisoni A, Paganelli C (2007) Removal torque of osseointegrated mini-implants: an in vivo evaluation. *Eur J Orthod* 29(5):443-448.
11. Okazaki J, Komasa Y, Sakai D, et al (2008) A torque removal study on the primary stability of orthodontic titanium screw mini-implants in the cortical bone of dog femurs. *Int J Oral Maxillofac Surg* 37(7):647-650.
12. Tinti C, Parma-Benfenati S (2003) Clinical classification of bone defects concerning the placement of dental implants. *Int J Periodontics Restorative Dent* 23(2):147-155.
13. Bulard RA, Vance JB (2005) Multi-clinic evaluation using mini-dental implants for long-term denture stabilization: a preliminary biometric evaluation. *Compend Contin Educ Dent* 26(12):892-897.
14. Shatkin TE, Shatkin S, Oppenheimer AJ, et al (2003) A simplified approach to implant dentistry with mini dental implants. *Alpha Omegan*. 96(3):7-15.
15. Comfort MB, Chu FCS, Chai J, et al (2005) A 5-year prospective study on small diameter screw-shaped oral implants. *J Oral Rehabil* 32(5):341-345.
16. Degidi M, Piattelli A, Gehrke P (2006) Five-year outcome of 111 immediate nonfunctional single restorations. *J Oral Implantol* 32(6):277-285.
17. Blanchaert RH (1998) Implants in the medically challenged patient. *Dent Clin North Am* 42(1):35-45.
18. Bornstein MM, Cionca N, Mombelli A (2009) Systemic conditions and treatments as risks for implant therapy. *Int J Oral Maxillofac Implants* 24(Suppl):12-27.
19. Dental implants: knowledge and attitude in elderly adults (IADR/AADR/CADR 87th General Session and Exhibition (April 1-4, 2009)
20. Weiss CM (2001) Preserving proven concepts in implant dentistry. *J Oral Implantol* 27(2):59-61.
21. Engfors I, Ortorp A, Jemt T (2004) Fixed implant-supported prostheses in elderly patients: a 5-year retrospective study of 133 edentulous patients older than 79 years. *Clin Implant Dent Relat Res* 6(4):190-198.
22. Stanford CM (2007) Dental implants: a role in geriatric dentistry for the general practice? *J Am Dent Assoc* 138:345-405.