

Splinted Zirconia Fixed Partial Denture Supported by Small Diameter (Mini Implants) in the Posterior Mandible: A Case Letter

Andrea Mascolo, DDS^{1*}
Paresh Patel, DDS²

INTRODUCTION

Implant-supported fixed partial dentures can restore a patient's missing posterior dentition. However, in sites that are atrophic, standard body endosseous implants may not be properly contained by the available bone, thus violating the principle of encasing the implant in a minimum of 1 mm of bone. Alternatively, solid core one-piece, small-diameter (mini) dental implants can be used in highly selected sites with great circumspection.

Mini dental implants have been successfully used to support fixed prosthesis that restore missing maxillary and mandibular incisors as well as mandibular posterior teeth.¹

The purpose of this case letter is to demonstrate that splinted mini implants may successfully support a fixed zirconia partial denture in the posterior mandible in highly selected patients and with an appropriate prosthetic design. The use of 2 small-diameter (mini) implants can reduce the cantilever effect created when using the procedure recommended by Misch (4-mm implant for a 7-mm mesial distal width).²

CASE LETTER

A 48-year-old man presented for restoration of his edentulous mandibular left first and second molar sites (nos. 18 and 19) (Figure 1). The patient reported that these teeth were extracted 10 years prior. His medical history was unremarkable and

there were no contraindications to dental implant treatment.

After clinical and radiographic examination, atrophic resorption was found in the buccal-lingual as well as occlusal-gingival dimension (Figure 2). Bone sounding evaluation demonstrated less than 5.0 mm of facial-lingual bone. The patient declined any bone grafting or ridge expansion due to fear, costs, and surgical trauma.

Occlusal analysis showed group function in lateral movements and a missing maxillary second molar. Based on these parameters, it was decided to use 3 mini dental implants to support splinted premolar-sized crowns with an implant protective occlusal scheme.

Buccal and lingual local infiltration was administered with 3.8 mL 2% lidocaine with 1:100 000 epinephrine (Xylocaine). Three 2.5 × 12 mm one-piece mini dental implants (OCO Biomedical, Albuquerque, NM) were placed. Care was taken to keep the implant placement as parallel as possible and to avoid the mandibular canal (Figure 3). Placement seating torque was at 45 Ncm for all 3 implants.

After 4 months of healing, conventional full arch crown and bridge impressions were made with polyvinyl siloxane (Take 1, Kerr, Orange, Calif) (Figure 3). Analogs were placed in the impression to be contained in the cast for splinted zirconia crown fabrication. A splinted zirconia core was made to fit down to the square portion of the 3 mini implants and then layered with feldspathic porcelain. (Glidewell Dental Lab, Newport Beach, Calif) (Figures 4 and 5). The occlusal table was made flat and narrow, and to have no opposing contact in the working and balancing excursions.

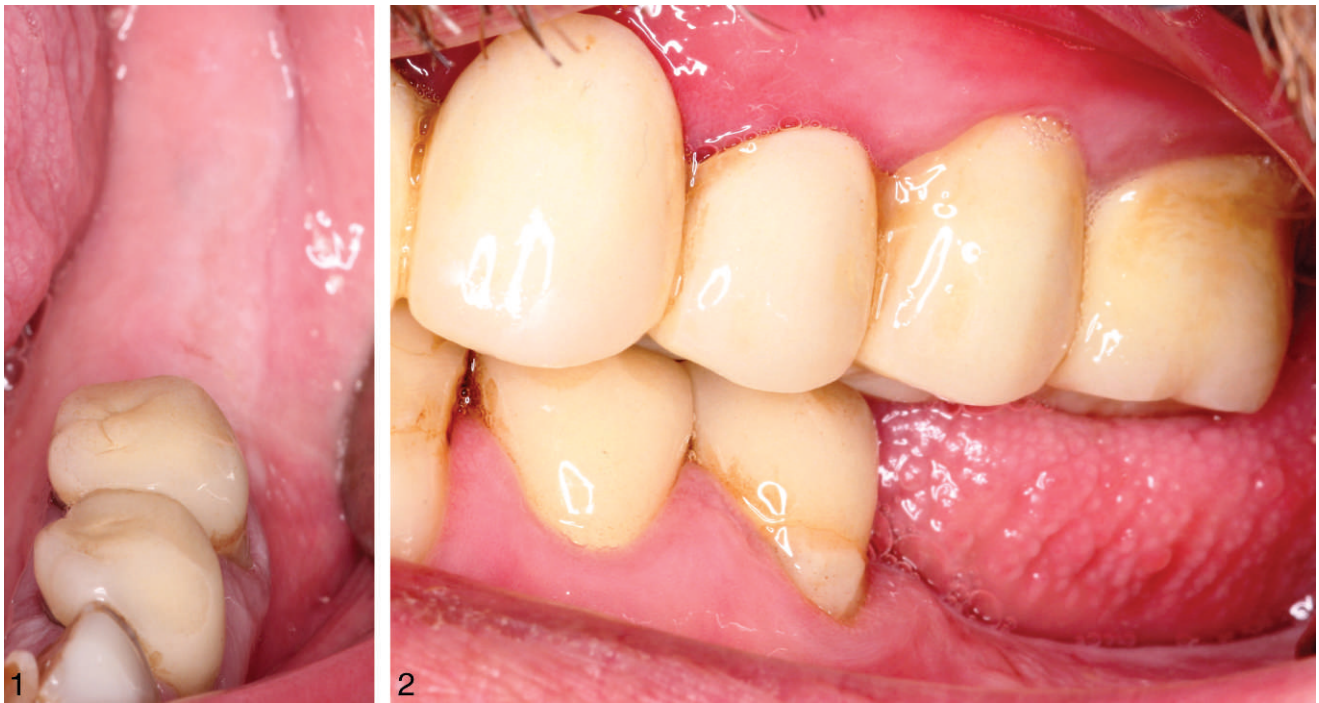Two weeks later, the splinted definitive crowns were tried in and evaluated for fit, function, and

¹ Private practice, Alessandria, Italy.

² Private practice, Mooresville, NC.

* Corresponding author, e-mail: andrea@studiomascolo.eu

DOI: 10.1563/AAID-JOI-D-12-00043

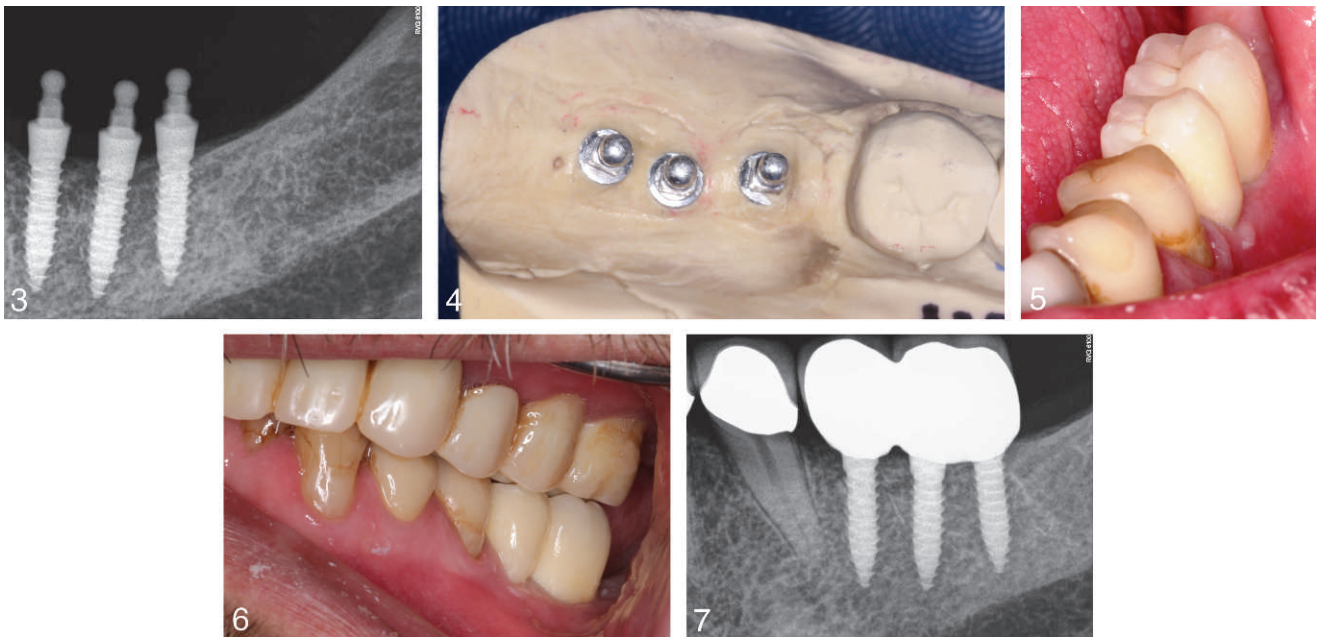


FIGURES 1 AND 2. **FIGURE 1.** The patient presented with an edentulous mandibular left. **FIGURE 2.** There was loss of vertical bone.

esthetics (Figure 5). After the patient's approval, the definitive splinted crowns were cemented with resin cement (Maxcem Elite, Kerr) (Figure 6). The tissue level zirconia margins are kept clean with daily

brushing, flossing, and the use of an AirFloss (Sonicare, Stamford, Conn).

The splinted fixed partial denture has been in function for 9 months with no symptoms, bleeding



FIGURES 3–7. **FIGURE 3.** Three mini implants were placed. **FIGURE 4.** The working cast was fitted with analogs. **FIGURE 5.** The crowns had a narrow rounded flat occlusal table to minimize off-axial occlusal forces. **FIGURE 6.** Slight occlusal relief was provided to account for natural tooth intrusion. **FIGURE 7.** A periapical radiograph was taken after 9 months of function.

on probing, or clinical signs of inflammation or mobility (Figure 7).

DISCUSSION

In situations where there may be an inadequate interdental space, reduced interocclusal space, convergent adjacent tooth roots, close proximity of adjacent tooth roots, narrow atrophic osseous contour, and adequate osseous quality, mini implants may be appropriate to support a fixed prosthesis in highly selected patients.^{3,4}

Bone sounding, while not as accurate as cone beam computerized tomography, can give the clinician an approximation of the osseous contour of the underlying bone at a particular site without subjecting the patient to radiation exposure and expense.⁴ The ridge mapping in this patient demonstrated an atrophic ridge contour of about 5 mm facial-lingual width. This was not enough bone volume to contain a standard diameter implant (3.75–5.7). The bone quality was assessed during the osteotomy sequential drilling and deemed to be of adequate density to support mini implants and adequately resist the delivered occlusal forces.

In this case example, to reduce the potential for implant overload, the decision was made to use 3 mini implants splinted together. This would allow for an increase in implant surface area while minimizing the volume of bone removal during the osteotomy. The final fixed restoration would also be designed with a narrow occlusal table to keep off axis forces to a minimum and to help prevent metal fatigue and cyclic-loading stress.

There are advantages to using 2 to 3 mini implants to support a molar restoration instead of a single wide-diameter implant. Quite often, the loss of mandibular molars results in a mesial-distal dimension that is insufficient in length for the placement of 2 conventional, standard-size implants. The use of mini implants in this case letter allows for minimal cantilevers in the final restoration. There is greater flexibility to maximize placement in compromised bone sites engaging the facial and lingual plates, and there may be

better retention of crestal bone levels around mini implants.⁵

However, the use of mini implants does have significant limitations, with reduced surface area being the foremost. When an occlusal force is applied, the strain to the supporting bone around small-diameter implants will be greater than a standard body implant.^{6–8}

CONCLUSIONS

Splinted mini implants may successfully support zirconia fixed partial dentures in the posterior mandible in highly selected patients with an appropriate prosthetic design. The implant dentist should consider many diverse implant and prosthetic designs to treat appropriately the anatomic conditions with which patients present.

ACKNOWLEDGMENT

The authors acknowledge the help of Dennis Flanagan, DDS, in the preparation of this manuscript. Clinical dentistry by Paresh B Patel, DDS.

REFERENCES

1. Mazor Z, Lorean A, Mijiritsky E, Levin L. Replacement of a molar with 2 narrow diameter dental implants. *Implant Dent.* 2012; 21:36–38.
2. Mische CE. Single tooth replacement: treatment options. In: Mische CE, ed. *Contemporary Implant Dentistry*. 3rd ed. St Louis, Mo: CV Mosby; 2008:327–366.
3. Shatkin TE, Shatkin S, Oppenheimer AJ, Oppenheimer BD. A simplified approach to implant dentistry with mini dental implants. *Alpha Omegan.* 2003;96:7–15.
4. Flanagan D. Fixed partial dentures and crowns supported by very small diameter dental implants in compromised sites. *Implant Dent.* 2008;17:182–191.
5. Flanagan D, Mascolo A. The mini dental implant in fixed and removable prosthetics: a review. *J Oral Implantol.* 2011;37(Spec No): 123–132.
6. Romeo E, Lops D, Amorfini L, Chiapasco M, Ghisolfi M, Vogel G. Clinical and radiographic evaluation of small-diameter (3.3-mm) implants followed for 1–7 years: a longitudinal study. *Clin Oral Implants Res.* 2006;17:139–148.
7. Lum LB, Osier JF. Load transfer from endosteal implants to supporting bone: an analysis using statics. *J Oral Implantol.* 1992;18: 343–353.
8. Weiss CM, Weiss A. *Principles and Practice of Implant Dentistry*. St Louis, Mo: Mosby Inc; 2001.