Search Dentaltown

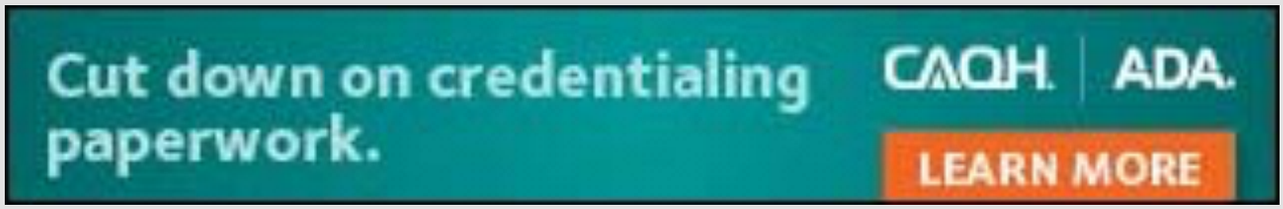

Aesthetic Option to Replace Missing Maxillary Laterals Dr. Paresh B. Patel

add comment

More Options

Share 0
Tweet
Share
Save 0
Share

SDI SMALL DIAMETER IMPLANTS

by Paresh B. Patel, DDS

An Aesthetic Option to Replace Missing Maxillary Laterals

One of the most difficult restorative procedures to manage has always been how to replace the missing anterior tooth. One of the most common in young adults happens to be the congenitally missing lateral incisor (Fig. 1).[1]

Treatment options range from:

A traditional three-unit bridge utilizing the canine and central incisor as abutments

A resin-bonded bridge utilizing the canine and central incisor lingual surfaces as retainers

Orthodontic movement of the canine into the lateral position along with cosmetic reshaping

An implant to replace the missing maxillary lateral

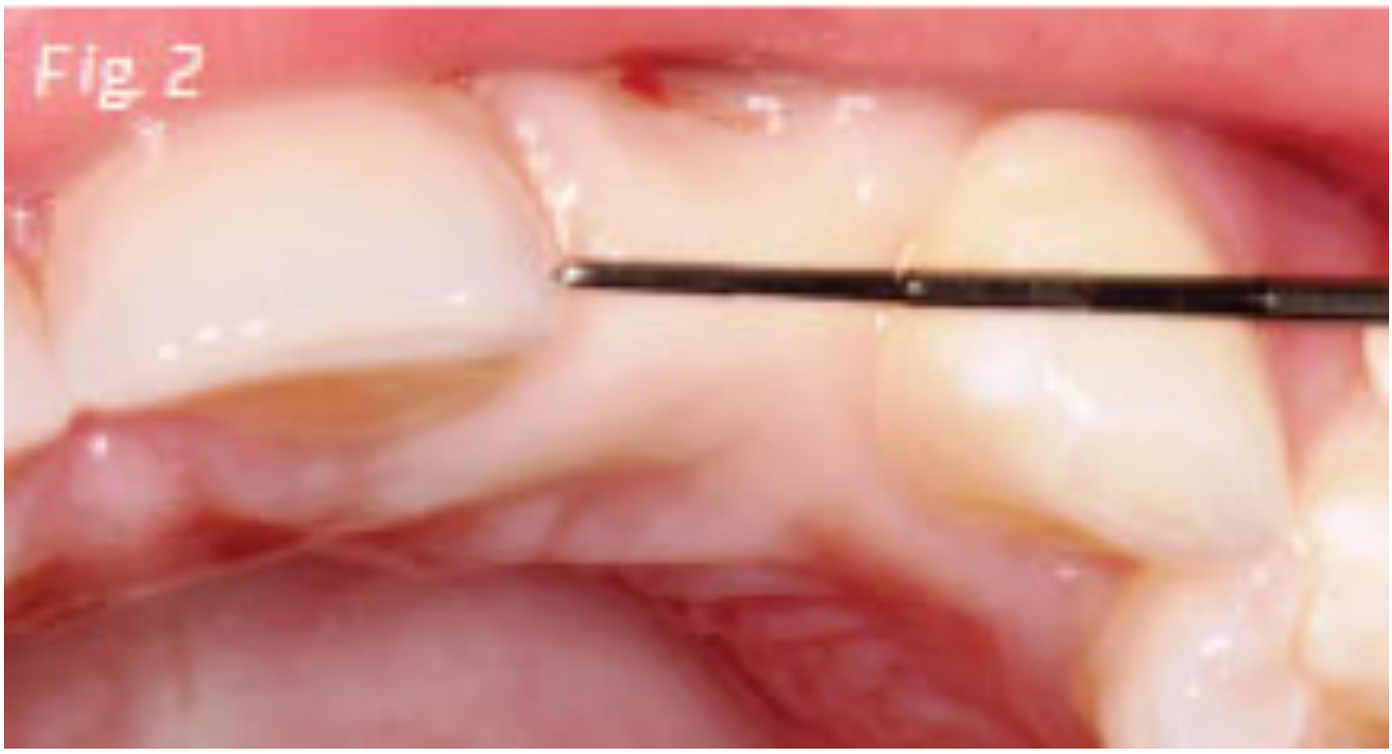

If enough bone volume, soft tissue and mesial distal space is available, then a standard body implant can be considered. In cases where these dimensions are deficient, the restorative dentist will have difficulty managing these violated parameters. Potential problems can be lack of restorative prosthetic space, implants too close to adjacent roots, implant shows through or facial plate dehiscence.

A novel solution to solve these issues can be the use of a 3.0mm implant. The use of a small-diameter implant such as this should be considered as most congenitally missing maxillary lateral incisors have an edentulous space of around 5.5 to 6.5mm (Fig. 1). The facial lingual dimension can also be compromised and usually has a dimension of 5mm (insufficient to adequately place a standard body implant without bone manipulation). In an area where only 6mm of space exists, the SDI allows for the placement of the implant 1.5mm from the adjacent teeth. Other reasons to consider the use of a 3.0mm SDI could be that most implants have abutments larger than the implant crestal dimension (including platform shifted abutments). This is usually done to enhance the emergence profile of the final prosthesis and creates the need for even more additional space. The 3.0mm SDI is one piece in design and with no microgap crestal bone loss may also be reduced or eliminated.[2]

Fig. 3

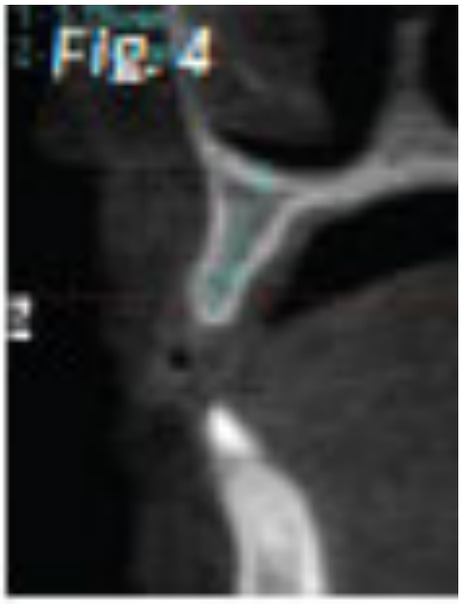
Fig. 4

Fig. 5

Fig. 6

Fig. 7

Fig. 8a

Fig. 8b

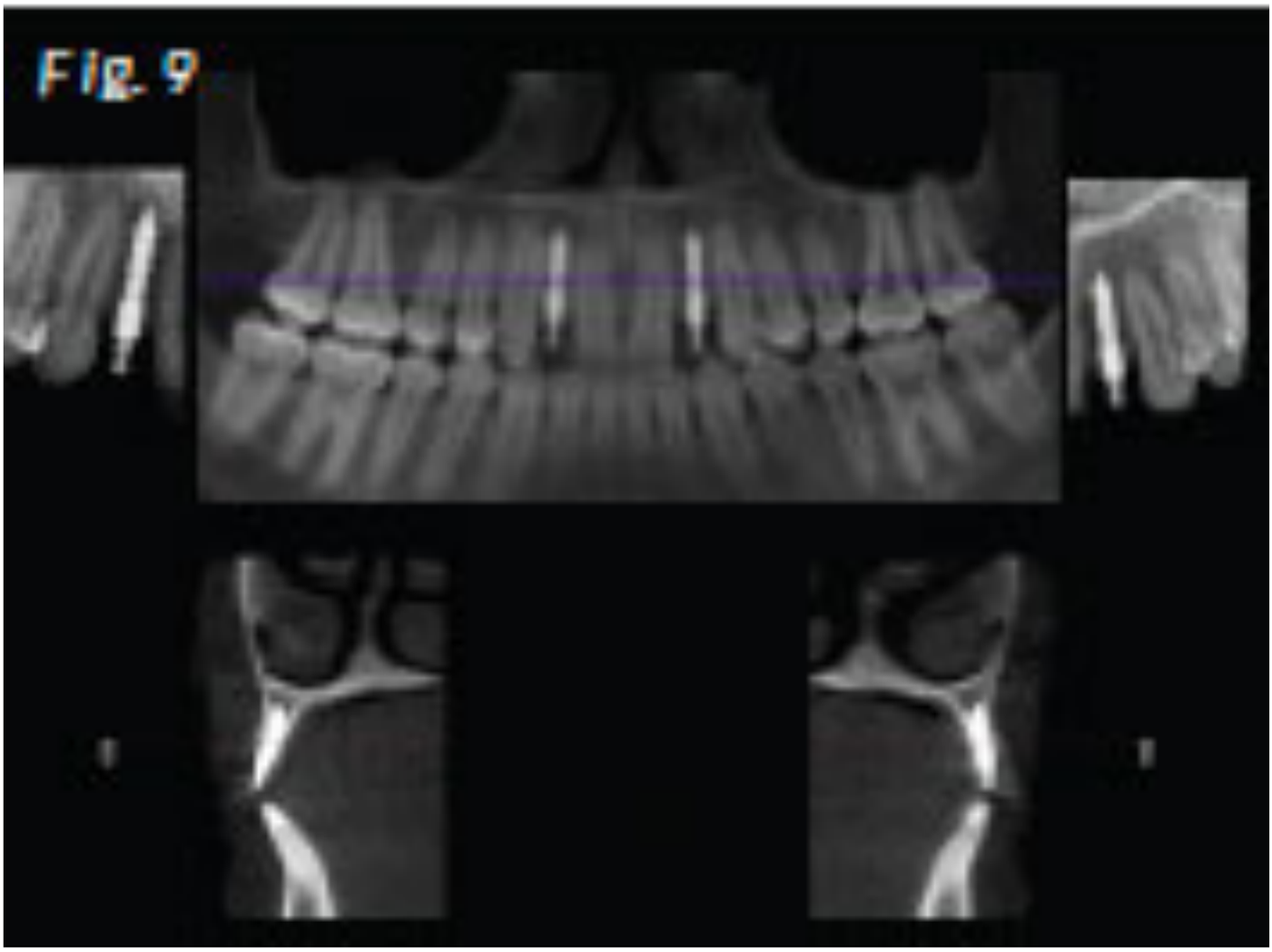

Clinical Case

A 17-year-old female presented to our office requesting replacement of her congenitally missing laterals. She had completed orthodontic treatment 12 months prior. Clinical examination reveled lack of mesial-distal space (Fig. 2) as well as spacing between the adjacent roots. Bone sounding confirmed limited facial-lingual width at around 3.5mm (Fig. 3). The patient declined our suggestions to consider a bone graft and soft tissue graft to add hard and soft volume to the edentulous areas. To confirm our clinical findings the patient was sent for a CT scan (Gendex GB-500 iCAT). Cross sectional slices demonstrate a facial lingual width of 3.8mm in the area of #7 and #10 (Fig. 4). Based off these results, it was readily assessed that a SDI would be necessary to replace the missing teeth.

Surgical Procedure

The placement protocol for SDI is similar to other endosteal implants. A pilot drill was used in a flapless approach to puncture through the cortical plate. A 3mm tissue punch (Zoll-Dental) was used to remove the overlying tissue and to visualize the boney crest (Fig. 5). The flapless approach preserved as much blood supply as possible to the compromised site. With the CT scan, our knowledge of the angle and topography of the ridge was known prior to surgery and the need to make a flap was further reduced. If at any time the need became apparent, a flap could and should be made. The pilot bit was stopped short of full depth and the quality of bone was assessed clinically with the blunt end of an endo probe. This was done to confirm what our CT scan showed as D3 bone in Hounsfield units. A PA was exposed to confirm that the pilot bit was aligned parallel between the adjacent tooth roots. Once confirmed a final drill of 2.4mm was taken to three-quarters depth of the implant length. This was done to follow our protocol that when in poor bone, the SDI will act as an osseotome and will compress and expand the bone to create bone of a more dense nature.

A small diameter implant 3.0 x 13mm MILO (Intra-Lock) was selected for a few important reasons (Fig. 6). Its Ossean surface is impregnated with calcium phosphate at the molecular level, allowing the implant to bypass the catabolic phase of bone remodeling. With that the implant can begin its osseointegration weeks ahead than without this nano-textured surface; a huge advantage when we are talking about one piece implants that require some sort of immediate restoration.

Fig 12

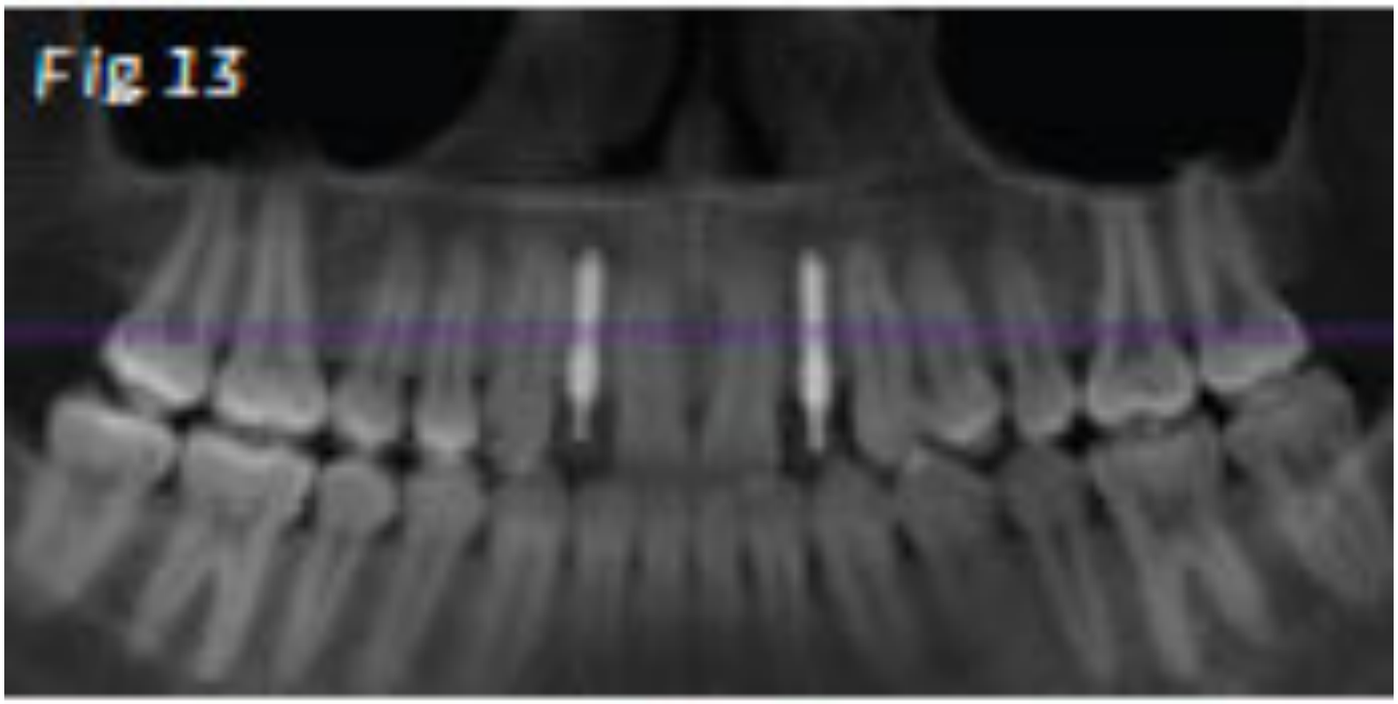
Fig 13

Fig 14

Cement over abutments for this system were also planned to be used to convert the O-ball into a crown form (Fig. 7). It allows for any laboratory to make a well-fitting crown on SDIs. The implant was introduced into the osteotomy via an implant handpiece (Aseptico AEU-7000). I prefer to place implants with a handpiece to minimize off axis vector forces. The SDI was gently rotated to its full seating depth at 30RPM and achieved a final torque of 45ncm (Figs. 8a & 8b on previous page). A final PA and CT scan was taken to ensure the one piece 3.0mm SDI was fully seated in bone with no threads above the crestal margin nor penetrated out of the facial or lingual plates (Fig. 9).

A plastic comfort cap was snapped over the O-ball and square portion of the one piece SDI. This would allow the soft tissue to be sculpted as healing occurred and would keep the gum tissue from covering the square platform of the implant (Fig. 10). Composite was added to the comfort caps to fashion an immediate non-loaded temporary. Impressions were taken (Capture Glidewell Direct) and sent to the lab for custom temporaries (DuraTemp Burbank Laboratories) (Fig. 12).

With the use of the DuraTemps, the tissue could continue to be formed for an ideal aesthetic result while function and phonetics could be verified (Fig. 13).

To ensure an elegant prosthetic solution, it was decided to utilize cement over abutments (Intra-Lock). This abutment converts the standard O-ball portion of the SDI into a tapered crown form and can be modified on the working model (Fig.11). By using the cement over abutments the laboratory can fabricate the implant-supported prosthesis with standard crown and bridge techniques and create a “true fit” SDI crown within the confines of a smaller prosthetic space.

Discussion

TSDI does have certain limitations. The foremost being reduced surface area. A 3.0mm SDI has about 33 percent less surface area than a 4mm standard body implant. In this case, due to the constricted mesial distal width, the use of an SDI is appropriate. Occlusal forces will be manageable due to the small prosthetic size of the laterals and the implant can be fully encased in bone without the fear of fenestration along the buccal aspect. The one-piece design provides a micro-gap-free design and good crestal bone maintenance as well as no chance for screw loosening.

Another limitation of SDI is the need for immediate restoration (not necessarily immediate function). The implant, due to its design, will have its abutment supragingival at the time of placement. This puts SDI at risk of being loaded during the healing phase by any oral habits.

The prosthetic replacement of a missing tooth has been a challenge for clinicians for years. This is compounded when dealing with a constricted aesthetic site. This case report demonstrates the novel use of SDI as part of a practitioners' implant armamentarium. When considering the use of an SDI, it is prudent to select one that offers the best features to allow quick osseointegration.

References

Graber JM. Anomalies in number of teeth. In: Graber TM, ed. Orthodontics: Principles and practice. 1966

Misch CE. Early bone loss etiology and its effect on treatment planning. Dent today June 1996

Author's Bio

Dr. Paresh Patel is a graduate of UNC-CH School of Dentistry and the MCG/AAID MaxiCourse. He is the co-founder of the American Academy of Small Diameter Implants and is a clinical instructor at the Reconstructive Dentistry Institute. Dr. Patel has placed more than 2,500 mini implants and has worked as a lecturer and clinical consultant on mini implants for various companies. He can be reached at pareshpateldds2@gmail.com or online at www.dentalminiimplant.com.

Share 0
Tweet
Share
Save 0
Share

add comment

view article pdf

more by this author (6)

Dentaltown Magazine

January 2019

Read Current Issue

Subscribe / Renew

Sponsors

The perfect radio show for Dentists looking for **ANSWERS!**

Company Info

contact us

advertise with us

howard farran dds, mba

privacy policy

terms of use

Communities

Dentaltown

Hygienetown

Orthotown

Site Help

Sally Gross, Member Services

Phone: +1-480-445-9710

Email: sally@farranmedia.com

Dentaltown Magazine

Macy Gross, Circulation

Phone: +1-480-445-9716

Email: macy@farranmedia.com

Follow Dentaltown

Follow Howard

Mobile App

WITH DENTALTOWN . . . NO DENTIST WILL EVER HAVE TO PRACTICE SOLO AGAIN®

WWW.DENTALTOWN.COM - WHERE THE DENTAL COMMUNITY LIVES®

9633 S. 48th Street Suite 200 • Phoenix, AZ 85044 · Phone: +1-480-598-0001 · Fax: +1-480-598-3450

©1999-2019 Dentaltown, L.L.C., a division of Farran Media, L.L.C. · All Rights Reserved