



Eduardo Anitua, Jose M Errazquin, José de Pedro, Pedro Barrio, Leire Begoña, Gorka Orive

Clinical evaluation of Tiny[®] 2.5- and 3.0-mm narrow-diameter implants as definitive implants in different clinical situations: a retrospective cohort study



Eduardo Anitua, MS, DDS, PhD

Private practice in implantology and oral rehabilitation, Vitoria, Spain

Jose M Errazquin

Private practice in implantology and oral rehabilitation, Irun, Spain

José de Pedro

Private practice in implantology and oral rehabilitation in Logroño, Spain

Pedro Barrio

Private practice in implantology and oral rehabilitation in Logroño, Spain

Leire Begoña, MSc

Eduardo Anitua Foundation, Vitoria, Spain

Gorka Orive, PhD

Biotechnology Institute (BTI), Vitoria, Spain

Correspondence to:

Eduardo Anitua
Instituto Eduardo Anitua,
c/ Jose Maria Cagigal 19,
10005 Vitoria, Spain
Tel: +34 945160652;
Fax: +34 945155095;
Email: eduardoanitua@
eduardoanitua.com

Key words failure, long-term follow-up, narrow-diameter implants, narrow implants, plasma rich in growth factors (PRGF), survival analysis

Aim: The aim of the present study was to assess retrospectively the survival of narrow-diameter implants (2.5 and 3 mm in diameter) in patients with insufficient bone ridge thickness for placement of standard-diameter implants.

Material and methods: Fifty-one patients with 89 inserted narrow-diameter implants (2.5 and 3.0 mm) were included. Patients were treated with one or more narrow-diameter implants between June 2004 and December 2005. The observation period for all included implants was at least 3 years after implant loading. Outcome measures were implant survival, complications and marginal bone level changes evaluated on panoramic radiographs.

Results: The mean follow-up period for all implants was 48 months. Only one implant was lost, yielding survival rates of 98.9% and 98.0% for the implant- and subject-based analyses, respectively. Six complications were reported. Twenty-four months after implant insertion, mean bone loss was 1.26 mm (SD 0.51).

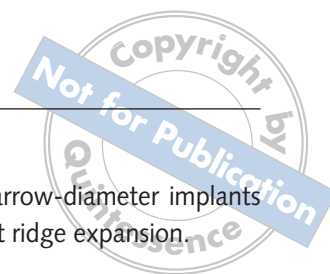
Conclusions: Narrow-diameter implants can be successfully used to treat narrow bone ridges up to 3 years after loading.

■ Introduction

For more than two decades, the use of osseointegrated implants has progressively improved the treatment planning of patients who have lost their teeth partially or totally. These advances have enabled the restoration of partially edentulous dental arches, the replacement of a single tooth and the use of maxillofacial, intrabuccal and extrabuccal prostheses for

significant improvement of functional capacity and aesthetics. By developing modifications in the designs of the implants, it has been possible to adapt them to the location as well as to the different characteristics of the bone where they are to be implanted. Additionally, it has been demonstrated that under certain circumstances the survival rates for short and wide-diameter implants are comparable with those obtained with longer implants and those of a standard diameter¹⁻³.

Conflict of interest: The present article was funded by the Biotechnology Institute (BTI, Vitoria, Spain). Gorka Orive and Leire Begoña are researchers at the Eduardo Anitua Foundation. Eduardo Anitua is the scientific director of BTI.



The placement of a regular-sized implant in a reduced interradicular space may increase the risk of violating the periodontal ligaments of adjacent teeth. In addition, the disparity in size between the implant, its restorative hardware and the smaller replacement tooth may also provoke overcontouring of the restoration⁴. In some cases, dental implants of standard size cannot be placed on a regular basis, for various clinical reasons. When the so-called 'mini-implants' came into use as temporary implants, the aim was to remove them when the larger-diameter implants were put into service. However, when clinicians attempted to remove these provisional mini-implants, they found it very difficult as they were integrated into the bone during the interim service period. As a result, some companies producing mini-implants applied for approval of the small-diameter implants for long-term use.

When inadequate bone width is present for placement of standard-diameter implants, most practitioners have been taught to suggest bone grafting, using either autogenous bone or one of the many available bone substitutes, usually by bone block grafting. However, all patients prefer minimally invasive techniques. Bone grafting is a well-documented procedure to restore lost bone volume, but it is associated with increased morbidity and a prolonged treatment time, with the necessary graft-healing period when dentures cannot be worn⁵.

Narrow-diameter implants have the potential to assist in this challenge. This type of implant can also be used in other clinical situations, including narrow interdental space, reduced bone ridge width, and the rehabilitation of incisors characterised by limited cervical diameter⁶. In recent decades several studies⁴⁻²² have reported the use of narrow-diameter implants in different clinical situations and using different surgical techniques (immediate loading, with or without allografts, and single restorations). In most cases, satisfactory results have been obtained, achieving medium- and long-term cumulative survival rates equivalent to those obtained in restorations using larger diameter implants (between 94% and 100% survival rates).

The aim of the present study was to retrospectively assess survival of narrow-diameter implants (2.5 and 3 mm in diameter) used as definitive implants in patients with insufficient bone ridge thickness for placing standard-diameter implants,

and also in cases where narrow-diameter implants could not be placed without ridge expansion.

■ Materials and methods

This article was written following the STROBE (Strengthening the Reporting of Observational studies in Epidemiology) guidelines²³.

The present study is an observational, retrospective, multicentre clinical study. Four private centres in Spain (Clínica Dental Dr Errazkin, Irun; Clínica Dental Dr Anitua, Vitoria; Clínica Dental Dr Barrio, Logroño; Clínica Dental Dr De Pedro, Logroño) were involved and 51 patients with 89 inserted narrow-diameter implants (2.5 and 3.0 mm in diameter) were included. Patients were identified using their clinical records and all of them who met the defined criteria were included in the study. All patients were treated with one or more Tiny® narrow-diameter implants (Biotechnology Institute, BTI, Vitoria, Spain) between June 2004 and December 2005. The observation period for all included implants was at least 3 years after implant loading.

Patient inclusion criteria included both genders, subjects with totally or partially edentulous jaws and insufficient bone ridge thickness (2.5–4 mm) for standard implant placement who were treated by 2.5- and 3.0-mm narrow-diameter implants (one or more). Exclusion criteria were patients whose implants were loaded for less than 3 years. Only subjects with good general health, without active infection or severe inflammation in the areas for placement of the implant prior to the operation, and without previous treatment with radiotherapy in the head or neck in the year prior to the intervention were included.

■ Implant placement surgical protocol

All clinical centres followed the same surgical protocol and treatment plan. At least one panoramic radiograph was taken for all patients prior to the intervention, to assess bone quality and quantity, and to measure the ridge height and width of the supporting bone. In most cases, a computerised axial tomography scan was also made to allow the physician to make a detailed study using specialised software in implant surgery planning (BTI Scan®, BTI). Rehabilitations were performed by six prosthodontists.



During the days prior to the intervention, all patients received adequate prophylaxis and oral hygiene instructions. Patients received 1 g of amoxicillin and 1 g of acetaminophen as prophylactic medication 1 h before the intervention. Prior to the intervention, all patients performed 1-min rinses with chlorhexidine digluconate 0.20% mouth rinse. Lips and the perioral area were also cleaned with chlorhexidine. An infiltrative anaesthesia was applied to all patients. Implant sites were prepared using a low-speed drilling procedure (125-50 rpm) without irrigation²⁴. Before installation, implants were carefully embedded in liquid plasma rich in growth factors (PRGF®, BTI) with the aim of bioactivating the implant surface²⁵.

After the intervention, patients were encouraged to take acetaminophen (1 g/8 h) or ibuprofen (600 mg/8 h), in case of pain. Patients were also instructed in the maintenance of proper oral hygiene around implants. In addition, just after the intervention, a panoramic radiograph was taken to verify adequate placement of the implant.

■ Clinical assessment

Patients were referred to a series of periodic evaluations, consisting normally of evaluations at 2 to 3 days after intervention, at 1 month, at 3 months, at 6 months and then once a year. The post-implant assessment at each follow-up visit included different clinical assessments to verify the status of the implant (gingival health, prosthesis mobility, pain, infection, alveolar ridge resorption and any complications). Moreover, periodic panoramic radiographs were carried out to verify the state of the implant in the follow-up period. In each clinical centre, data were collected from the patients' clinical records. Variables were registered regarding the patients, implants, surgery and prosthesis. The primary outcome measure was implant survival rate at the end of the observation period (at least 3 years after implant loading). The implant was considered to be successful if it complied with the following success criteria:

- a stable prosthesis
- absence of pain, infections or any other pathology related to the implants
- absence of a radiolucent line around the implant;

and if none of the following events occurred:

- implant loss
- fracture that makes support of the prosthesis impossible
- significant bone loss
- lack of osseointegration.

Implant loss was considered any implant lost due to biological (failure to achieve osseointegration or loss of acquired osseointegration) or biomechanical causes. Marginal bone levels were measured on the panoramic radiographs taken directly after the surgery and at least 24 months after implant placement. All panoramic radiographs were carried out using a positioning pin (with the patient's chin resting on a standard device) and with the Frankfurt plane parallel to the ground. Measurements on the panoramic radiographs were performed using computer software (Sidexis XG, Sirona Dental Systems, Bensheim, Germany), which performs calibration of the radiograph using a known length (implant length). Once the radiograph was calibrated to a 1:1 ratio, eliminating the possible presence of magnification, measurements were made mesially and distally to the implants, calculating the distance between the edge of the implant and the most coronal contact between the bone and the implant. The bone level recorded just after the surgical insertion of the implant was the reference point for the subsequent measurements.

Data collection and analysis were performed by two independent examiners. The primary outcome measure was implant survival. Descriptive statistics were used. Peri-implant bone level changes were averaged at the patient level.

■ Results

In the present study, 89 narrow-diameter implants (2.5 and 3 mm in diameter), inserted in a total of 51 patients were included. The mean age of the patients at insertion time was 54.84 years (standard deviation [SD] 12.6 years) (range 19 to 90 years). A total of 39 patients were female (76.5%). Twelve subjects (23.5%) were smokers. Ten out of 51 patients showed previous periodontal disease (19.6%), one showed maxillary pathology (cleidocranial dysostosis), and two patients were affected by diabetes mellitus (3.9%).

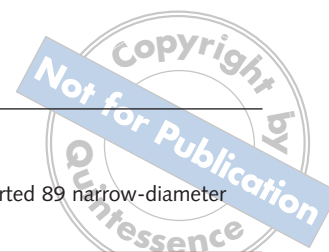


Table 1 Frequency of the inserted narrow-diameter implants.

Diameter (mm)	Lengths (mm)				Total
	10	11.5	13	15	
2.5	2	6	14	9	31
3.0	6	3	27	22	58
Total	8	9	41	31	89

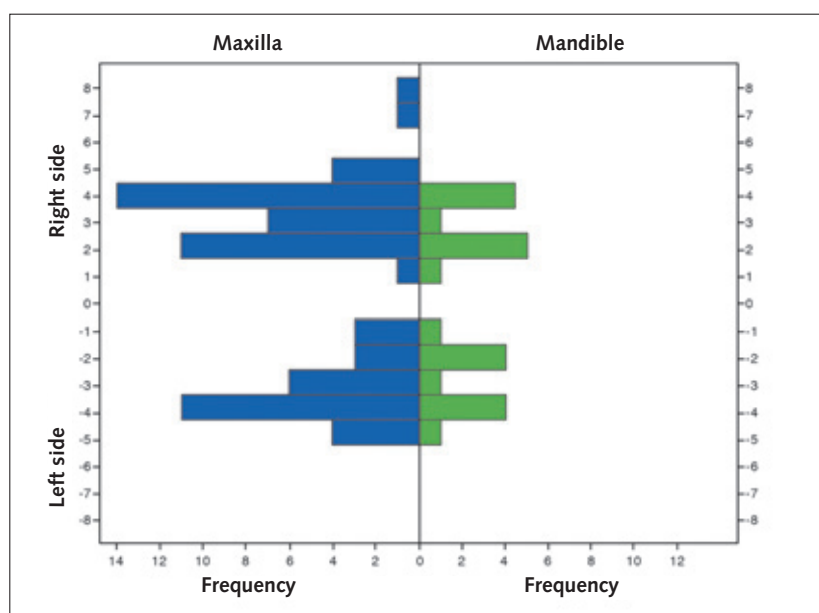


Fig 1 Anatomic distribution of the 89 narrow-diameter implants. The y-axis shows the anatomical location of implants whereas the x-axis illustrates both the frequency of the inserted implants and the jaw location.

The frequency of the lengths and diameters of the 89 narrow-diameter implants is given in Table 1. Regarding implant positions, 66 implants (74.2%) were inserted in the maxilla. Figure 1 shows the anatomic distribution of the implants, and Table 2 provides the main anatomic, surgical and prosthetic characteristics of the implants included in the study.

Regarding the prostheses used, more than a half of the implants (55.1%) were rehabilitated with fixed partial dentures. Complete overdentures were used in the 30.3% of the implants, whereas 13% of the implants were rehabilitated with single crowns. Most of the prostheses were cemented (80.9%).

Marginal bone loss was measured in 61 out of 89 implants (only those in which a panoramic radiograph was available 24 months post-insertion). Results


Table 2 Description of the inserted 89 narrow-diameter implants.

Implants		No. of implants	%
Position	Buccal	83	93.3
	Lingual	1	1.1
	Medial	5	5.6
Adjacent structures	1 tooth	2	2.2
	1 implant	2	2.2
	1 tooth + 1 implant	26	29.2
	2 teeth	19	11.2
	2 implants	49	55.1
Bone type	I	6	6.7
	II	30	33.7
	III	37	41.6
	IV	16	18.0
Surgical phases	1	57	64.0
	2	32	36.0
Crest expansion	Yes	69	77.5
	No	20	22.5
Particulate bone graft	Yes	46	51.7
	No	43	48.3
Loading type	Immediate	27	30.3
	Deferred	62	69.7
Initial torque (Ncm)	0–15	16	18.0
	15–30	37	41.6
	30–40	36	40.5

showed that mean marginal bone loss was 1.26 mm (SD 0.51; median 1.26, range 0.24 to 2.73 mm).

The mean follow-up period for all implants was 48.06 months (SD 4.95). Table 3 shows the follow-up times for the non-failed implants and patients. Only one implant failed during the observation period. The patient (59-year-old female) receiving this implant suffered from rheumatoid arthritis and presented an extremely resorbed cortical ridge. The implant was placed in one surgical phase after a ridge expansion procedure and using lyophilised bone graft. Furthermore, the implant was immediately loaded, as a transitional implant.

During the study observation period, a total of six complications were registered in six patients (two infections, two pain episodes, one inflammation in



the mucosa around the implant, and one stomatitis). Complications did not exceed 8 days in duration and were described as mild, as they were well tolerated by the subjects and did not interfere with their normal activities. One of the patients with an infection received oral antibiotics for 4 days as treatment, while in the other infection case, the area was drained. One patient who presented pain received additional non-steroidal anti-inflammatory drugs. Figures 2 and 3 show the clinical situations before and after treatment in two patients involved in the study.

■ Discussion

Dental implants with a reduced diameter are designed for specific clinical situations, such as placement of implants where bone width is narrow or between adjacent teeth that have only a narrow space between them. They are also a viable alternative to bone augmentation when poor alveolar ridge width is encountered and in cases of restricted mesiodistal anatomy. Narrow-diameter implants are particularly useful when replacing small teeth such as lateral maxillary and mandibular incisors.

Table 3 Months of follow-up (from insertion of implant) by patients and implants.

Follow-up (months)	Patients			Implants		
	N	%	Cum %	N	%	Cum %
42 to <45	5	10.0	10.0	9	10.2	10.2
45 to <50	26	52.0	62.0	47	53.4	63.6
50 to <55	16	32.0	94.0	29	33.0	96.6
55 to 60	3	6.0	100.0	3	3.4	100.0
Total	50	100.0		88	100.0	

Cum, cumulative

The present study suggests that treatment with narrow-diameter implants may be a useful alternative to treat narrow ridges. Only one implant failed during the observation period (2.5 mm in diameter). It has been suggested using finite elemental analysis that wider implants may dissipate better the acting forces, thus reducing the stress in the surrounding bone²⁶. As a consequence, it should be taken into account that narrow-diameter implants may potentially be more prone to failure than standard-diameter implants. This may be due to the reduced available bone-implant contact area or to reduced resistance to fatigue. The placement of 2.5-mm

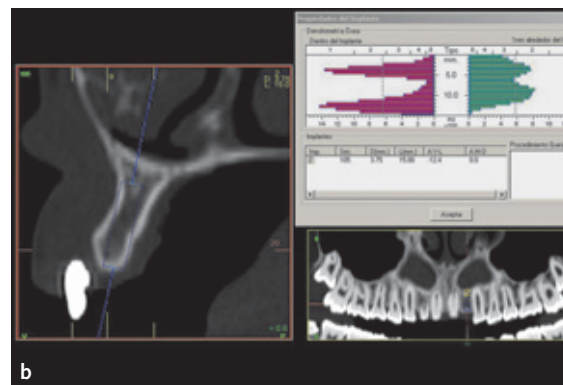
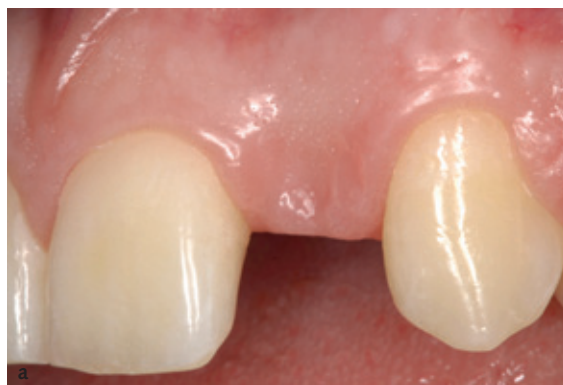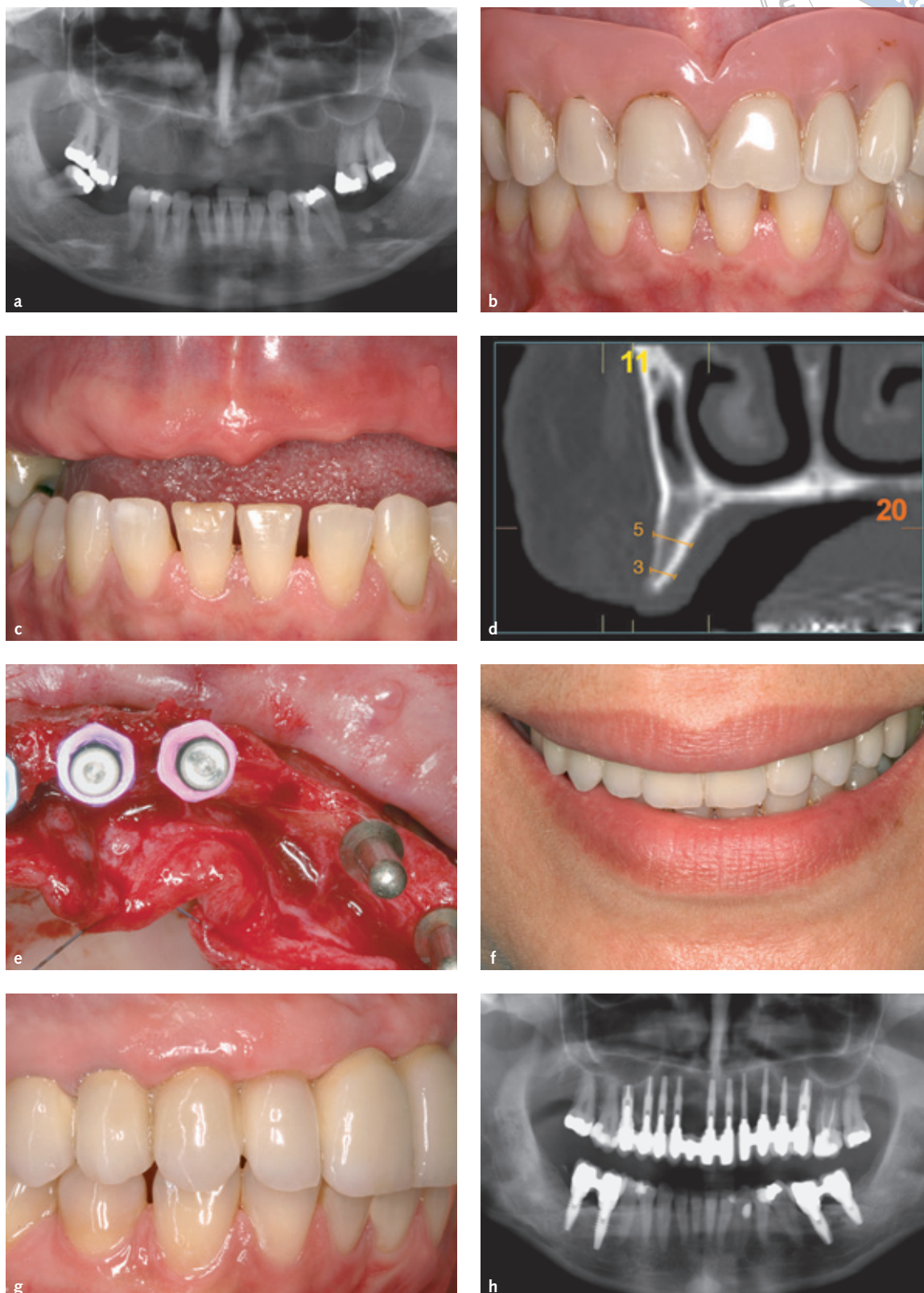


Fig 2 Example of one case involved in the study. (a) The patient was an 18-year-old female with agenesis of the lateral incisor. (b) Assuming a mesiodistal width of 6.2 mm, it was decided to place a 3.0-mm diameter implant. (c) Immediate loading was selected for this implant. (d and e) Results 3 years after implant placement.

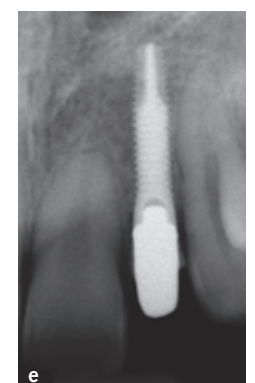
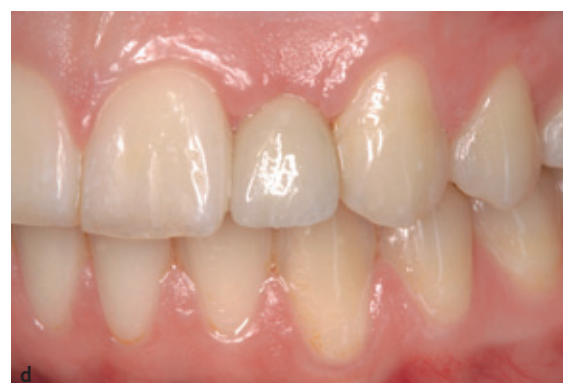
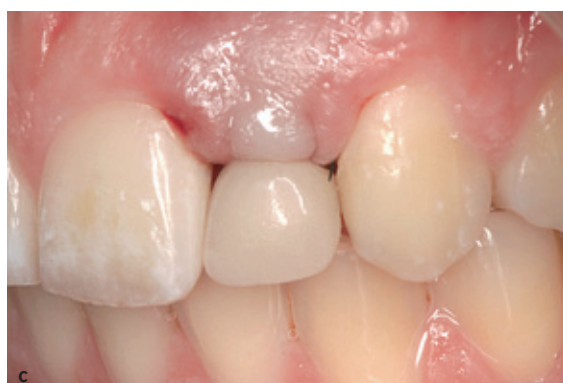Fig 3 Example of another case involved in the study. (a to d) Panoramic radiograph of a 58-year-old patient with partial edentulism. The ridge ranged between 3 and 4 mm. (e) Implants were placed after ridge expansion. Some Tiny® implants were used as transitional implants. (f) Provisional prosthesis. (g) When placing the definitive prosthesis, all implants were osseointegrated and the transitional implants were maintained. (h) Final situation of the patient 4 years after implant placement.





diameter implants, as well as 3.0-mm ones, must always be splinted with two other implants, except when these are placed as single implants in cases of maxillary and mandibular lateral incisors.

One of the first studies that evaluated the use of narrow-diameter implants was published in 1999. Polizzi et al⁷ evaluated the predictability of using implants with a 3.0 mm diameter (30 implants in 21 patients) for single-tooth restorations in situations when the mesiodistal dimension caused an unfavourable condition. The implants were in function for 3 to 7 years, and only two complications occurred (one failure and one replaced prosthesis), achieving an overall success rate of 96.7%.

Shatkin et al¹⁵ conducted in 2007 the largest published study evaluating narrow-diameter implants. In a retrospective analysis, the authors evaluated 2514 narrow-diameter implants (1.8 to 2.4 mm) placed in 531 patients over a 5-year period. The mean duration of follow-up was 2.9 years. The overall implant survival was 94.2%. Statistically significant predictors of failure included the use of removable prostheses, the posterior maxilla, atrophic bone and smoking. The mean failure time for the failed implants was approximately 6.4 months, correlating with the osseointegration period.

Terpelle and Khoury¹⁸ conducted in 2008 a retrospective study with 337 narrow-diameter implants (3.0 and 3.4 mm) inserted in 137 patients: 38 implants were loaded immediately. Only two of the 337 implants were lost (3.4 mm), showing a survival rate of 99.4%. None of the immediately loaded implants was lost, and no major prosthetic complications were detected. At the same time, Degidi et al¹⁹ conducted a study where 237 patients received 510 narrow-diameter implants (3.0 to 3.5 mm). In this study, only three out of the 510 implants were lost (survival rate of 99.4%) and no statistically significant differences were detected among the studied variables.

Degidi et al²² conducted a randomised clinical trial comparing the bone loss pattern and soft tissue healing of immediate versus one-stage loaded 3.0-mm diameter implants in cases involving a single missing lateral maxillary incisor. Sixty narrow-diameter implants were placed in 60 patients. No implant failures occurred and no statistically significant differences were observed for bleeding

or plaque index. The marginal bone loss at the 36-month follow-up was 0.85 mm (SD 0.71) and 0.75 mm (SD 0.63) for the immediate and one-stage groups, respectively. Results of the present retrospective study are comparable to those reported by other authors²⁷ and those involving BTI implants of different diameters and lengths²⁸⁻³⁰.

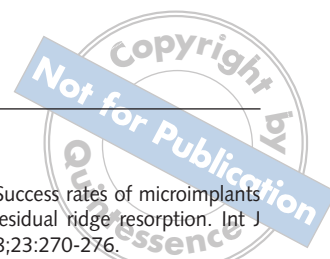One important issue that should be kept in mind when interpreting the present results is that they come from a retrospective study. This type of study has less validity than randomised prospective clinical trials, due to issues of selection bias and confounding factors. Additionally, retrospective studies rely on the completeness of data entered in the patient's chart, which may implicate the risk of missing data because of misplaced, misfiled or missing information in the chart.

Implant design and properties and the surface condition of the implant may modify the percentage of bone-implant contact. This is particularly important because the greater the percentage of bone-implant contact, the less stress is applied to the bone-implant interface. The narrow-diameter implants used in the present study had a rough, acid-etched surface that showed significantly greater bone-implant contact compared with machined- or polished-surface implants³¹. In addition, all implants were humidified with PRGF[®] in order to bioactivate their surfaces by creating a protein layer that stimulated the mechanism of bone formation at the implant-bone interface, which may promote faster implant osseointegration³².

The marginal bone loss observed in the present study was consistent with data reported in studies involving narrow-diameter and standard-diameter implants³³. In a recent study published by Maló et al²¹, a mean marginal bone resorption of 1.74 mm, after placing 247 narrow implants, was reported in patients with edentulous posterior regions.

■ Conclusions

Narrow-diameter implants (2.5 to 3 mm) can be successfully used to treat narrow bone ridges up to 3 years in function. Longer follow-up periods of 10 or more years are needed to validate the present good results in a long-term prospective study.



References

- Renouard F, Nisand D. Impact of implant length and diameter on survival rates. *Clin Oral Implants Res* 2006;17(Suppl 2):35-51.
- Esposito M, Grusovin MG, Rees J, Karasoulos D, Felice P, Alissa R et al. Effectiveness of sinus lift procedures for dental implant rehabilitation: a Cochrane systematic review. *Eur J Oral Implantol* 2010;3:7-26.
- Felice P, Checci V, Pistilli R, Scarano A, Pellegrino G, Esposito M. Bone augmentation versus 5-mm dental implants in posterior atrophic jaws. Four-month post-loading results from a randomised controlled clinical trial. *Eur J Oral Implantol* 2009;2:267-281.
- Comfort MB, Chu FC, Chai J, Wat PY, Chow TW. A 5-year prospective study on small diameter screw-shaped oral implants. *J Oral Rehabil* 2005;32:341-345.
- Esposito M, Grusovin MG, Felice P, Karatzopoulos G, Worthington HV, Coulthard P. The efficacy of horizontal and vertical bone augmentation procedures for dental implants: a Cochrane systematic review. *Eur J Oral Implantol* 2009;2:167-184.
- Davaranpanah M, Martinez H, Tecucianu JF, Celletti R, Lazzara R. Small-diameter implants: indications and contraindications. *J Esthet Dent* 2000;12:186-194.
- Polizzi G, Fabbro S, Furri M, Herrmann I, Squarzone S. Clinical application of narrow Brånemark System implants for single-tooth restorations. *Int J Oral Maxillofac Implants* 1999;14:496-503.
- Vigolo P, Givani A. Clinical evaluation of single-tooth mini-implant restorations: a five-year retrospective study. *J Prosthet Dent* 2000;84:50-54.
- Hallman M. A prospective study of treatment of severely resorbed maxillae with narrow nonsubmerged implants: results after 1 year of loading. *Int J Oral Maxillofac Implants* 2001;16:731-736.
- Zinsli B, Sägesser T, Mericske-Stern R. Clinical evaluation of small-diameter ITI implants: a prospective study. *Int J Oral Maxillofac Implants* 2004;19:92-99.
- Vigolo P, Givani A, Majzoub Z, Cordioli G. Clinical evaluation of small-diameter implants in single-tooth and multiple-implant restorations: a 7-year retrospective study. *Int J Oral Maxillofac Implants* 2004;19:703-709.
- Zarone F, Sorrentino R, Vaccaro F, Russo S. Prosthetic treatment of maxillary lateral incisor agenesis with osseointegrated implants: a 24-39-month prospective clinical study. *Clin Oral Implants Res* 2006;17:94-101.
- Cordaro L, Torsello F, Mirisola Di Torresanto V, Rossini C. Retrospective evaluation of mandibular incisor replacement with narrow neck implants. *Clin Oral Implants Res* 2006;17:730-735.
- Romeo E, Lops D, Amorfini L, Chiapasco M, Ghisolfi M, Vogel G. Clinical and radiographic evaluation of small-diameter (3.3 mm) implants followed for 1-7 years: a longitudinal study. *Clin Oral Implants Res* 2006;17:139-148.
- Shatkin TE, Shatkin S, Oppenheimer BD, Oppenheimer AJ. Mini dental implants for long-term fixed and removable prosthetics: a retrospective analysis of 2514 implants placed over a five-year period. *Compend Contin Educ Dent* 2007;28:92-99.
- Veltri M, Ferrari M, Balleri P. One-year outcome of narrow diameter blasted implants for rehabilitation of maxillas with knife-edge resorption. *Clin Oral Implants Res* 2008;19:1069-1073.
- Morneburg TR, Proschel PA. Success rates of microimplants in edentulous patients with residual ridge resorption. *Int J Oral Maxillofac Implants* 2008;23:270-276.
- Terpelle T, Khoury F. Narrow-diameter implants. A three year retrospective study of 337 implants. *Clin Oral Implants Res* 2008;19:925.
- Degidi M, Piattelli A, Carinci F. Clinical outcome of narrow diameter implants: a retrospective study of 510 implants. *J Periodontol* 2008;79:49-54.
- Franco M, Viscioni A, Rigo L, Guidi R, Zollino I, Avantaggiato A, Carinci F. Clinical outcome of narrow diameter implants inserted into allografts. *J Appl Oral Sci* 2009;17:301-306.
- Maló P, de Araújo Nobre M. Implants (3.3 mm diameter) for the rehabilitation of edentulous posterior regions: a retrospective clinical study with up to 11 years of follow-up. *Clin Implant Dent Relat Res* 2009 Aug 3 [Epub ahead of print].
- Degidi M, Nardi D, Piattelli A. Immediate versus one-stage restoration of small-diameter implants for a single missing maxillary lateral incisor: a 3-year randomized clinical trial. *J Periodontol* 2009;80:1393-1398.
- von Elm E, Altman DG, Egger M, Pocock SJ, Gotsche PC, Vandenbroucke JP; STROBE Initiative. The Strengthening the Reporting of Observational Studies in Epidemiology (STROBE) statement: guidelines for reporting observational studies. *Lancet* 2007;370:1453-1457.
- Anitua E, Carda C, Andia I. A novel drilling procedure and subsequent bone autograft preparation: a technical note. *Int J Oral Maxillofac Implants* 2007;22:138-145. Erratum 2007;22:309.
- Anitua E. Plasma rich in growth factors: preliminary results of use in the preparation of future sites for implants. *Int J Oral Maxillofac Implants* 1999;14:529-535.
- Anitua E, Tapia R, Luzuriaga F, Orive G. Influence of implant length, diameter, and geometry on stress distribution: a finite element analysis. *Int J Periodontics Restorative Dent* 2010;30:89-95.
- Roos-Jansäker AM, Lindahl C, Renvert H, Renvert S. Nine-to fourteen-year follow-up of implant treatment. Part I: implant loss and associations to various factors. *J Clin Periodontol* 2006;33:283-289.
- Anitua E, Orive G, Aguirre JJ, Ardanza B, Andia I. 5-year clinical experience with BTI dental implants: risk factors for implant failure. *J Clin Periodontol* 2008;35:724-732.
- Anitua E, Orive G, Aguirre JJ, Andia I. Clinical outcome of immediately loaded dental implants bioactivated with plasma rich in growth factors: a 5-year retrospective study. *J Periodontol* 2008;79:1168-1176.
- Anitua E, Orive G, Aguirre JJ, Andia I. Five-year clinical evaluation of short dental implants placed in posterior areas: a retrospective study. *J Periodontol* 2008;79:42-48.
- Trisi P, Lazzara R, Rebaudi A, Rao W, Testori T, Porter SS. Bone-implant contact on machined and dual acid-etched surfaces after 2 months of healing in the human maxilla. *J Periodontol* 2003;74:945-956.
- Anitua E, Orive G, Pla R, Roman P, Serrano V, Andia I. The effects of PRGF on bone regeneration and on titanium implant osseointegration in goats: a histologic and histomorphometric study. *J Biomed Mater Res A* 2009;91:158-165.
- Cochran DL, Nummikoski PV, Schoolfield JD, Jones AA, Oates TW. A prospective multicenter 5-year radiographic evaluation of crestal bone levels over time in 596 dental implants placed in 192 patients. *J Periodontol* 2009;80:725-733.

Copyright of European Journal of Oral Implantology is the property of Quintessence Publishing Company Inc. and its content may not be copied or emailed to multiple sites or posted to a listserv without the copyright holder's express written permission. However, users may print, download, or email articles for individual use.